

# Charge Syndrome—A Case Report

A. Ravindran, A. Amirthagani, Prince Peter Dhas, S. Nagarajan, Senthil Kumar, Satheesh Kumar, Venkatesh

Department of Otorhonorhology, Thanjavur Madical College, Thanjavur, India

Email: [ravindranent2@gmail.com](mailto:ravindranent2@gmail.com)

Received 2 March 2015; accepted 18 March 2015; published 24 March 2015

Copyright © 2015 by authors and Scientific Research Publishing Inc.

This work is licensed under the Creative Commons Attribution International License (CC BY).

<http://creativecommons.org/licenses/by/4.0/>



Open Access

---

## Abstract

**CHARGE syndrome is a rare, recently well recognized entity with non-random pattern of congenital anomalies. The syndrome associations consist of C-coloboma of the eyes, H-heart disease, A-atresia of the choanae, R-retarded growth and development, G-genital hypoplasia/genitourinary anomalies and E-ear anomalies and/or hearing loss. All anomalies are not seen in every case and a varied spectrum of associations is seen in most of the cases. The exact incidence is not known. However, the reported prevalence is approximately 1:10,000 births. We report one such case.**

## Keywords

Charge Syndrome, Choanal Atresia, Coloboma

---

## 1. Introduction

CHARGE syndrome was initially defined as a non-random association of anomalies (coloboma, heart defect, atresia choanae, retarded growth and development, genital hypoplasia, ear anomalies/deafness). In 1998, an expert group defined the major (the classical 4C's: Choanal atresia, Coloboma, Characteristic ears and Cranial nerve anomalies) and minor criteria of CHARGE syndrome. Individuals with all four major characteristics or three major and three minor characteristics are highly likely to have CHARGE syndrome. However, there have been individuals genetically identified with CHARGE syndrome without the classical choanal atresia and coloboma. The reported incidence of CHARGE syndrome ranges from 0.1 - 1.2/10,000 and depends on professional recognition. Coloboma mainly affects the retina. Major and minor congenital heart defects (the commonest cyanotic heart defect is tetralogy of Fallot) occur in 75% - 80% of patients. Choanal atresia may be membranous or bony, bilateral or unilateral. Mental retardation is variable with intelligence quotients (IQ) ranging from normal to profound retardation. Under-development of the external genitalia is a common finding in males but it is less apparent in females. Ear abnormalities include a classical finding of unusually shaped ears and hearing loss (conductive and/or nerve deafness that ranges from mild to severe deafness). Multiple cranial nerve dysfunctions

are common. A behavioral phenotype for CHARGE syndrome is emerging. Mutations in the *CHD7* gene (member of the chromodomain helicase DNA protein family) are detected in over 75% of patients with CHARGE syndrome. Children with CHARGE syndrome require intensive medical management as well as numerous surgical interventions. They also need multidisciplinary follow-up.

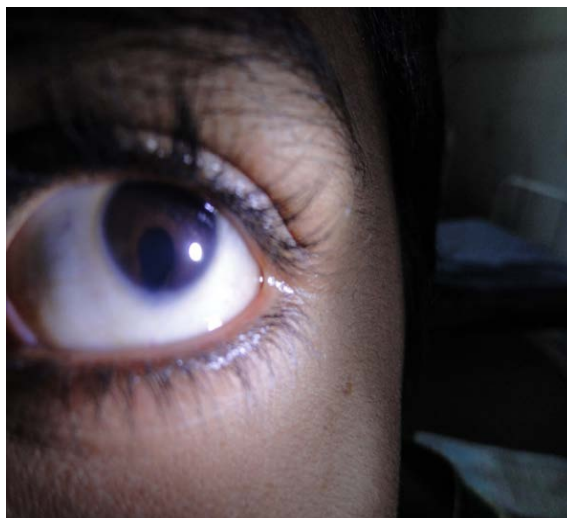
Some of the hidden issues of CHARGE syndrome are often forgotten, one being the feeding adaptation of these children, which needs an early aggressive approach from a feeding team. As the child develops, challenging behaviors become more common and require adaptation of educational and therapeutic services, including behavioral and pharmacological interventions.

## 2. Case Report

A female child aged 14, was brought to the OPD by the grand mother, with the complaints of discharge from left side of nose since birth. There was history of hard of hearing both ears, difficulty in speech, defective vision on left eye. Otherwise, the perinatal and developmental history was normal.

On examination, pt had unilateral choanal atresia, sensorineural hearing loss on both side. Eye examination revealed left eye micro cornea with typical coloboma (**Figure 1**) choroid involving optic disc and iris, squint, spontaneous nystagmus, loss of left eye vision. General examination of the patient showed facial asymmetry (**Figure 2**), polydactyly (**Figure 3**), poor breast development on left side, systemic examination revealed, wide fixed split on auscultation, abdominal and respiratory systems are normal.

Child was investigated. Diagnostic nasal endoscopy showed complete choanal atresia on left side. Severe sensorineural hearing loss on both sides on Pure Tone Audiogram. CT PNS and temporal bone showed posterior coloboma left eye, left osseous choanal atresia (**Figure 4**).



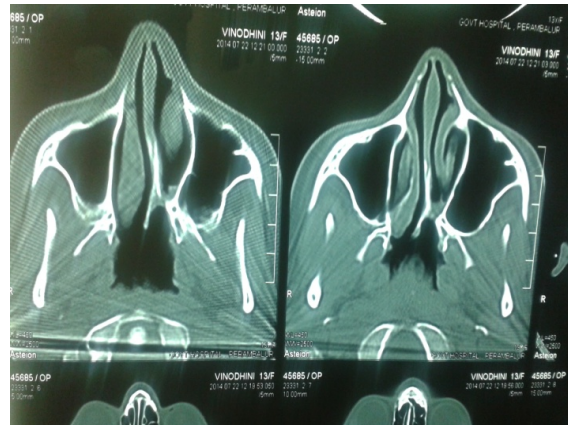
**Figure 1.** Coloboma left eye.



**Figure 2.** Showing facial asymmetry.



**Figure 3.** Showing polydactyly.



**Figure 4.** CT PNS showing choanal atresia (L).

Ultra sonogram of abdomen showed Left side extra renal pelvis. On echocardiogram moderate size 5 mm ostium secundum type of atrial septal defect with less than 2:1 left to right shunt.

Child has choanal atresia, coloboma of eyes, hearing loss, heart defect thus satisfying the criteria for CHARGE SYNDROME, which is undiagnosed till the age of 14.

### 3. Discussion

The CHARGE association was first described in 1979 by Hall *et al.*, in 17 children with multiple congenital anomalies who were ascertained by choanal atresia [1] [2]. In the same year, Hittner reported this syndrome in 10 children with ocular colobomas and multiple congenital anomalies [3], hence the syndrome is also called Hall-Hittner syndrome [4]. Pagon *et al.*, in 1981 first coined the acronym CHARGE association [5], (coloboma, heart defect, atresia choanae, retarded growth and development, genital hypoplasia, Ear anomalies/deafness) as a non-random association of anomalies occurring together more frequently than one would expect on the basis of chance. The original diagnostic criteria required the presence of four out of six of the CHARGE characteristics. Over the past 15 years the specificity of this pattern of malformations has reached the level that many clinicians now consider it to be a recognizable CHARGE syndrome [2].

### 4. Clinical Description

#### 4.1. Coloboma

This feature may be unilateral or bilateral and may affect only the iris or extend to involve the retina, or only the retina. Vision may be normal or impaired. The eye abnormalities range from iris coloboma without visual impairment to microphthalmos and anophthalmos. Retinal coloboma is more prevalent than iris coloboma and can affect the optic nerve. Eye malformations have been reported in as many as 80% of patients with CHARGE syndrome, with retinal involvement being the most common [6]. External inspection is not sufficient and testing

for functional vision is important but challenging especially in CHARGE individuals with extensive bilateral chorioretinal coloboma involving the optic nerve [7].

#### 4.2. Heart Defect

Congenital heart defects occur in 75% - 80% of patients with CHARGE syndrome. The most common major heart defect is tetralogy of Fallot (33%). Other frequent anomalies are patent ductus arteriosus, double outlet right ventricle with atrioventricular canal, ventricular septal defect and atrial septal defect with or without cleft mitral valve. Vascular rings and more complex heart defects need to be anticipated [8]-[11].

#### 4.3. Choanal Atresia

Choanal atresia is a narrowing or a blockage of the passages between the nasal cavity and the naso-pharynx. It represents a primary feature with a high index of suspicion for CHARGE syndrome and it should focus attention on other organ systems such as the eye and heart. Choanal atresia may be membranous or bony; bilateral or unilateral. Bilateral posterior choanal atresia (BPCA) was shown to be associated with increased neonatal mortality, especially if associated with major cardiac malformations +/- tracheoesophageal atresia [8]. However, the Canadian epidemiological study data suggests that an individual from this population with a more severe clinical presentation of CHARGE features generally survive [9]. Polyhydramnios in pregnancy is seen commonly in individuals with bilateral posterior choanal atresia, and may also be present without BPCA, probably due to an insufficient swallowing mechanism. Chronic middle ear infections and deafness can be associated complications of choanal atresia [12].

#### 4.4. Retardation of Growth and Development

Growth and developmental retardation become more obvious as the child matures. At birth, children with CHARGE syndrome usually have normal weights and lengths [13]. When growth deceleration is due to cardiac and respiratory problems, there may be catch up growth, and normal height can be obtained [14]. However, the influence of feeding problems on growth in infancy should not be underestimated. Early and continued intervention for feeding difficulties is vitally important [15]; occasionally there is growth hormone deficiency. The majority of school-aged children with CHARGE syndrome are below the third percentile for physical growth norms [13]; feeding with solids and lumpy foods, and risk of aspiration may still exist. Mental retardation is variable with intelligence quotients (IQ) ranging from near-normal to profound retardation. Behavioral issues and an autism-like spectrum disorder are now being recognized as features of the syndrome [16] [17].

#### 4.5. Genitourinary Problems

Under-development of the external genitalia is a common finding in males but it is more difficult to recognize in females. Microphallus, penile agenesis, hypospadias, chordee, cryptorchidism, bifid scrotum, atresia of uterus, cervix and vagina, hypoplastic labia and clitoris are reported genital anomalies in this syndrome. Reported renal anomalies include solitary kidney, hydronephrosis, renal hypoplasia, duplex kidneys and vesicoureteral reflux. Hypogonadotrophic hypogonadism has been reported and is associated with delays in puberty or pubertal arrest [18] [19].

#### 4.6. Ear, Olfactory and Other Cranial Nerve Anomalies

Ear abnormalities include a classical finding of unusually shaped ears [6]. Lack of cartilage to the outer ear with deficient 7th nerve innervation to intrinsic ear muscles produces a prominent lop- or cup-shaped ear with a hypoplastic lobule (Figure 2). Hearing loss, conductive and/or nerve deafness, ranges from mild to severe. Ear anomalies were reported in 80% - 100% of cases in different series [10] [20]. Facial nerve palsies were noted to be a reliable predictor of sensorineural hearing loss. The characteristic abnormalities demonstrated by temporal bone computerized tomography (CT) or magnetic resonance imaging (MRI) scan include hypoplastic incus, decreased numbers of turns to the cochlea (mondini defect), and, in particular, absent semicircular canals. These distinctive radiological findings are classical for CHARGE syndrome and can aid diagnosis in a suspected case [21]. For this reason, a neonatal CT scan to look at the choanae and temporal bones can be extremely useful.

Blake *et al.* suggested that a typical clinical diagnosis of CHARGE syndrome requires the presence of at least 4 major features or 3 major features plus at least 3 minor features. Major features include ocular coloboma or microphthalmia, choanal atresia or stenosis, cranial nerve abnormalities, and characteristic auditory and/or auricular anomalies. Minor features include distinctive facial dysmorphism, facial clefting, tracheoesophageal fistula, congenital heart defects, genitourinary anomalies, developmental delay, and short stature. Other frequently associated abnormal findings include characteristic hand dysmorphism, hypotonia, deafness, and dysphagia [1] [22].

In our case, patient has unilateral coloboma, choanal atresia, sensorineural deafness, Left side extra renal pelvis, ostium secundum type of atrial septal defect. Thus fulfilling the criteria for charge syndrome [22]. The peculiar feature of the case is the late diagnosis. Usually patient will present with early symptoms. Here our patient came with the unilateral watery discharge from nose leading to our diagnosis of charge syndrome.

## 5. Management

Children with CHARGE syndrome require intensive medical Management as well as numerous surgical interventions. The most common neonatal emergencies in CHARGE syndrome involve cyanosis due to bilateral posterior choanal atresia and/or congenital heart defects, or the less common presentation of tracheoesophageal fistula. The primary foci of management should be airway Stabilization and circulatory support [1]. All patients suspected of having CHARGE syndrome should have a cardiology consultation. If the infant has Restrictive pulmonary blood flow and is dependant on a patent ductus arteriosus, the administration of prostaglandin to maintain ductal patency may be life saving. Some children require tracheostomy to manage chronic Airway problems and/or gastroesophageal reflux and aspiration.

Children with CHARGE syndrome require aggressive Medical management of their feeding difficulties, often needing gastrostomy and jejunostomy feeding tubes. Gastroesophageal fundoplication may be required for GER that does not respond to medical management. As intubation can be difficult in children with CHARGE syndrome, a pediatric anesthesiologist or pediatric Otolaryngologist should be present for planned surgical Procedures.

Any infant suspected of having CHARGE syndrome should have a complete eye examination by an ophthalmologist, with follow-up every three to six months thereafter, depending on the eye involvement. Photophobia is often a significant problem that can be ameliorated with tinted spectacles or by wearing a cap or visor with a dark brim. In the presence of facial palsy, patients should avoid corneal scarring by using artificial tears.

Hearing aids should be used as soon as hearing loss is documented. Frequent re-molding of the earpieces is necessary as the ear canals can be initially very small and ear cartilage may be insufficient to support a hearing aid. Cochlear implantations have been successfully performed in CHARGE syndrome patients. Children with CHARGE syndrome who undergo cochlear implantation should be allowed to continue with their sign language in parallel with their expressive speech training [23]. Adapted educational and therapeutic services to deal with dual auditory and visual sensory impairment should be proposed early in the child's life [23]-[25]. However, this population is unique with respect to their aberrant cranial nerve pathways and problems with expressive language.

In terms of endocrine issues, sex steroid therapy has been used for penile growth and descent of testes in males with CHARGE syndrome. The main use for testosterone is for delayed and incomplete male puberty during adolescence. Females often require hormone replacement at puberty [18]. Sex hormone replacement is also indicated for prevention of osteoporosis [19].

## 6. Conclusion

The acronym "CHARGE" denotes the nonrandom association of coloboma, heart anomalies, choanal atresia, retardation of growth and development, and genital and ear anomalies, which are frequently present in various combinations and varying degrees in individuals with CHARGE syndrome [3] [4]. No single feature is universally present or sufficient for the clinical diagnosis of CHARGE syndrome, and numerous guidelines have been published to aid in establishing a likely clinical diagnosis. The peculiar feature of the case is the late diagnosis. Usually patient will present with early symptoms. Here our patient came with the unilateral watery discharge from nose leading to our diagnosis of charge syndrome. With the permission of the patient and her parent, we are publishing this article due to the peculiarity of the case.



## References

- [1] Blake, K.D., Davenport, S.L.H., Hall, B.D., Hefner, M.A., Pagon, R.A., Williams, M.S., Lin, A.E. and Graham Jr., J.M. (1998) CHARGE Association: An Update and Review for the Primary Pediatrician. *Clinical Pediatrics*, **37**, 159-173. <http://dx.doi.org/10.1177/000992289803700302>
- [2] Hall, B.D. (1979) Choanal Atresia and Associated Multiple Anomalies. *Journal of Pediatrics*, **95**, 395-398. [http://dx.doi.org/10.1016/S0022-3476\(79\)80513-2](http://dx.doi.org/10.1016/S0022-3476(79)80513-2)
- [3] Hittner, H., Hirsch, N., Kreh, G. and Rudolph, A. (1979) Colobomatous Microphthalmia, Heart Disease, Hearing Loss, and Mental Retardation: A Syndrome. *Journal of Pediatric Ophthalmology and Strabismus*, **16**, 122-128.
- [4] Graham Jr., J.M. (2001) A Recognizable Syndrome within CHARGE Association: Hall-Hittner Syndrome. *American Journal of Medical Genetics*, **99**, 120-123. [http://dx.doi.org/10.1002/1096-8628\(2000\)9999:999<0::AID-AJMG1132>3.0.CO;2-J](http://dx.doi.org/10.1002/1096-8628(2000)9999:999<0::AID-AJMG1132>3.0.CO;2-J)
- [5] Pagon, R.A., Graham Jr., J.M., Zonana, J. and Young, S.L. (1981) Coloboma, Congenital Heart Disease, and Choanal Atresia with Multiple Anomalies: CHARGE Association. *Journal of Pediatrics*, **99**, 223-227. [http://dx.doi.org/10.1016/S0022-3476\(81\)80454-4](http://dx.doi.org/10.1016/S0022-3476(81)80454-4)
- [6] Russell-Eggitt, I.M., Blake, K.D., Taylor, D. and Wyse, R.K. (1990) The Eye in CHARGE Association. *British Journal of Ophthalmology*, **74**, 421-426. <http://dx.doi.org/10.1136/bjo.74.7.421>
- [7] McMain, K., Robitaille, J., Blake, K., Wood, E., Smith, I., Temblay, F., Johnston, J. and Beis, J. (2005) Eye in Charge. <http://www.chargesyndrome.ca/TheEyeInCHARGE.htm>
- [8] Blake, K.D., Russell-Eggitt, I.M., Morgan, D.W., Ratcliffe, J.M. and Wyse, R.K.H. (1990) Who's in CHARGE? Multidisciplinary Management of Patients with CHARGE Association. *Archives of Disease in Childhood*, **65**, 217-223. <http://dx.doi.org/10.1136/adc.65.2.217>
- [9] Lin, A.E., Siebert, J.R. and Graham Jr., J.M. (1990) Central Nervous System Malformations in the CHARGE Association. *American Journal of Medical Genetics*, **37**, 304-310. <http://dx.doi.org/10.1002/ajmg.1320370303>
- [10] Tellier, A.L., Cormier-Daire, V., Abadie, V., Amiel, J., Sigaudy, S., Bonnet, D., de Lonlay-Debeney, P., Morrissseau-Durand, M.P., Hubert, P., Michel, J.L., Jan, D., Dollfus, H., Baumann, C., Labrune, P., Lacombe, D., Philip, N., Le-Merrer, M., Briard, M.L., Munnich, A. and Lyonnet, S. (1998) CHARGE Syndrome: Report of 47 Cases and Review. *American Journal of Medical Genetics*, **76**, 402-409. [http://dx.doi.org/10.1002/\(SICI\)1096-8628\(19980413\)76:5<402::AID-AJMG7>3.0.CO;2-O](http://dx.doi.org/10.1002/(SICI)1096-8628(19980413)76:5<402::AID-AJMG7>3.0.CO;2-O)
- [11] Cyran, S.E., Martinez, R., Daniels, S., Dignan, P.S.J. and Kaplan, S. (1987) Spectrum of Congenital Heart Disease in CHARGE Association. *Journal of Pediatrics*, **110**, 576-580. [http://dx.doi.org/10.1016/S0022-3476\(87\)80555-3](http://dx.doi.org/10.1016/S0022-3476(87)80555-3)
- [12] Keller, J.L. and Kacker, A. (2000) Choanal Atresia, CHARGE Association, and Congenital Nasal Stenosis. *Otolaryngologic Clinics of North America*, **33**, 1343-1351. [http://dx.doi.org/10.1016/S0030-6665\(05\)70285-1](http://dx.doi.org/10.1016/S0030-6665(05)70285-1)
- [13] Blake, K.D., Kirk, J.M. and Ur, E. (1993) Growth in CHARGE Association. *Archives of Disease in Childhood*, **68**, 508-509. <http://dx.doi.org/10.1136/adc.68.4.508>
- [14] Searle, L. and Blake, K.D. (2005) CHARGE Syndrome from Birth to Adulthood: An Individual Reported on from 0 to 33 Years. *American Journal of Medical Genetics Part A*, **133**, 344-349. <http://dx.doi.org/10.1002/ajmg.a.30565>
- [15] Dobbeltsteyn, C., Marche, D.M., Blake, K.D. and Rashid, M. (2005) Early Oral Sensory Experiences and Feeding Development in Children with CHARGE Syndrome: A Report of Five Cases. *Dysphagia*, **20**, 89-100. <http://dx.doi.org/10.1007/s00455-004-0026-1>
- [16] Smith, I.M., Nichols, S.L., Issekutz, K. and Blake, K. (2005) Behavioral Profiles and Symptoms of Autism in CHARGE Syndrome: Preliminary Canadian Epidemiological Data. *American Journal of Medical Genetics Part A*, **133**, 248-256. <http://dx.doi.org/10.1002/ajmg.a.30544>
- [17] Hartshorne, T.S., Grialou, T.L. and Parker, K.R. (2005) Autistic-like behavior in CHARGE syndrome. *American Journal of Medical Genetics Part A*, **133**, 257-261. <http://dx.doi.org/10.1002/ajmg.a.30545>
- [18] Blake, K.D., Salem-Hartshorne, N., Abi Daoud, M. and Gradstein, J. (2005) Adolescent and Adult Issues in CHARGE Syndrome. *Clinical Pediatrics*, **44**, 151-159. <http://dx.doi.org/10.1177/000992280504400207>
- [19] Forward, K., Cummings, E. and Blake, K. (2005) Bone Health in Adolescents and Adults with CHARGE Syndrome. In Press.
- [20] Lalani, S.R., Safiullah, A.M., Fernbach, S.D., Harutyunyan, K.G., Thaller, C., Peterson, L.E., McPherson, J.D., Gibbs, R.A., White, L.D., Hefner, M., Davenport, S.L., Graham, J.M., Bacino, C.A., Glass, N.L., Towbin, J.A., Craigen, W.J., Neish, S.R., Lin, A.E. and Belmont, J.W. (2006) Spectrum of *CHD7* Mutations in 110 Individuals with CHARGE Syndrome and Genotype-Phenotype Correlation. *The American Journal of Human Genetics*, **78**, 303-314. <http://dx.doi.org/10.1086/500273>
- [21] Amiel, J., Attiee-Bitach, T., Marianowski, R., Cormier-Daire, V., Abadie, V., Bonnet, D., Gonzales, M., Chemouny, S.,

- Brunelle, F., Munnich, A., Manach, Y. and Lyonnet, S. (2001) Temporal Bone Anomaly Proposed as a Major Criterion for Diagnosis of CHARGE Syndrome. *American Journal of Medical Genetics*, **99**, 124-127. [http://dx.doi.org/10.1002/1096-8628\(20010301\)99:2<124::AID-AJMG1114>3.0.CO;2-9](http://dx.doi.org/10.1002/1096-8628(20010301)99:2<124::AID-AJMG1114>3.0.CO;2-9)
- [22] Verloes, A. (2005) Updated Diagnostic Criteria for CHARGE Syndrome: A Proposal. *American Journal of Medical Genetics Part A*, **133A**, 306-308. <http://dx.doi.org/10.1002/ajmg.a.30559>
- [23] Blake, K.D. and Brown, D. (1993) CHARGE Association Looking at the Future—The Voice of a Family Support Group. *Child: Care, Health and Development*, **19**, 395-409. <http://dx.doi.org/10.1111/j.1365-2214.1993.tb00744.x>
- [24] Tellier, A.L., Lyonnet, S., Cormier-Daire, V., de Lonlay, P., Abadie, V., Baumann, C., Bonneau, D., Labrune, P., Lacombe, D., Le Merrer, M., Nivelon, A., Philip, N., Briard, M.L. and Munnich, A. (1996) Increased Paternal Age in CHARGE Association. *Clinical Genetics*, **50**, 548-550. <http://dx.doi.org/10.1111/j.1399-0004.1996.tb02736.x>
- [25] Thelin, J.W. and Fussner, J.C. (2005) Factors Related to the Development of Communications in CHARGE Syndrome. *American Journal of Medical Genetics Part A*, **133**, 282-290. <http://dx.doi.org/10.1002/ajmg.a.30550>