

A Combination of Endoscopic CO₂ Laser Microsurgery and Radiotherapy for Treatment of T2N0M0 Glottic Carcinoma

Motohiro Sawatsubashi¹, Toshiro Umezaki¹, Takemoto Shin², Shizuo Komune¹

¹Department of Otolaryngology-Head and Neck Surgery, Graduate School of Medical Sciences, Kyushu University, Fukuoka, Japan

²Saga Medical School, Saga, Japan

Email: motohiro@qent.med.kyushu-u.ac.jp

Received April 19, 2012; revised May 30, 2012; accepted June 22, 2012

ABSTRACT

The aims of this study were to evaluate the results of CO₂ laser surgery alone and CO₂ laser surgery combined with radiotherapy in patients with T2N0M0 glottic carcinoma. A retrospective analysis was conducted of 35 cases of T2N0M0 glottic carcinoma. Fourteen patients with normal vocal cord mobility were treated with endoscopic CO₂ laser surgery alone. The remaining 21 patients were treated with CO₂ laser surgery followed by radiotherapy (44 - 70 Gy, including low-dose carboplatin chemoradiotherapy). Main outcome measures were local control, organ preservation, recurrence, 5-year survival, and successful salvage in cases of recurrence. We evaluated the patient's voice with the psychoacoustics GRBAS scale, maximum phonation time (MPT), and airflow rate (AFR) obtained by aerodynamic tests. Mean follow-up period was 5 years. Among the 35 T2N0M0 patients, 5-year survival and 5-year voice preservation rates were 97% and 89%, respectively. Local recurrence occurred in 7 of these patients (20%); 4 of 7 local recurrences were successfully re-treated by laser surgery. Total laryngectomy was necessary for salvage treatment in the remaining 3 patients. The post-treatment voice qualities were judged to be the same or improved over pretreatment qualities. There was little change in MPT and AFR after treatment in non-recurrence patients. CO₂ laser microsurgery is an excellent tool for treating selected cases of T2N0M0 glottic carcinoma. CO₂ laser surgery followed by radiotherapy is a useful option for treatment of T2N0M0 glottic carcinoma.

Keywords: T2 Glottic Carcinoma; Laryngeal Cancer; Endoscopic Laser Surgery; Chemoradiotherapy

1. Introduction

The larynx is involved in the important physiological functions of vocalization and swallowing. In Japan, approximately 3000 incident cases of laryngeal cancer, and 1000 died due to laryngeal cancer. The most frequent sites are glottis (60% to 65%) and supraglottis (30% to 35%) [1]. The frequency of laryngeal carcinomas in these sites is different among different countries. In particular, the incidence rates are very high in Italy, France, Spain, and Brazil [1]. The major symptom of glottic cancer is hoarseness. Therefore, it is important in the care of glottic carcinoma patients not only to improve the treatment results but also to preserve vocal fold function. Radiotherapy (including chemoradiotherapy), open surgery, and laser microsurgery are all accepted treatments for stage II glottic cancer [2-8]. However the appropriate treatment for patients with T2N0M0 glottic cancer is not well defined. In Saga Medical School Hospital, CO₂ laser surgery has been performed since 1986 as one of the organ preservation treatment choices, in early carcinoma

(T1N0M0) of the larynx [9]. Until 1997 in our hospital, the first choice of treatment for T2 glottic cancer has been partial or a total laryngectomy, but selected cases of T2 glottic cancer (T2 tumors without impaired vocal fold mobility and the tumor did not extend to the vocal process, early T2) have been received endoscopic CO₂ laser since 1990. T2 tumors with impaired vocal fold mobility or deep extension involving the paraglottic space or extending to the false vocal fold (advanced T2) were treated with CO₂ laser surgery followed by radiotherapy since 1998.

CO₂ laser surgery treatment has also been available in other institutions [2-7]. However, there are few reports evaluating the results of CO₂ laser surgery combined with radiotherapy in T2N0M0 glottic carcinoma patients. In our hospital, laser-debulking surgery was used prior to radiotherapy (or chemoradiotherapy) to improve the local control rate in advanced T2 glottic cancer patients. This report investigated the results of CO₂ laser surgery alone and CO₂ laser surgery combined with radiotherapy or

chemoradiotherapy in patients with T2N0M0 glottic carcinoma. We also studied the results to determine how laser surgery affects the voice.

2. Patients and Methods

2.1. Patients

For this study, detailed clinical analysis was performed on 56 patients who had undergone total laryngectomy or endoscopic CO₂ laser surgery between 1990 and 2000 in Saga Medical School Hospital. All patients had T2N0M0 invasive squamous cell glottic carcinoma. Carcinoma in situ and verrucous carcinoma were excluded. None of the patients had received radiotherapy or chemotherapy prior to endoscopic surgery. Patients with a follow-up period of less than 2 years were excluded. Thirty-five of 56 patients received endoscopic CO₂ laser surgery between 1990 and 2000 in Saga Medical School Hospital. The remaining 21 patients received total laryngectomy between 1990 and 1997. Informed consent was obtained from all patients. Invasive squamous cell glottic carcinoma was classified according to the UICC TNM classification of 1992.

2.2. Treatments

In Saga medical school hospital, T2 tumors without impaired vocal fold mobility (early T2) were treated with endoscopic CO₂ laser surgery alone from 1990. T2 tumors with impaired vocal fold mobility or deep extension involving the paraglottic space or extending to the false vocal fold (advanced T2) were treated with total or partial laryngectomy until 1997. All advanced T2 glottic cancers were treated with CO₂ laser surgery followed by radiotherapy from 1998.

The endoscopic CO₂ laser surgery was classified according to the criteria of the Working Committee, European Laryngological Society [10]. Laser power was at 3 - 10 W with a 0.1-sec pulse or continuous vaporization. In the endoscopic laser surgery, all resections were done as a cordectomy with one of the following two techniques. In the first technique (laser surgery alone), a CO₂ laser was used as a scalpel to excise a lesion (type II, III, IV and Va cordectomy) in selected T2 cases (early T2) in whom the tumor did not extend to the vocal process and who had normal vocal cord mobility. Fourteen patients with T2N0M0 disease were treated with endoscopic CO₂ laser surgery alone. The remaining 21 patients were treated with CO₂ laser surgery followed by radiotherapy. These advanced T2 cases had tumors that extended to the subglottic space, a primary lesion that was exophytic with a large volume, or a tumor that extended to the vocal process or impaired vocal cord mobility. The tumor tissue was vaporized with a CO₂ laser, including the epithelium, Reinke's space, and the vocal ligament (de-

bulking surgery). The vocal muscle was preserved as much as possible even if this required leaving some tumor. Radiotherapy (44 - 70 Gy, 2 Gy a day, 5 days a week) was then given. Nine of 21 patients received low-dose carboplatin (CBDCA) conventional concomitant extra beam chemoradiotherapy (CBDCA at 15 mg/m² a day, 5 days a week, total of four weeks). CBDCA was used as a radio sensitizer because it was shown to enhance the effects of radiation [11,12]. The patients in this group were treated with a 4-Mev linear accelerator. Parallel-opposed portals were used routinely, almost always with a field size of 5 by 5 cm.

2.3. Treatments for Recurrence

As a general rule for patients experiencing recurrence, we performed CO₂ laser surgery alone for rT1N0M0 or rT2N0M0 patients with normal vocal cord mobility. The criteria for CO₂ laser surgery of recurrent glottic cancer are similar to the de Gier HHW criteria [13]. Other patients received laser surgery followed by radiation therapy or total laryngectomy. We also performed neck dissection for rN patients.

2.4. Clinical Analysis

The main outcome measures were local tumor control, voice preservation, recurrence, 5-year survival, and successful salvage in cases of recurrence. The 5-year cause-specific survival rate (end point: death by other causes) and 5-year cumulative laryngeal preservation rate (end point: total laryngectomy) for these patients were calculated by the Kaplan-Meier method. Salvage rates are reported as a percentage of successful salvage per recurrence. The minimum follow-up period was 2 years and the maximum was 12 years (mean, 5 years).

2.5. Voice Evaluation

We evaluated the patient's voice with GRBAS, maximum phonation time (MPT), air flow rate (AFR), pitch, and intensity obtained by aerodynamic tests. The GRBAS scale was classified according to the Japan Society of Logopedics and Phoniatrics [14]. The authors and a speech pathologist made judgment ratings of voice quality. The voice sample was measured and analyzed more than one year (from one year to two years) after surgery. We used PS77 (Nagasima Co., Ltd., Tokyo Japan) and Multi-Dimensional Voice Program, MDVP (Kay Elemetrics Co., Ltd., NJ, USA) were used to test phonatory function. Statistical analysis was done with the Wilcoxon signed-rank test or paired student *t* test. *p* values of < 0.01 were regarded as significant.

2.6. Follow-Up

As a general rule, patients were examined after treatment

in an outpatient clinic every two or four weeks for the first year after discharge, every month during the second year, and every few months during the third year. At each outpatient visit, the patient was always examined by at least two physicians to double check test and examination results.

2.7. Comparison with Total Laryngectomy Results

We also compared the results for the 35 patients with results between 1990 and 1997 of total laryngectomy for 21 stage II (advanced T2) glottic carcinoma patients.

3. Results

Among the 35 T2N0M0 patients, the 5-year survival and 5-year voice preservation rates were 97% and 89%, respectively. Two of the 14 patients who underwent CO₂ laser surgery alone had a type II cordectomy, 8 patients a type III cordectomy, and 4 patients a type Va cordectomy. The 5-year cause-specific survival rate was 100%, the laryngeal preservation rate was 100%, and the recurrence rate was 29%. Three of 21 patients who underwent CO₂ laser surgery followed by radiotherapy had a type I cordectomy, 16 patients a type II cordectomy, 1 patient a type III cordectomy, and 1 patient was performed type Va cordectomy. No patients suffered from dysphasia or perichondritis during or after treatments. The 5-year cause-specific survival rate was 97%, the laryngeal preservation rate was 82%, and the recurrence rate was 14% (Table 1). The side effects of chemoradiotherapy, such as prevalent toxicity, were all within Grade 1 and 2.

Local recurrence occurred in 7 patients (20%), and 4 of 7 local recurrences were successfully re-treated with laser surgery. Total laryngectomy was necessary for salvage treatment in the remaining 3 patients. One patient died with nodal regional failure (Figure 1). Anterior commissure spread was seen in 7 patients. There was no significant difference in local control between the groups of patients with and without anterior commissure involvement.

Table 1. Stage II glottic cancer therapeutic results.

Treatments	Patients (n)	5-yr Survival (%)	Voice preserve (%)	Recurrence (%)
Laser surgery	14	100	100	29
Laser surgery + RT	21	97	82	14
Laser surgery (Total)	35	97	89	20
Total laryngectomy	21	100	0	19

yr, year; RT, Radiotherapy.

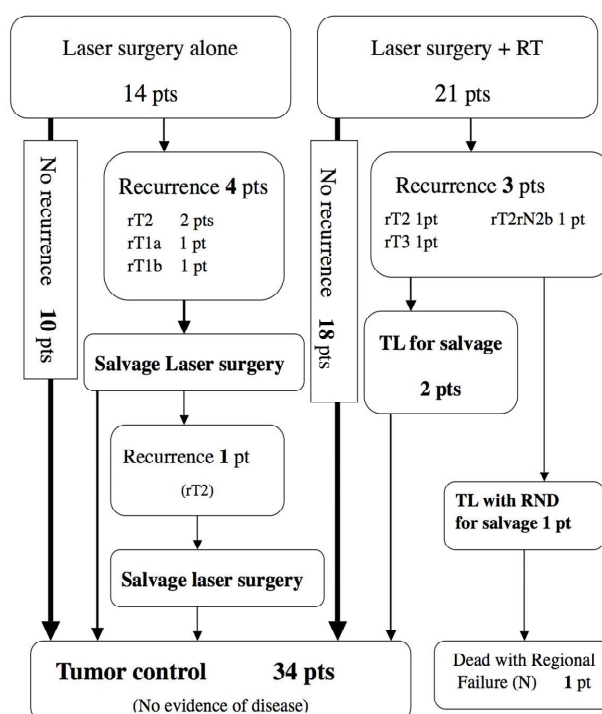


Figure 1. Surgical salvage treatment pathway of 7 T2N0M0 patients with local recurrence. RT: Radiotherapy. TL: Total laryngectomy. RND: Radical neck dissection. Pt: Patient. Pts: Patients.

There was little change in MPT ($p > 0.05$) after treatment in no recurrent T2N0M0 patients. Although the postoperation AFR and pitches were slightly higher than the pre-operation values ($p > 0.01$), no statistically significant differences were observed between pre- and postoperation voice qualities (Figures 2-4). The post-treatment voice qualities were judged to be the same or improved over pretreatment qualities (GRABAS scale, Table 2). The 5-year cause-specific survival rate for the total laryngectomy group was 100%, and the recurrence rate was 19% (Table 1). In 4 of 21 patients, recurrence of cervical lymph node metastasis was detected, but all 4 patients were salvaged by neck dissection.

4. Discussion

The glottic cancer treatments for laryngeal function preservation include endoscopic microsurgery, partial laryngectomy, radiotherapy, and combined therapy [2-8,14-18]. Endoscopic laser surgery is widely accepted for early glottic cancer treatment [5,8,19]. There are several advantages of CO₂ laser surgery alone in comparison with radiotherapy and partial laryngectomy [4,9,15,18,20]:

- 1) less pain after treatment and fewer side effects such as radiation-induced pharyngitis or dermatitis;
- 2) short surgery time and there no side effects such as dysphasia, hemorrhage, or cartilage necrosis;
- 3) histopathological

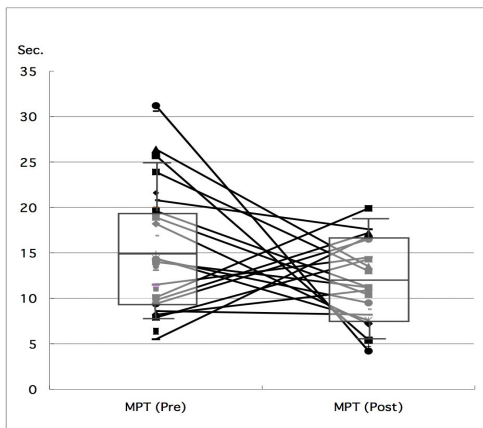


Figure 2. Pre- and post-operative MPT in T2N0M0 glottic cancer patients (n = 19, p > 0.05). MPT, maximum phonation time (sec). Pre, pre-operative, post, post-operative.

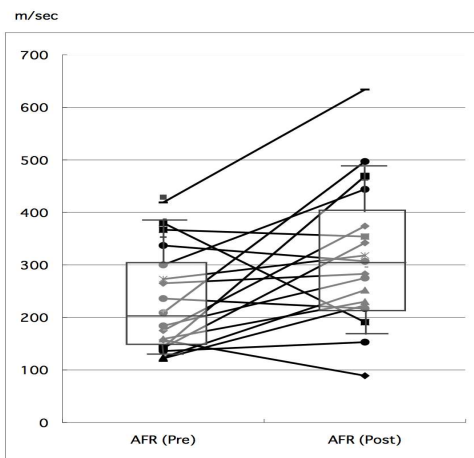


Figure 3. Pre- and post-operative AFR, in T2N0M0 glottic cancer patients (n = 18, p > 0.01). AFR, mean air flow rate during phonation.

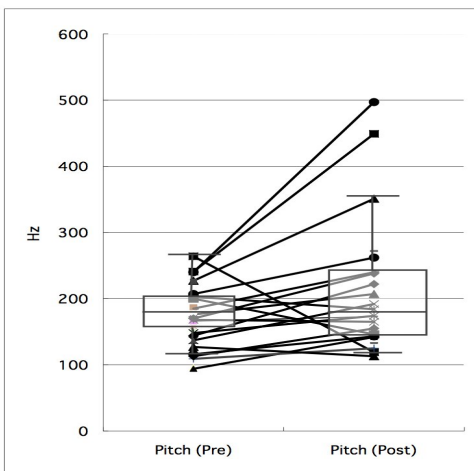


Figure 4. Pre- and post-operative pitch measurements in T2N0M0 glottic cancer patients (n = 23, p > 0.01). Pre, pre-operative, post, post-operative.

Table 2. Comparative voice quality after laser surgery.

	Grade	Rough	Breathy	Asthenic	Strained
Improvement	10	8	9	0	6
No change	6	8	6	16	7
Impairment	0	0	1	0	3

evaluation; 4) re-treatment with laser surgery or radiation of recurrent tumors; 5) easy observation during follow-up; 6) short hospitalization period and high cost effectiveness; and 7) no radiation-induced carcinoma.

Because of these advantages, CO₂ laser surgery has been performed for early glottic carcinoma in our institution. In this study, all outcome measures were good including those of local control, voice preservation, recurrence rate, 5-year survival rate, and successful salvage in cases of recurrence, and voice quality. In particular, this study showed that CO₂ laser surgery alone is sufficient for early T2 cases. Early glottic cancer cases are controlled by radiation treatment or partial laryngectomy, but we think that CO₂ laser surgery alone is more advantageous than these therapies.

Although favorable results for selected T2N0M0 laryngeal carcinoma treated with laser surgery are supported by previous study [4,8], no definitive recommendations could be given for the best single treatment for all T2N0M0 glottic cancers. Radiotherapy is believed to preserve voice best, but radiotherapy alone is associated with a high risk of local recurrence [16,17]. When we have judged that CO₂ laser surgery alone was not adequate for T2N0M0 cases, we have used CO₂ laser surgery followed by radiotherapy or chemoradiotherapy as a combination therapy to improve results and voice quality.

For T2 glottic cancer, the local control with radiotherapy alone falls to 50 to 85% [21]. The previous report showed it seemed to favor open conservation surgery over radiotherapy or endoscopic laser surgery when local control is the endpoint [21]. Our study showed that the 5-year survival and 5-year voice preservation rates were 97% and 89%, respectively.

The post-treatment voice qualities were judged to be the same or improved over pretreatment qualities (Table 2). We think that voice qualities should be an important factor to integrate into decision-making.

Because this report is not a randomized retrospective study, and the total cost of CO₂ laser surgery followed by external beam radiotherapy is significantly higher than that of laser surgery alone, further investigation is needed to resolve these problems. However, our study revealed good local control results and satisfactory vocal qualities. We believe that this method is a more useful treatment than that of partial or total laryngectomy or radiotherapy alone.

Endoscopic laser surgery has been used successful for

treating radiation failure of early glottic carcinoma [13,22], but there are few studies of the patterns of local recurrences, related re-treatment methods, and results for salvage treatment. In this study, 4 local recurrent rT1 and rT2 patients were salvaged with CO₂ laser surgery. Our previous study of CO₂ laser surgery for T1N0 glottic carcinoma patients (n = 55) found 13% recurrence, but all recurrence patients (rT1 or rT2) were salvaged with re-laser surgery [8]. These results showed that laser surgery was one of the best re-treatment options for salvage therapy in case of local failure. It is important to do close clinical follow-up, because even if patients have recurrence they may undergo re-treatment swiftly.

Voice quality impairment was minimal in most patients in this study. The factors in the patients' social backgrounds, such as age and occupation, were different. Therefore, it was necessary to assess the voice after laser surgery in consideration of each patient's social background. Laser excision for treatment of early glottic cancer had more advantages than those of radiotherapy or laryngectomy from the viewpoint of quality of life.

5. Conclusions

Endoscopic CO₂ laser surgery alone gives good oncological results and is a desirable alternative to radiotherapy or partial laryngectomy for patients with early T2 glottic carcinoma.

In advanced cases of T2N0 cancer, endoscopic CO₂ laser microsurgery followed by radiation or chemoradiation therapy is a useful therapy.

6. Acknowledgments

We thank Jun-ichi Fukaura, ST, for his technical assistance. This work is partly supported by the Japanese Foundation for Multidisciplinary Treatment of Cancer and a Grant-in-Aid for Encouragement of Young Scientists, (No. 12770975) from the Japan Society for Promotion of Science. This work was presented in part at the 18th UICC International Cancer Congress, Oslo, Norway, 30 June-5 July, 2002.

REFERENCES

- [1] H. Miyahara, "Cigarette Smoking as a Carcinogenesis Risk Factor in Cancer of the Larynx and Pharynx," *Journal of the Japan Broncho-Esophagological Society*, Vol. 56, No. 5, 2005, pp. 383-393. [doi:10.2468/jbes.56.383](https://doi.org/10.2468/jbes.56.383)
- [2] S. W. Barthel and R. M. Esclamado, "Primary Radiation Therapy for Early Glottic Cancer," *Otolaryngology—Head and Neck Surgery*, Vol. 124, No. 1, 2001, pp. 35-39. [doi:10.1067/mhn.2001.112574](https://doi.org/10.1067/mhn.2001.112574)
- [3] L. P. Bron, D. Soldati, A. Zouhair, M. Ozsahin, E. Brosard, P. Monnier and P. Pasche, "Treatment of Early Stage Squamous-Cell Carcinoma of the Glottic Larynx: Endoscopic Surgery or Cricohyoidoepiglottopexy versus Radiotherapy," *Head and Neck*, Vol. 23, No. 10, 2001, pp. 823-829. [doi:10.1002/hed.1120](https://doi.org/10.1002/hed.1120)
- [4] E. de Campora, M. Radici and L. de Campora, "External versus Endoscopic Approach in the Surgical Treatment of Glottic Cancer," *European Archives of Oto-Rhino-Laryngology*, Vol. 258, No. 10, 2001, pp. 533-536. [doi:10.1007/s004050100402](https://doi.org/10.1007/s004050100402)
- [5] H. E. Eckel, W. Thumfart, M. Jungehülsing, C. Sittel and E. Stennert, "Transoral Laser Surgery for Early Glottic Carcinoma," *European Archives of Oto-Rhino-Laryngology*, Vol. 257, No. 4, 2000, pp. 221-226. [doi:10.1007/s004050050227](https://doi.org/10.1007/s004050050227)
- [6] Y. Kumamoto, M. Masuda, Y. Kuratomi, S. Toh, A. Shinokuma, K. Chujo, T. Yamamoto and S. Komiyama, "FAR Chemoradiotherapy Improves Laryngeal Preservation Rates in Patients with T2N0 Glottic Carcinoma," *Head and Neck*, Vol. 24, No. 7, 2002, pp. 637-642. [doi:10.1002/hed.10114](https://doi.org/10.1002/hed.10114)
- [7] O. Laccourreye, R. Gutierrez-Fonseca, D. Garcia, S. Hans, N. Hacquart, M. Ménard and D. Brasnu, "Local Recurrence after Vertical Partial Laryngectomy, a Conservative Modality of Treatment for Patients with Stage I-II Squamous Cell Carcinoma of Glottis," *Cancer*, Vol. 85, No. 12, 1999, pp. 2549-2556. [doi:10.1002/\(SICI\)1097-0142\(19990615\)85:12<2549::AID-CNCR9>3.0.CO;2-M](https://doi.org/10.1002/(SICI)1097-0142(19990615)85:12<2549::AID-CNCR9>3.0.CO;2-M)
- [8] G. Motta, E. Esposito, B. Cassiano and S. Motta, "T1-T2-T3 Glottic Tumors: Fifteen Years Experience with CO₂ Laser," *Acta Oto-Laryngologica (Supplementum)*, Vol. 527, 1997, pp. 155-159. [doi:10.3109/00016489709124062](https://doi.org/10.3109/00016489709124062)
- [9] M. Sawatsubashi, K. Tsuda, K. Suzuki, S. Takagi, A. Inokuchi and T. Shin, "Endoscopic CO₂ Laser Surgery for T1N0 Glottic Carcinoma," *Japanese Journal of Cancer Clinics*, Vol. 47, No. 5, 2001, pp. 413-419.
- [10] M. Remacle, H. E. Eckel, A. Antonelli, D. Brasnu, D. Chevalier, G. Friedrich, J. Olofsson, H. H. Rudert, W. Thumfart, M. de Vincentiis and T. P. Wustrow, "Endoscopic Cordectomy: A Proposal for a Classification by the Working Committee, European Laryngological Society," *European Archives of Oto-Rhino-Laryngology*, Vol. 257, No. 4, 2000, pp. 227-231. [doi:10.1007/s004050050228](https://doi.org/10.1007/s004050050228)
- [11] L.-X. Yang, E. B. Double, J. A. O'Hara and H.-J. Wang, "Carboplatin Enhances the Production and Persistence of Radiation-Induced DNA Single-Strand Breaks," *Radiation Research*, Vol. 143, No. 3, 1995, pp. 302-308. [doi:10.2307/3579217](https://doi.org/10.2307/3579217)
- [12] L. X. Yang, E. B. Double and H.-J. Wang, "Irradiation Enhances Cellular Uptake of Carboplatin," *International Journal of Radiation Oncology Biology Physics*, Vol. 33, No. 3, 1995, pp. 641-646. [doi:10.1016/0360-3016\(95\)00202-A](https://doi.org/10.1016/0360-3016(95)00202-A)
- [13] H. H. W. de Gier, P. P. M. Knegt, M. F. de Boer, C. A. Meeuwis, L.-A. van der Velden and J. D. F. Kerrebijn, "CO₂-Laser Treatment of Recurrent Glottic Carcinoma," *Head and Neck*, Vol. 23, No. 3, 2001, pp. 177-180. [doi:10.1002/1097-0347\(200103\)23:3<177::AID-HED1015>3.0.CO;2-8](https://doi.org/10.1002/1097-0347(200103)23:3<177::AID-HED1015>3.0.CO;2-8)

- [14] M. Hirano, S. Saito, M. Sawashima, S. Hiki and H. Hirose, "A Guideline for Vocal Function Tests," *Journal of the Japan Broncho-Esophagological Society*, Vol. 23, No. 2, 1982, pp. 164-167. [doi:10.5112/jjlp.23.164](https://doi.org/10.5112/jjlp.23.164)
- [15] J. T. Kenedy, P. M. Paddle, B. J. Cook, P. Chapman and T. A. Iseli, "Voice Outcomes Following Transoral Laser Microsurgery for Early Glottis Squamous Cell Carcinoma," *The Journal of Laryngology & Otology*, Vol. 121, No. 12, 2007, pp. 1184-1188. [doi:10.1017/S0022215107007554](https://doi.org/10.1017/S0022215107007554)
- [16] G. Kanonier, E. Fritsch, T. Rainer and W. F. Thumfart, "Radiotherapy in Early Glottic Carcinoma," *The Annals of Otology, Rhinology and Laryngology*, Vol. 105, No. 10, 1996, pp. 759-763.
- [17] E. Medini, I. Medini, K. K. Chung, M. Gapany and S. H. Levitt, "Curative Radiotherapy for Stage II-III Squamous Cell Carcinoma of the Glottic Larynx," *American Journal of Clinical Oncology*, Vol. 21, No. 3, 1998, pp. 302-305. [doi:10.1097/00000421-199806000-00021](https://doi.org/10.1097/00000421-199806000-00021)
- [18] J. H. Brandenburg, "Laser Cordotomy versus Radiotherapy: An Objective Cost Analysis," *The Annals of Otology, Rhinology and Laryngology*, Vol. 110, No. 4, 2001, pp. 312-318.
- [19] E. N. Myers, R. L. Wagner and J. T. Johnson, "Microlaryngoscopic Surgery for T1 Glottic Lesions: A Cost-Effective Option," *The Annals of Otology, Rhinology and Laryngology*, Vol. 103, No. 1, 1994, pp. 28-30.
- [20] K. G. Delsupehe, I. Zink, M. Lejaegere and R. W. Bastian, "Voice Quality after Narrow-Margin Laser Cordectomy Compared with Laryngeal Irradiation," *Otolaryngology—Head and Neck Surgery*, Vol. 121, No. 5, 1999, pp. 528-533. [doi:10.1016/S0194-5998\(99\)70051-3](https://doi.org/10.1016/S0194-5998(99)70051-3)
- [21] D. M. Hartl, A. Ferlito, D. F. Brasnu, J. A. Langendijk, A. Rinaldo, C. E. Silver and G. T. Wolf, "Evidence-Based Review of Treatment Options for Patients with Glottic Cancer," *Head and Neck*, Vol. 33, No. 11, 2011, pp. 1638-1648. [doi:10.1002/hed.21528](https://doi.org/10.1002/hed.21528)
- [22] M. Quer, X. Leon, C. Orus, P. Venegas, M. López and J. Burgués, "Endoscopic Laser Surgery in the Treatment of Radiation Failure of Early Laryngeal Carcinoma," *Head and Neck*, Vol. 22, No. 5, 2000, pp. 520-523. [doi:10.1002/1097-0347\(200008\)22:5<520::AID-HED13>3.0.CO;2-K](https://doi.org/10.1002/1097-0347(200008)22:5<520::AID-HED13>3.0.CO;2-K)