

Cholecystoduodenocolic Fistula: An Unexpected Intraoperative Finding, a Surgical Challenge

Gulzar Ahmad Bhat, Rahul Jain, Pawan Lal

Gen. & Minimal Access Surgery, Lok Nayak Hospital, Maulana Azad Medical College, New Delhi, India
Email: drbhatgulzar@gmail.com

Received 4 March 2016; accepted 16 April 2016; published 19 April 2016

Copyright © 2016 by authors and Scientific Research Publishing Inc.
This work is licensed under the Creative Commons Attribution International License (CC BY).
<http://creativecommons.org/licenses/by/4.0/>



Open Access

Abstract

The bilioenteric fistulas, first described in 1890 by Courvoisier, are found in 0.15% - 8% of biliary tract operations. Combined fistulas involving the gallbladder, duodenum and colon are extremely rare. We presented a case of 38 year female who presented to our OPD with complaints of pain right upper abdomen for seven months in whom a cholecysto-duodenocolic fistula (**Figure 1 & Figure 2**) was found during surgery which was repaired primarily. Gallstone disease is a common problem in hepatobiliary system and may rarely present as cholecysto-enteric fistula. The most common type of biliary enteric fistula is Cholecystoduodenal fistula (70%). Cholecysto-duodenocolic (CDC) fistula is a rare complication of cholelithiasis. The standard treatment of IBF is cholecystectomy and repair of the fistulous opening. Although very rare a cholecystoduodenocolic fistula should be kept as a possibility when there are adhesions between GB, duodenum and colon. Conversion to open surgery should be considered early when the anatomy is not clear to prevent iatrogenic injury.

Keywords

Fistula, Cholecystectomy, Cholecystoduodenocolic Fistula

1. Introduction

A biliary fistula is an abnormal passage or communication from the biliary system to an organ, cavity, or free surfaces. Fistula are classified as external (biliary-cutaneous) or internal (biliobiliary, bilioenteric, bronchobiliary) [1]. The bilioenteric fistulas, first described in 1890 by Courvoisier, were found in 0.15% - 8% of biliary

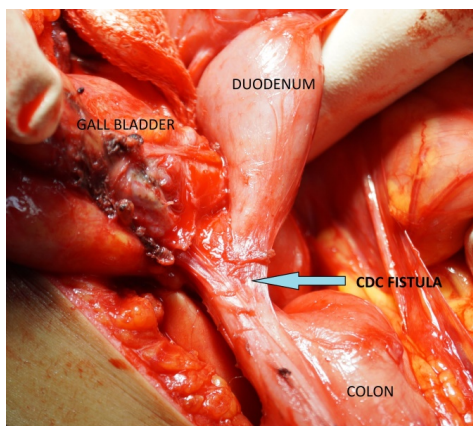


Figure 1. Image showing Cholecysto-duodeno-colic (CDC fistula-shown by arrow).

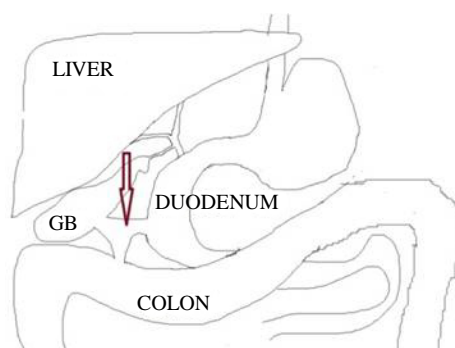


Figure 2. Representational diagram of Cholecysto-duodeno-colic fistula (arrow).

tract operations. Out of which about 70% are Cholecystoduodenal and 8% to 26.5% are cholecystocolic and usually located at the hepatic flexure, with higher incidence in the elderly and in women [2]-[5]. Internal biliary fistula (IBF) is associated with chronic cholelithiasis in 90% of the cases. Preoperative diagnosis of IBF is difficult [6]. As the symptoms of IBF include abdominal pain, fever, nausea, vomiting, flatulence, fat intolerance, diarrhoea and weight loss, which are all non-specific and seen in most gastrointestinal pathologies, the diagnosis is often not suspected preoperatively [7]. The diagnosis is usually made preoperatively [8]-[10].

Cholecystocolic fistula (CCF) is a late complication of long-lasting gallstone disease and is found in roughly 1 in every 1,000 cholecystectomies. It is the second most common cholecystoenteric fistula after the Cholecystoduodenal [11]-[13].

Symptoms of CCF are usually minimal and/or non-specific, and preoperative diagnostic tools often fail to show such a rare condition, hence diagnosis is often achieved intraoperatively [14] [15].

Combined fistulas involving the gallbladder, duodenum and colon are extremely rare [16]. A double communication of the gallbladder with both the duodenum and colon is rare in this condition, only five previous cases having been recorded in the English literature (Dormal, Estacio and Sherman, 1975; Dowse, 1963; Pitman and Davies, 1963; Shocket, Evans and Jones, 1970) [17].

Objective: Cholecystoduodenocolic fistula which is one of the rarest complications of gall bladder stones can be difficult to diagnose preoperatively and needs an early suspicion intraoperatively to prevent injury to adjacent structures.

2. Case Report

We report a case of 38 year female who presented to our OPD with complaints of pain right upper abdomen for seven months. Pain was of moderate intensity continuous and non-radiating. Patient had no history of jaundice

and intestinal obstruction. There was no history of any abdominal surgery in the past. Patient had no history of any bowel pathology. There was no other significant complaint. General physical examination was normal with no signs of any nutritional deficiencies. Local examination of the abdomen was normal with no palpable organomegaly and no free fluid. Patients hemoglobin was 13.4 gm/dl, total bilirubin was 0.5 mg/dl, alkaline phosphatase was 48 IU/L. Ultrasonography (USG) abdomen revealed contracted Gall bladder (GB) with a single calculus in neck region with 3.5 mm wall thickness. CBD was normal. Patient was worked up for laparoscopic cholecystectomy.

Laparoscopic cholecystectomy was done after taking down adhesions. Callot's anatomy was found to be distorted. After meticulous dissection the duodenum and transverse colon were found adherent to gall bladder. With high suspicion of a Cholecystoduodenal fistula and non-progression of surgery by laparoscopy, it was decided by surgical team to convert the procedure to open. GB was dissected by fundus first method. A cholecysto-duodenocolic fistula (CDCF) (**Figure 1**) was found as the adhesions between GB and Duodenum and colon were taken down by sharp dissection. The fistulous tract was excised. Colon repaired primarily and duodenum was repaired by omental patch. Cholecystectomy was completed and abdomen closed. Postoperative period was uncomplicated and patient was discharged on sixth post-operative day. Patient has been under regular follow up since last 3 months and is doing fine.

3. Discussion

Gallstone disease is a common problem in Indian subcontinent. It can present as acute cholecystitis, gall stone pancreatitis, obstructive jaundice, gallstone ileus or cholecysto-enteric fistula. Although many patients will be asymptomatic and may present as an incidental finding on imaging done for some other reason.

The most common type of biliary enteric fistula is Cholecystoduodenal fistula (70%) followed by cholecystocolic fistula (8% - 26%) [2]-[5] and the least common cholecystogastric fistula. The reported incidence of internal biliary fistulas is about 2% of total biliary diseases [18]. The most common cause is pressure necrosis due to an impacted gallstone usually in the neck of gallbladder, which gradually erodes into the duodenum [19].

Cholecystoduodenocolic (CDC) fistula is a rare complication of cholelithiasis. Only 21 examples had been reported up to 1984 [17]. High index of suspicion might help to diagnose it preoperatively.

The standard treatment of internal biliary fistula (IBF) is cholecystectomy and repair of the fistulous opening [20]. Modern techniques in laparoscopy should allow safe laparoscopic cholecystectomy, even for patients with cholecystoduodenocolic fistula. The fistulous tract can be divided by an endo-GI stapler. It may be safer to convert to open surgery when the anatomy is not clear or the expertise is not available.

4. Conclusion

Although very rare a cholecystoduodenocolic fistula should be kept as a possibility when there are dense adhesions between gall bladder, duodenum and colon. Conversion to open surgery should be considered early when the anatomy is not clear to prevent iatrogenic injury.

References

- [1] Safaie-Shirazi, S., Zike, W.L. and Printen, K.J. (1973) Spontaneous Enterobiliary Fistulas. *Surgery, Gynecology & Obstetrics*, **137**, 769-772.
- [2] Balent, E., Plackett, T.P. and Lin-Hurtubise, K. (2012) Cholecystocolonic Fistula. *Hawai'i Journal of Medicine & Public Health*, **71**, 155-157.
- [3] Chowbey, P.K., Bandyopadhyay, S.K., Khullar, R. and Baijal, M. (2006) Laparoscopic Management of Cholecystoenteric Fistulas. *Journal of Laparoendoscopic & Advanced Surgical Techniques*, **16**, 467-472. <http://dx.doi.org/10.1089/lap.2006.16.467>
- [4] Costi, R., Randone, B., Violi, V., Scatton, O., Sarli, L., Soubrane, O., Dousset, B. and Montariol, T. (2009) Cholecystocolonic Fistula: Facts and Myths. A Review of the 231 Published Cases. *Journal of Hepato-Biliary-Pancreatic Surgery*, **16**, 8-18. <http://dx.doi.org/10.1007/s00534-008-0014-1>
- [5] Angrisani, L., Corcione, F., Tartaglia, A., Tricarico, A., Rendano, F., Vincenti, R., Lorenzo, M., Aiello, A., Bardi, U., Bruni, D., Candela, S., Caracciolo, F., Crafa, F., De Falco, A., De Werra, C., D'Errico, R., Giardiello, C., Petrillo, O. and Rispoli, G. (2001) Cholecystoenteric Fistula (CF) Is Not a Contraindication for Laparoscopic Surgery. *Surgical Endoscopy*, **15**, 1038-1041. <http://dx.doi.org/10.1007/s004640000317>

- [6] Sapula, R. and Skibinski, W. (2002) Gallstone Ileus as a Complication of Cholecystolithiasis. *Surgical Endoscopy*, **16**, 360. <http://dx.doi.org/10.1007/s00464-001-4221-y>
- [7] Le Blanc, K.A., Barr, L.H. and Rush, B.M. (1983) Spontaneous Biliary Enteric Fistulas. *Southern Medical Journal*, **76**, 1249-1252. <http://dx.doi.org/10.1097/00007611-198310000-00013>
- [8] Inal, M., Oguz, M., Aksungur, E., Soyupak, S., Boruban, S. and Akgul, E. (1999) Biliary-Enteric Fistulas: Report of Five Cases and Review of the Literature. *European Radiology*, **9**, 1145-1151. <http://dx.doi.org/10.1007/s003300050810>
- [9] Schumacher, G., Keck, H. and Neuhaus, P. (1996) Cholecystoduodenal Fistula with Subsequent Gallstone Ileus: Case Report of an Unusual Course. *Zentralbl Chir*, **121**, 408-411.
- [10] Angrisani, L., Corcione, F., Tartaglia, A., Tricarico, A., Rendano, F., Vincenti, R., Lorenzo, M., Aiello, A., Bardi, U., Bruni, D., Candela, S., Caracciolo, F., Crafa, F., De Falco, A., De Werra, C., D'Errico, R., Giardiello, C., Petrillo, O. and Rispoli, G. (2001) Cholecystoenteric Fistula (CF) Is Not a Contraindication for Laparoscopic Surgery. *Surgical Endoscopy*, **15**, 1038-1041. <http://dx.doi.org/10.1007/s004640000317>
- [11] Glenn, F., Reed, C. and Grafe, W.R. (1981) Biliary Enteric Fistula. *Surgery, Gynecology & Obstetrics*, **153**, 527-531.
- [12] Angrisani, L., Corcione, F., Tartaglia, A., Tricarico, A., Rendano, F., Vincenti, R., et al. (2001) Cholecystoenteric Fistula (CF) Is Not a Contraindication for Laparoscopic Surgery. *Surgical Endoscopy*, **15**, 1038-1041. <http://dx.doi.org/10.1007/s004640000317>
- [13] Chowbey, P.K., Bandyopadhyay, S.K., Sharma, A., Khullar, R., Soni, V. and Baijal, M. (2006) Laparoscopic Management of Cholecystoenteric Fistulas. *Journal of Laparoendoscopic & Advanced Surgical Techniques Part A*, **16**, 467-472. <http://dx.doi.org/10.1089/lap.2006.16.467>
- [14] Angrisani, L., Corcione, F., Tartaglia, A., Tricarico, A., Rendano, F., Vincenti, R., et al. (2001) Cholecystoenteric Fistula (CF) Is Not a Contraindication for Laparoscopic Surgery. *Surgical Endoscopy*, **15**, 1038-1041. <http://dx.doi.org/10.1007/s004640000317>
- [15] Chowbey, P.K., Bandyopadhyay, S.K., Sharma, A., Khullar, R., Soni, V. and Baijal, M. (2006) Laparoscopic Management of Cholecystoenteric Fistulas. *Journal of Laparoendoscopic & Advanced Surgical Techniques Part A*, **16**, 467-472. <http://dx.doi.org/10.1089/lap.2006.16.467>
- [16] Nenihauser, G.N.M. and Thonipson, J.C. (1966) Cholecystoduodenocolic Fistula Due to Gallstones: Case Report. *Annals of Surgery*, **163**.
- [17] Ross, G.B. (1984) Cholecystoduodenocolic Fistula and Gallstone Ileus. *Postgraduate Medical Journal*, **60**, 698-699.
- [18] Yamashita, H., Chijiwa, K., Ogawa, Y., et al. (1997) The Internal Biliary Fistula Reappraisal of Incidence, Type, Diagnosis and Management of 33 Consecutive Cases Surgery. *HPB Surgery*, **10**, 143-147. <http://dx.doi.org/10.1155/1997/95363>
- [19] Attri, M.R., Ahangar, S. and Bhardwaj, R. (2010) Cholecystoduodenal Fistula: An Intraoperative Diagnosis. *JK Science*, **12**.
- [20] Duzgun, A.P., Ozmen, M.M., Ozer, M.V. and Coskun, F. (2007) Internal Biliary Fistula Due to Cholelithiasis: A Single-Centre Experience. *World Journal of Gastroenterology*, **13**, 4606-4609. <http://dx.doi.org/10.3748/wjg.v13.i34.4606>