

Shape Misleading of Hydatid Cyst*

M. Moujahid[#], K. Chakoura, Y. Issaoui, I. Ennafae, M. Ghari, My. H. Tahiri

Department of General Surgery, 5th Military Hospital, Guelmim, Morocco.

Email: [#]m.moujahid@gmx.fr

Received February 5th, 2012; revised March 6th, 2012; accepted March 18th, 2012

Copyright © 2013 M. Moujahid *et al.* This is an open access article distributed under the Creative Commons Attribution License, which permits unrestricted use, distribution, and reproduction in any medium, provided the original work is properly cited.

ABSTRACT

The hydatidosis is a problem of public health in the zones of rising of the developing countries. It is an anthroponose due to the development at the man of the larva of *Echinococcus granulosus*. The localizations at the man are varied, unique or multiple, isolated or associated of which the chief of thread is represented by the liver and the lung. We report a misleading revelation of the hydatid cyst of the psoas.

Keywords: Muscular Hydatid Cyst; Psoas; Unaccustomed Localizations; Diagnosis and Treatment

1. Introduction

The echinococcosis is a cosmopolitan antropozoonosis, affecting the man and some mammals, connected to the development in the body of the embryonic shape of a tape worm of the dog called *Echinococcus granulosus*.

The muscular localization of the hydatid cyst is rare and unusual even in the endemic countries. The clinical symptom is aspecific, its diagnosis bases essentially on the imaging. It is the disease which raises a real problem of public health in our country. The muscular localization occupies usually the fourth rank after the liver, lung and the spleen location. The embryo hexacanth has to cross the liver and the lung which are important filters before arriving at muscles. Besides the muscular fiber is the seat of a contractility and a production of lactic acid, which prevents the development of the parasite in the muscle. This hydatidosis affects preferentially proximal muscles, being this probably of in their wealth vascular with a big blood flow at their level.

The muscular hydatidosis is a rare affection and the effect of the psoas seems exceptional; even in country of endemic disease.

The rarity of this localization and its clinical polymorphism make the interest of this study. We report a

hydatid cyst of psoas of a misleading revelation.

2. Observation

34-year-old Mr HB admitted in the service of neurosurgery on 7/12/2008 for a medical coverage of a right para-vertebral collection in a feverish condition with lumbago and a loss of weight calculated to 10 kg in two months associated with a swelling of the iliac fossa and the right inguinal fold (**Figure 1**). The spondylitis diagnosis of a tubercular origin was recalled. The abdominal echography showed a right collection para vertebral spread at the crista iliaca. The pelvic abdomino scanner showed the presence of a collection divided up in touch with the muscle psoas and the right ilio psoas (**Figure 2**). The bio-

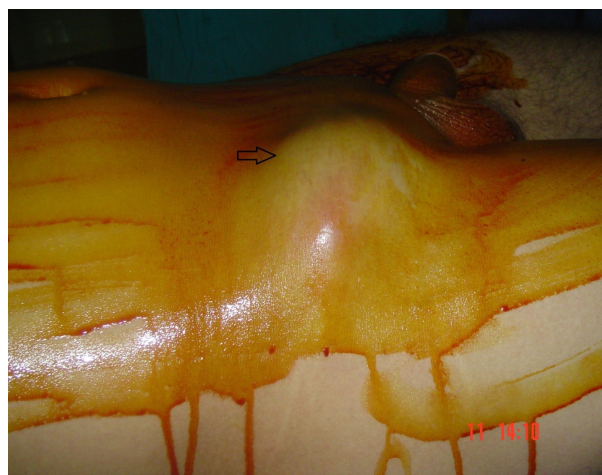


Figure 1. Mass of the iliac pit and the fold of the groin right.

*Authors' Contributions: Moujahid M and MY H Tahiri have inspired the idea, collected the case, analysis and wrote most of the manuscript. Chakoura K and Issaoui Y helped in collecting the data. Ennafae I and EL Ghari have performed the sonography. All authors read and approved the final manuscript.

Competing interests: The authors declare that they have no competing interests.

[#]Corresponding author.

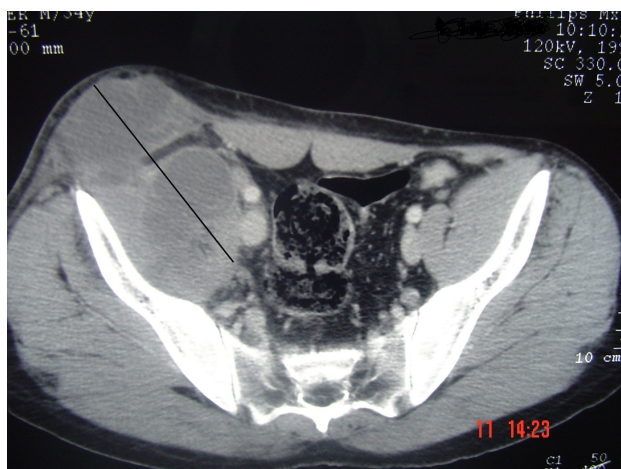


Figure 2. Abdomino pelvic scan showing the presence of a collection in the muscle psoas and the right ilio psoas.

logical balance sheet showed a hyperleukocytosis. BK research in the spit and urine was negative as well as the skin test in the tuberculin. The lung radiography was normal. The diagnosis of an abscess of psoas was held and the patient was sent to our service for medical care coverage. He was operated with discovery of a hydatid cyst of psoas per operation spurting out at the level of the ilio psoas and at the level of the fold of the groin. After a protection by fields soaked in the hydrogen peroxide and the inhalation of the content of the cyst and cleaning by serum and hydrogen peroxide. A pericystectomy was revealed with a good clinical and radiological evolution. The post surgery results were simple with a drop of 4 years without any sign of recurrence.

3. Discussion

The hydatidosis rages in an endemic way in certain countries of the Mediterranean Basin in Oceania and in South America. It is a disease of the rural world in the traditional breeding areas. It is an anthroponosis due to the development of Man's larva of the taenia *Echinococcus granulosus*.

The definitive host is represented by the dog; the man integrates accidentally in the cycle of the parasite. Embryonic eggs, eliminated from the exterior environment with the saddles of the dog, are ingested, penetrate into the digestive wall, through the liver, sometimes exceed the hepatic veins and reach the lungs. Other unusual localizations were reported in particular the bone 1% - 3%, pleura or peritoneum 4% - 7%, spleen and kidney 2% - 5%, brain 1% - 5%, heart 0.5% - 2% of the hydatid localizations [1]. More exceptionally the thyroid, the pancreas, the ovaries, the joints, the mild parts subcutaneous and muscular.

The skeletal muscle is the position of 1% of the hydatid localizations of man [2], the muscular localizations

reported are the diaphragm [3], the big pectoral muscle, the brachial muscles, the sartorius [4] and the psoas muscle [5-7] as in our case.

The muscle is generally very resistant in the hydatidosis because it tends to divide and encapsulate the larva as well as the contractile activity and the production of lactic acid [1,2,8].

On the clinical plan it is necessary to emphasize the usual latency of the clinical symptoms, which appear as sluggish tumefaction increasing in volume gradually, sometimes by signs of compression or feigning another pathology as pathological vertebral fracture or spondylitis [9,10] as it was the case of our patient.

The preoperative diagnosis is sometimes difficult because the biological examinations and the hydatid serology are usually negative because of the encapsulation of the larva. The radiography of the abdomen without preparation can show an opacity falling on the axis of the psoas and the disappearance of the external edge of this muscle, Sometimes calcifications under forms of curvilinear border [3,5,6].

The echography and the scanner can direct the diagnosis by showing a fluid image more or less heterogeneous with sometimes a visualization of daughter cysts [1,3,8]. Magnetic resonance imaging more precise in the determination of the morphology, the topography and the connections with the nearby structures in particular vasculo nervous [2,7]. The treatment is essentially surgical. It is the only radical treatment allowing us to confirm the diagnosis and to ensure a complete cure.

4. Conclusions

The hydatid cyst of psoas is a rare affection with slow development which can take a misleading form. It is always necessary to think of it especially concerning the persons living in a country with high endemic disease and to ask for necessary complementary examinations to make the diagnosis and avoid therapeutic errors.

The eradication of this affection requires prevention by the sanitary education of the populations, the supervision of the slaughter of animals, the treatment of the domestic dogs by Praziquantel and the systematic euthanasia of stray dogs.

REFERENCES

- [1] M. Amrani, F. Zouaidia, M. A. Belabbas, *et al.*, "Hydatidosis: About Some Unusual Locations," *Medicina Tropical*, Vol. 60, 2000, pp. 271-272.
- [2] N. Meddeb, N. Bahrouch, H. Elleuch, *et al.*, "Hydatid Cyst of the Adducteurs Muscles of the Thigh Aspect MRI, about a Case," *Bulletin de la Société de Pathologie Exotique*, Vol. 94, No. 2, 2001, pp. 106-108.
- [3] M. Daali and R. Hssaïda, "Muscular Hydatid: 15 cas,"

- Presse Medicale, Paris*, Vol. 28, No. 5, 2000, pp. 1166-1169
- [4] T. Hammami, F. Noomane, M. Ketata, *et al.*, "Muscular Hydatid Cyst of the Thigh: A Comment of Three Observations," *Revue de Chirurgie Orthopédique*, Vol. 88, 2002, pp. 193-196.
- [5] A. EL Moussaoui, R. Rabii, H. Rais, *et al.*, "Hydatid Cyst of the Psoas Muscle. A Case Report," *Annales d'Urologie*, Vol. 31, No. 6-7, 1997, pp. 357-360.
- [6] A. Benchekroun, H. Jira, O. J. Cheikhani, *et al.*, "Hydatid Cyst of the Psoas: A Case Report," *Annals of Urology*, Vol. 35, No. 2, 2001, pp. 108-110.
[doi:10.1016/S0003-4401\(01\)00012-2](https://doi.org/10.1016/S0003-4401(01)00012-2)
- [7] M. Melis, L. Marongiu, F. Scintu, Pisano and M. Giuseppe, "Primary Hydatid Cysts of Psoas Muscle," *ANZ Journal of Surgery*, Vol. 72, No. 6, 2002, pp. 443-445.
[doi:10.1046/j.1445-2197.2002.02420.x](https://doi.org/10.1046/j.1445-2197.2002.02420.x)
- [8] M. Daali, R. Bennani-Lahmam and A. Hajji, "Hydatid Cyst of the Psoas about 3 New Observations," *Lyon Chiropractic*, Vol. 2, No. 93, 1997, pp. 113-115.
- [9] S. A. Sakka, "Primitif Hydatid Cyst of the Thigh with Painful Demonstration at the Level of the Hip," *Reviews of Orthopaedic Surgery*, Vol. 79, 1993, pp. 226-228.
- [10] S. Karray, M. Karray, M. Zlitni and M. Douik, "Radical Cure of Vertebral Hydatidosis. A Case Report," *Acta Orthopaedica Belgica*, Vol. 70, No. 1, 2004, pp. 80-83.