

(Ventrodorsal) Symmetrical Bicornuate Uterus Mimicking a Pedunculated Myoma—A Case Report

Adam Moyosore Afodun^{1,2*}, Khadijah Kofoworola Quadri³, Mustapha Akajewole Masud⁴, Muhammad Olanrewaju Buhari¹, Sodiql Kolawole Lawal¹

¹Department of Anatomy, Faculty of Biomedical Science, Kampala International University, Kampala, Uganda

²Department of Radiology, Ultrasound and Doppler Unit, Crystal Specialist Hospital, Lagos, Nigeria

³Department of Physiology, College of Medicine, University of Lagos, Lagos, Nigeria

⁴Department of Anatomy, State University of Zanzibar, Zanzibar, Tanzania

Email: *afodunadam@yahoo.com

How to cite this paper: Afodun, A.M., Quadri, K.K., Masud, M.A., Buhari, M.O. and Lawal, S.K. (2017) (Ventrodorsal) Symmetrical Bicornuate Uterus Mimicking a Pedunculated Myoma—A Case Report. *Forensic Medicine and Anatomy Research*, 5, 33-38.

<https://doi.org/10.4236/fmar.2017.54004>

Received: October 3, 2017

Accepted: October 28, 2017

Published: October 31, 2017

Copyright © 2017 by authors and Scientific Research Publishing Inc.

This work is licensed under the Creative

Commons Attribution International

License (CC BY 4.0).

<http://creativecommons.org/licenses/by/4.0/>



Open Access

Abstract

Uterine anomalies account for about 4% in the most sampled population. Here we report a case of a 35 years old woman with occasional complaint of suprapelvic “heaviness”. She had an abnormal menstrual cycle for the last 6 years. Manual palpitations were unrevealing and she appeared externally healthy. HSG was earlier performed as part of a fertility intervention (wrongly concluding on a detached form of pedunculated-myoma). Ultrasound revealed 2 separated fundal-cones, uterine cavities and a single inferior cervix. Cyesis in the bicornuate uterus is usually high-risk, making patients with uterine anomalies prone to proven misdiagnosis (e.g. appendicitis) and infertility. In addition, sonar further showed bilateral ovarian torsion. Corrective surgery was done in a hospital; post surgical healing was normal and uneventful.

Keywords

Bicornuate, Ultrasound, Fertility, Population

1. Introduction

The Latin word “cornu” means horn. A bicornuate uterus, a fused type of uterine malformation in humans is “normal” amongst other mammals like rats, mice and pigs. Tubal Mullerian anomaly accounts for bicornuate 39%, arcuate 7%, septated-uterus 34%, aplastic > 5% and other uterine structural defects [1]. Bicornuate uterus being a disorder of Mullerian ducts [2] is distinct from type II

uterine didelphys which sometimes have two vaginas/external genitalia.

There are reported cases of IVF failure in a bicornuate uterus and some increased incidence of ectopic pregnancy complications [3]. Kumar *et al.* (2008) [4] in a study reported that MRI showing bicornuate uterus exposed cervical agenesis. Some studies [5] have cited septate uterus as the 2nd most common uterine anomaly after bicornuate uterus [6]. Surgically treated didelphic uterus according to Heinonen (2000) [7] has encouraging fertility prognosis when compared to a bicornuate uterus. Pregnancy rarely occurs in the horn of a unicornuate uterus [8].

A longitudinal study [9] observed that antenatal women with monitored (ultrasound) history were at lower risk of having uterine anomalies. Accurate statistical percentage and incidence of Mullerian abnormality in a population is difficult to estimate due to its rarity [10]. Malfusion of the mesonephric duct (Müllerian) *in utero* results in different uterine anomalies [11]. Data linking Caesarian sections, PROM (premature rupture of membrane), breach-lie/presentations to uterine anomalies are mostly from case reports, structural anatomic variations or micro-studies [12] [13] [14]. Advances in 3D and 4D (*i.e.*, 3D in real-time) ultrasound have led to non-invasive observations of these anomalies [9].

2. Case Report

A middle-aged woman suspected to be from a high-socio-economic background reported at the Radiological Department of Crystal Specialist Hospital (CSH), Dopemu-Akowonjo, Lagos, Nigeria. Ultrasound was performed with a Logic 3—Pro General Electric (GE) ultrasound machine (made in USA); 3.5 MHz curvilinear transducer. She had a turbulent menstrual cycle, with fluctuating amenorrhea and sometimes/occasional episodes of excessive bleeding. “Frozen” sonograms confirmed bicornuate uterus; though the (bilateral) ovaries were distal in position, they appeared normal in collaboration with structural anatomical plane.

Oral-patient interaction yielded no significant family history of rhesus-factor incompatibility, or consanguineous marriage by relatives. According to medical-records, the patient was nulliparous, weighed 61 kg and had copious “whitish” discharge noted by the attending physician during speculum examination of the cervix and external os. Informed consent was sought from patient and granted by Crystal Specialist Hospital for documentation of this case in line with the 1975 Helsinki Declaration on patient-rights and confidentiality.

Surgical treatment of the patient was not done or carried out in our hospital (CSH); however, information reached us that her postoperative recovery was uneventful with skin stitches removed after 8 days. Follow-up data also revealed dressing was done on the 2nd postoperative day and patient discharged on the 9th day.

3. Discussion

Diagnosis of a bicornuate uterus in other to differentiate it with split-uterine-didelphys

can be by hysteroscopy, ultrasound, HSG and laparoscopy. It should be noted that in a septated uterus, a thick persistent longitudinal septum partially separates the uterine cavity superiorly as opposed to a bicornuate variation (**Figure 1**). Our ultrasound findings are in agreement with a retrospective study [10] on didelphys uterus and bicornuate uteri; they (researchers) noted patients with the anomalies required sustained infertility treatments. Parallel to Jayasinghe *et al.* (2005) [15] and majority of obstetricians, if a confirmed diagnosis of cysis occurs in the rudimentary horn (see **Figure 2**, u2), immediate surgery must be performed. Since there is a failure in the complete development of both Mullerian ducts with incomplete fusion, the fused lower portion forms the main cervical and uterovaginal area (**Figure 2**, u1).

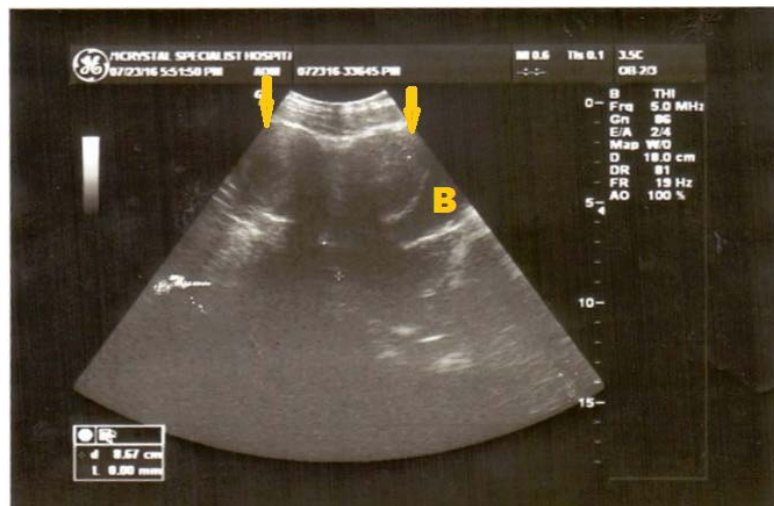


Figure 1. The 2 uterine cavities are separated at an angle of approximately 78° anteflexed. Observe the pressure indentation on posterior-inferior wall of urinary bladder (B).

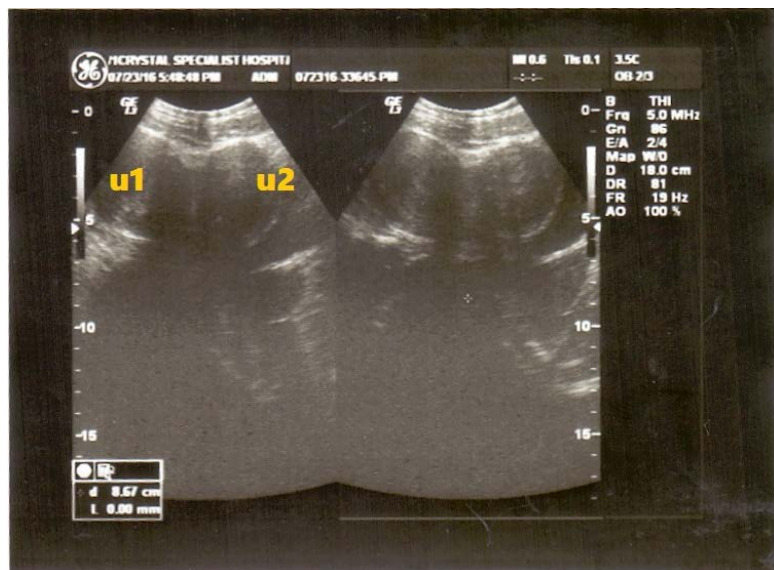


Figure 2. B mode-split image of (**Figure 1**) above. Note the supra-fundal area with the second horn (u2) mimicking a fibroid (benign) tumor (anteriorly).

Severe dysmenorrhea, occasional cervical duplication [16] make gravidae a daunting task in women with the bicornuate uterus; being mostly in “compressed” form of birth defects. **A plausible explanation for irregular uterine anomalies is decreased muscle mass and blood flow in uterine arteries.** Incidence of this rare anomaly varies and may affect gynecological structure and obstetric outcome [2]. Greater than 60% of women with malformed uterus may stay completely asymptomatic. Cephalic part of the bicornuate uterus appears bifurcated (Figure 1) while the caudal part is normal. The symmetry of uterine cavities in bicornuate uterus creates certain fissional communication inferiorly. In the branched horn (Figure 1) if the angle of one uterine cavity is equal or less than 75 degrees, a septate uterus is formed [17]. Likely haematometra and cryptomenorrhea is a chronology likely to develop in the rudimentary horn (Figure 2, u2).

In agreement with Reuter *et al.*, (1989) [17] sonography will rule-out pressure of pedunculated/fistulic or septated uterine component; since it is at a wide angle $75^\circ - 102^\circ$. In contrast to our case report, unicornuate uterus indicates “single-horned” with a RT or LT adnexae, with a small AP diameter parallel to the cervix; while a didelphic variant exhibits 2 (cervical and endometrial) canals [18] [19] [20]. Paired mesonephric ducts are incompletely fused in a “dented” fundus. Bicornuate uterus can also be caused by resorption defects, malrotation fusions during embryonic stage, with an angle separating the 2 horns not greater than ($>$) 105° [18]; as opposed to a normal uterus (control) seen in Figure 3, marked probe tenderness was present in the right fornix. Normal uteri women have better reproductive outcome and higher pregnancy rate compared with those with anomalies. Without a doubt, they belong to a high- risk group and it is of great importance for sonologists to detect reproductive tract anatomic variations by ultrasound early. The widely divergent apices and bi-fundus of the bicornuate uterus makes hysteroplastic unity a theoretical possibility.

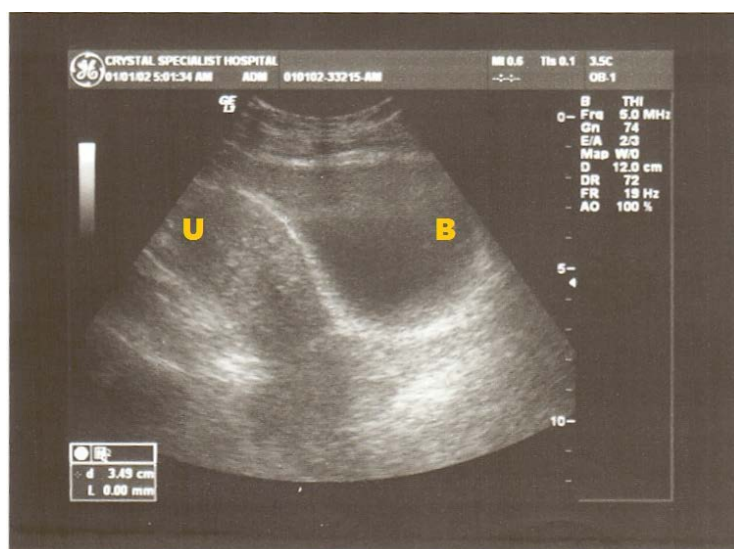


Figure 3. Control/normal longitudinal section of a non-gravid anteverted uterus (U) free of any pedunculated mass or attachment.

4. Conclusions

Conception and fertility in bicornuate uteri remains a controversial topic among radiologists and gynecologists. Elusive data on surgical correction: (partial) hysterectomy, metroplasty or myomectomy (as the case may apply) remains sparse.

Strassman's utriculoplasty surgery could be helpful in correcting women with a bicornuate uterus. This procedure will allow for fusion of the bi-uterine cavity and fundus. Incision for uniting uterine cavity improves parturitional outcome in bicornuate patients who had earlier suffered abortions. Real-time ultrasound should be considered to exclude Herlyn-Werner-Wunderlich (HWW) syndrome.

References

- [1] Cunningham, F.G., Leveno, K.J., Bloom, S.L., Hauth, J.C., Rose, D.J. and Spong, C.Y. (2010) Reproductive Tract Abnormalities. In: Cunningham, F.G., Ed., *Williams Obstetrics*, 23rd Edition, McGraw Hill, New York, 895-896.
- [2] Suwal, A. and Kumar, A. (2010) Complete Bicornuate Uterus with Complete Longitudinal Vaginal Septum. *Journal of Nepal Medical Association*, **49**, 243-246.
- [3] Singh, N., Singh, U. and Verma, M.L. (2013) Ruptured Bicornuate Uterus Mimicking Ectopic Pregnancy: A Case Report. *Journal of Obstetrics and Gynaecology Research*, **39**, 364-366. <https://doi.org/10.1111/j.1447-0756.2012.01914.x>
- [4] Kumar, S., Singh, S.K., Mavuduru, R., Naveen, A., Agarwal, M.M., Vanita, J., et al. (2008) Bicornuate Uterine Horns with Complete Cervical-Vaginal Agenesis and Congenital Vesico-Uterine Fistula. *International Urogynecology Journal and Pelvic Floor Dysfunction*, **19**, 739-741. <https://doi.org/10.1007/s00192-007-0507-5>
- [5] Nahum, G.G. (1998) Uterine Anomalies. How Common Are They, and What Is Their Distribution among Subtypes? *Journal of Reproductive Medicine*, **43**, 877-887.
- [6] Speroff, L. and Fritz, M.A. (2005) Clinical Gynecologic Endocrinology and Infertility. 7th Edition, Lippincott Williams & Wilkins, Philadelphia.
- [7] Heinonen, P.K. (2000) Clinical Implications of the Didelphic Uterus: Long Term Follow-Up of 49 Cases. *European Journal of Obstetrics and Gynecology and Reproductive Biology*, **91**, 183-190. [https://doi.org/10.1016/S0301-2115\(99\)00259-6](https://doi.org/10.1016/S0301-2115(99)00259-6)
- [8] Tufail, A. and Hasmi, H.A. (2007) Ruptured Ectopic Pregnancy in a Rudimentary Horn of the Uterus. *Journal of College of Physicians and Surgeons Pakistan*, **17**, 105-106.
- [9] Woelfer, B., Salim, R. and Jurkovic, D. (2001) Reproductive Outcomes in Women with Congenital Uterine Anomalies Detected by Three-Dimensional Ultrasound Screening. *Obstetrics & Gynecology*, **98**, 1099-1103.
- [10] Zhang, Y., Zhao, Y. and Qiao, J. (2010) Obstetric Outcome of Women with Uterine Anomalies in China. *Chinese Medical Journal*, **123**, 418-422.
- [11] Ahmad, F.K., Sherman, S.J. and Hagglund, K.H. (2000) Twin Gestation in a Woman with a Uterus Didelphys. A Case Report. *The Journal of Reproductive Medicine*, **45**, 357-359.
- [12] Reichman, D., Lauger, M.R. and Robinson, B.K. (2009) Pregnancy Outcomes in Unicornuate Uteri: A Review. *Fertility and Sterility*, **91**, 1886-1894.
- [13] Akar, M.E., Bayer, D., Yildiz, S., et al. (2005) Reproductive Outcome of Women with Unicornuate Uterus. *Australian and New Zealand Journal of Obstetrics and Gynaecology*, **45**, 148-150. <https://doi.org/10.1111/j.1479-828X.2005.00346.x>
- [14] Rackow, B.W. and Arici, A. (2007) Reproductive Performance of Women with Müller-

rian anomalies. *Current Opinion in Obstetrics & Gynecology*, **19**, 229-237.

<https://doi.org/10.1097/GCO.0b013e32814b0649>

- [15] Jayasinghe, Y., Rane, A. and Staleuki, H. (2005) The Presentation and the Early Diagnosis of a Rudimentary Horn. *Obstetrics & Gynecology*, **105**, 1456-1467.
<https://doi.org/10.1097/01.AOG.0000161321.94364.56>
- [16] Ribeiro, S.C., Yamakami, L.Y., Tormena, R.A., et al. (2010) Septate Uterus with Cervical Duplication and Longitudinal Vaginal Septum. *Revista Da Associacao Medica Brasileira*, **56**, 254-256. <https://doi.org/10.1590/S0104-42302010000200029>
- [17] Reuter, K.L., Daly, D.C. and Cohen, S.M. (1989) Septate versus Bicornuate Uteri: Errors in Imaging Diagnosis. *Radiology*, **172**, 749-752.
<https://doi.org/10.1148/radiology.172.3.2528160>
- [18] Zwiebel, W.J. (1983) Pelvic Congenital Anomalies and Pubertal Disorders. In: Zwiebel, W.J., Ed., *Introduction to Ultrasound*, Saunders, Philadelphia, 294-296.
- [19] Troiano, R.N. and McCarthy, S.M. (2004) Müllerian Duct Anomalies: Imaging and Clinical Issues. *Radiology*, **233**, 19-34.
- [20] Afodun, A.M., Ayinde, T.O., Quadri, K.K. and Masud, M.A. (2015) Concise Human Chorionic Atlas (Ultrasound, Gross, Histopathologic and Eponymical Approach). 1st Edition (Organ-Series), Xlibris Publishers, 50 p.
<https://www.xlibris.com/Bookstore/BookDetail.aspx?BookId=SKU-001001968>