

Hemorrhagic Valsalva Retinopathy in a Pregnant Woman

Charles Geraud Fredy Nganga Ngabou^{1,2*}, Chantal Makita¹, Bénédicte Diatewa²

¹Teaching University Hospital of Brazzaville, Brazzaville, Republic of Congo

²Ophthalmology Clinics, Brazzaville, Republic of Congo

Email: *fredygeraud@gmail.com

How to cite this paper: Nganga Ngabou, C.G.F., Makita, C. and Diatewa, B. (2018) Hemorrhagic Valsalva Retinopathy in a Pregnant Woman. *Case Reports in Clinical Medicine*, 7, 85-89.

<https://doi.org/10.4236/crcm.2018.72008>

Received: January 8, 2018

Accepted: January 30, 2018

Published: February 2, 2018

Copyright © 2018 by authors and Scientific Research Publishing Inc.

This work is licensed under the Creative Commons Attribution International License (CC BY 4.0).

<http://creativecommons.org/licenses/by/4.0/>



Open Access

Abstract

Valsalva retinopathy is caused by a sudden increase in intra-thoracic or abdominal pressure, following forced expiration, with mouth and nose closed (Valsalva maneuver). We report a case of Valsalva retinopathy in a pregnant woman. A 36 years old patient, pregnant at 24 weeks of amenorrhea, who consulted for sudden visual acuity decrease of the left eye, evolving since 24 hours after Valsalva maneuvers to calm down her panic and control her breathing. The refraction has demonstrated a decrease of visual acuity in the left eye to “can see a hand moving”, while the visual acuity remained normal in the right eye. Spontaneous evolution was marked by a fast and progressive reduction of hemorrhage and progressive recovery of vision in the left eye. Valsalva retinopathy was first described in 1972 by Thomas Duane. Physical activity is usually found before it occurs. Many situations are usually associated to this occurrence among which: pregnancy, vomiting, weightlifting or trauma. Regression of this hemorrhage without sequelae is usual. But sometimes, we need a Nd:Yag laser treatment or surgery to evacuate the blood.

Keywords

Valsalva Retinopathy, Pregnant Woman, Retinal Hemorrhage Macula

1. Introduction

Valsalva retinopathy is a rare disease characterized by a sudden visual loss due to pre-retinal hemorrhage, caused by a rapid increase in intraocular venous pressure [1]. It often occurs in healthy young adults, following various clinical contexts: intense aerobic exercise, defecation effort, vomiting and in many other circumstances. The associated visual loss can be profound if hemorrhage occurs in the pre-macular region. We report a case of Valsalva retinopathy in a preg-

nant woman.

This study aims to reinforce conservatory treatment in priority.

2. Case Report

This study aims to highlight the place of pregnancy in this pathology, and to show the therapeutic modalities. A 36-year-old patient who consulted for sudden decrease of visual acuity that had been evolving for 24 hours in the left eye. Pregnant of 24 weeks, she startled after being frightened, then she performed Valsalva maneuvers to calm down her panic and control her breathing. Visual acuity assessment showed an important decrease in the left eye to “see a hand moving”, while visual acuity in the right eye was 20/20. Fundus examination revealed a massive macular pre-retinal hemorrhage in the left eye. We see a bud in front of a temporal vessel of the lesion (**Figure 1**). The fundus of the right eye was normal.

The biological assessment performed by her obstetrician had found a normal platelet count, there was no blood-clotting. Retinal fluorescein angiography (FGA) performed two months later showed no leakage, justifying a spontaneous and isolated nature of the phenomenon without any other retinal lesion. A slower venous return to the arteriovenous time especially on the lower temporal vein, facing the bud (**Figure 2(a)**). Late-time dilatation of the same vein (**Figure 2(b)**) suggesting a venous hemorrhage.

Spontaneous evolution was marked by a fast and progressive reduction of hemorrhage and progressive recovery of vision in the left eye. At one month, the hemorrhage had reduced by almost a quarter (**Figure 3(a)**), and by two months by almost two-thirds (**Figure 3(b)**).

The patient gave birth vaginally at 37 weeks of pregnancy, without anesthesia, and without complications. Reviewed 2 months after vaginal delivery, that is 5 months after diagnosis, there was a complete anatomical and functional restoration, with a visual acuity of 20/20 in the left eye.

3. Discussion

Valsalva retinopathy was described for the first time by Duane in Philadelphia in 1972 [2] on a series of 3 patients composed of two women and one man. None of

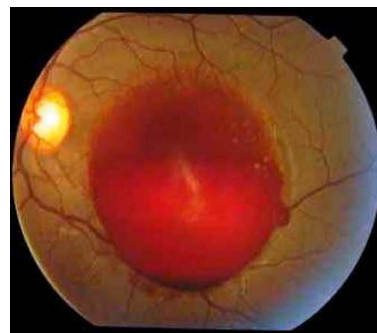


Figure 1. Massive pre-retinal hemorrhage.

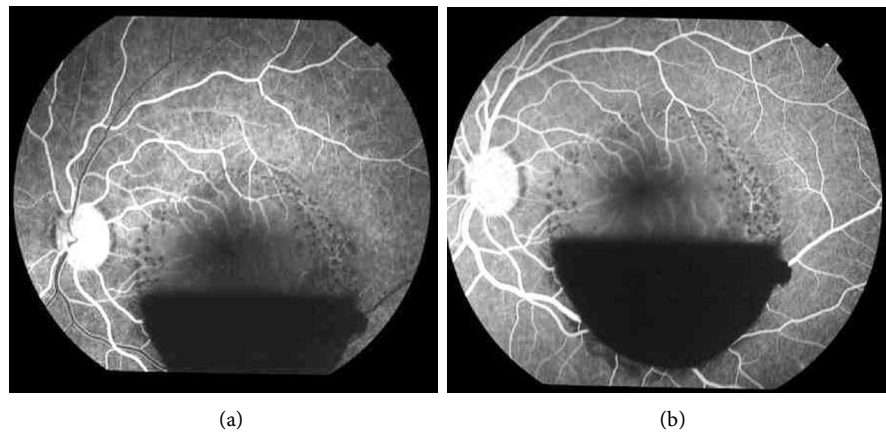


Figure 2. (a) Slower venous return on the lower temporal venous at the beginning of the arteriovenous time; (b) Late-time dilatation of the temporal lower vein.

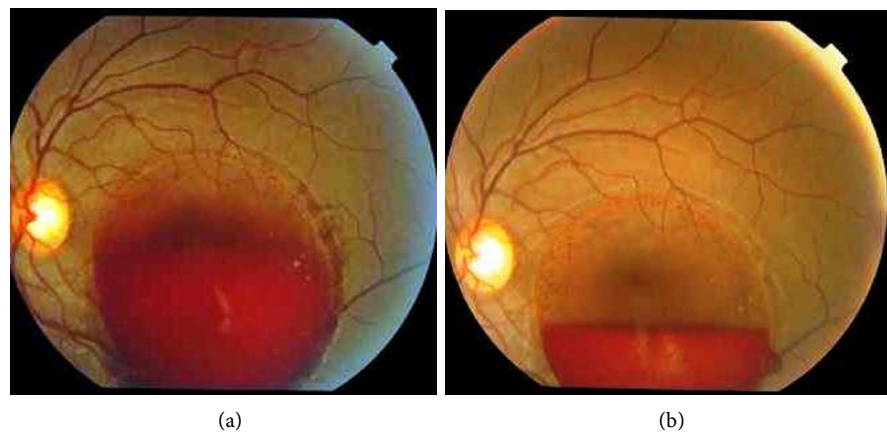


Figure 3. (a) Regression of hemorrhage 1 month later; (b) Regression of 2/3 of the hemorrhage 2 months later.

both women were pregnant. However, several authors have then described this pathology in pregnant women [1] [3] [4] [5] [6]. Pre-retinal hemorrhage is related to cephalic hypertension [7] [8].

The mechanism of this venous cephalic hypertension is explained by the Valsalva maneuver. There are anatomical adhesions of the vitreous to the retinal vessels. The thoracic hypertension by blocking in inspiration has repercussions on the cephalic venous circulation and then on the retinal venous one. Under the effect of retinal venous hypertension, the adhesions pull the vessel that breaks, it is the vitreous traction on a vein that causes its rupture [8] [9]. Kadrmaz [10] shows the rupture of a large superior temporal vein that is responsible for Valsalva hemorrhage. This let us mention a venous lesion, even though the lesion is not clear in our figures. In Valsalva hemorrhage case, initial lesion is not always visible [3].

During pregnancy, there is an increase in intra-abdominal pressure. With the Valsalva maneuvers, the pressure becomes considerable to cause the venous rupture [3] [4].

In our case, this maneuver was initially due to a reflex, because frightened the patient blocked her breathing in inspiration in a start, then voluntary hyperventilation to calm the panic.

In the case of Nghiem-Buffer, Tara F, Sanjeeva S and García-Fernández [1] [3] [4] [6], the maneuver was related to vomiting. El-Khayat [5] has found Yoga apnea exercises.

Aside from pregnant women, Valsalva hemorrhagic retinopathy has also been found regardless of sex, in other circumstances, such as: 1) after a sneeze crisis [8]; 2) in post coital [11]; 3) after general anesthesia associated with vomiting [1] [12]; 4) after traumatic thoracic compression [1]; 5) in the practice of weightlifting [1].

Expectancy is often recommended. The usual resorption of hemorrhage without sequelae is common [1] [4] [8] [11]. The timing of spontaneous resorption is very variable. In our case, it was 5 months, as for El-Khayat [5]. Guignon Souquet [8] noticed resorption after 8 months without treatment. Physical or surgical interventions are likely to bring visual recovery more quickly.

In a series of 6 cases of Valsava hemorrhage, García-Fernández [1] has realized for the first case a derivation of blood in the vitreous with Nd:Yag laser firstly, but the maneuver failed. Finally she performed a vitrectomy, and the patient indeed completely recovered his vision 10 days after operation. For the 4 remaining patients, vitrectomy was performed as first-intention with total visual recovery. For the last patient who had a small hemorrhage less troublesome for vision she had performed a conservative treatment and the haemorrhage resorbed spontaneously after one month.

In a series of 12 cases, Khan [13] performed Nd:Yag laser treatment on 11 patients without any complication, the 12th who preferred a conservative treatment recovered more slowly. Bypareddy [14] has noted an iatrogenic macular hole with Nd:Yag laser in the treatment of a case of pre-retinal hemorrhage, which shows that these interventions are associated with some degree of risk.

Despite the great potential of vaginal delivery to replicate the Valsalva maneuver [15], Wickremasinghe [6], who analyzed these deliveries in pregnant women with Valsalva hemorrhage, sustains that vaginal delivery without epidural or other intervention is the method that presents the least risk of hemorrhage aggravation.

4. Conclusion

Valsalva hemorrhagic retinopathy is a rare pathology that is often responsible for sudden unilateral poor vision associated with pre-macular retinal hemorrhage. Visual recovery usually occurs after six months without treatment. Nd:Yag laser treatment can quickly help to clear the posterior pole by dispersing the blood in the vitreous. Vitrectomy makes it possible to clean up all the hemorrhage more quickly. We should specify that these two interventions are not without complications.

Consent Statement

Written informed was obtained from the patient for publication of this case report and any accompanying images.

References

- [1] García-Fernández, M., Castro-Navarro, J. and Gonzalez-Castano, C. (2012) Long-Term Evolution of Valsalva Retinopathy: A Case Series. *Journal of Medical Case Reports*, **6**, 346. <https://doi.org/10.1186/1752-1947-6-346>
- [2] Duane, T.D. (1972) Valsalva Hemorrhagic Retinopathy. *Transactions of the American Ophthalmological Society*, **70**, 298-313.
- [3] Nghiem-Buffet, S. and Guiberteau, B. (2009) Rétinopathie de Valsalva et grossesse. *Images en Ophtalmologie*, **3**, 86-87.
- [4] Tara, F., Sharifi, M. and Hoseini, E. (2015) Valsalva Retinopathy in Pregnancy: A Case Report. *BMC Research*, **8**, 67. <https://doi.org/10.1186/s13104-015-1029-8>
- [5] El-Khayat, A.R. (2017) Valsalva Haemorrhagic Retinopathy in Pregnancy after Yoga. *BMJ Case Reports*, **11**. <https://doi.org/10.1136/bcr-2017-221099>
- [6] Wickremasinghe, S.S., Tranos, P.G. and Davey, C. (2003) Valsalva Haemorrhagic Retinopathy in a Pregnant Woman: Implications for Delivery. *Acta Ophthalmologica Scandinavica*, **81**, 420-422. <https://doi.org/10.1034/j.1600-0420.2003.00102.x>
- [7] Matonti, F., Donadieu, V., Hoffart, L., Dornadin, A., Nadeau, S., Roux, S. and Denis, D. (2013) Traitement précoce par laser Nd:YAG de la rétinopathie de Valsalva: Resultants à propos de cinq cas et revue de la littérature. *Journal Français d'Ophtalmologie*, **36**, 604-609. <https://doi.org/10.1016/j.jfo.2013.01.007>
- [8] Guigon-Souquet, B., Salaun, L., Macarez, R., Bazin, S., De La Manierre, E. and Mazdou, M. (2004) Hemorragie rétrohyaloïdienne secondaire à une manœuvre de Valsalva. *Journal Français d'Ophtalmologie*, **27**, 1159-1162. [https://doi.org/10.1016/S0181-5512\(04\)96288-2](https://doi.org/10.1016/S0181-5512(04)96288-2)
- [9] Takano, M., Sugiura, N., Yonemoto, J. and Ohno, S. (1993) Vitreous Hemorrhage Associated with Acute Posterior Vitreous Detachment—A Case Report. *Japanese Journal of Ophthalmology*, **37**, 199-203.
- [10] Kadrmas, E.F. and Pach, J.M. (1995) Vitreous Hemorrhage and Retinal Vein Rupture. *American Journal of Ophthalmology*, **120**, 114-115. [https://doi.org/10.1016/S0002-9394\(14\)73769-9](https://doi.org/10.1016/S0002-9394(14)73769-9)
- [11] Michaels, L., Tint, N.L. and Alexander, P. (2014) Postcoital Visual Loss Due to Valsalva Retinopathy. *BMJ Case Reports*.
- [12] Patane, P.S., Krummenacher, T.K. and Rao, R.C. (2015) Valsalva Hemorrhagic Retinopathy Presenting as a Rare Cause of Impaired Vision after a General Anesthetic—A Case Report and Review of the Literature. *Journal of Clinical Anesthesia*, **27**, 341-346.
- [13] Khan, M.T., Saeed, M.U., Shehzad, M.S. and Qazi, Z.A. (2008) Nd:YAG Laser Treatment for Valsalva Premacular Hemorrhages: 6 Month Follow up: Alternative Management Options for Preretinal Premacular Hemorrhages in Valsalva Retinopathy. *International Ophthalmology*, **28**, 325-327.
- [14] Bypareddy, R., Chawla, R., Azad, S.V. and Takkar, B. (2016) Iatrogenic Parafoveal Macular Hole Following Nd-l:YAG Posterior Hyaloidotomy for Premacular Haemorrhage. *BMJ Case Reports*.
- [15] Eneh, A. and Almeida, D. (2013) Valsalva Hemorrhagic Retinopathy during Labour: A Case Report and Literature Review. *Canadian Journal of Ophthalmology*, **48**, 145-147. <https://doi.org/10.1016/j.jcjo.2013.05.019>