

Five Centimeter Concrete Nail Aspiration in a 2-Year-Old Nigerian Child: A Call for More Parental/Care-Givers' Education: A Case Report

Aliyu J. Daniel¹, Abubakar Umar², Solomon J. Hassan^{1*}, Yikawe S. Stephen¹, Ray Bayo², Solomon Ukwuani²

¹Department of Otorhinolaryngology, Usmanu Danfodiyo University Teaching Hospital, Sokoto, Nigeria

²Cardiothoracic Surgery Unit, Department of Surgery Usmanu Danfodiyo University Teaching Hospital, Sokoto, Nigeria

Email: *maleshesh@yahoo.com

Received 26 April 2015; accepted 5 July 2015; published 8 July 2015

Copyright © 2015 by authors and Scientific Research Publishing Inc.

This work is licensed under the Creative Commons Attribution International License (CC BY).

<http://creativecommons.org/licenses/by/4.0/>



Open Access

Abstract

Introduction: Foreign body (FB) aspiration is a common cause of respiratory emergency in early childhood. Parents and care-givers are usually unaware of initial time of FB aspiration, and the varied symptoms may be confusing to them. Therefore, education on ways of avoiding the incidence is paramount, and prompt hospital presentation will reduce morbidity and mortality. **Case Report:** A 5 cm concrete nail, which was aspirated by a 2-year-old male Nigerian child of the Hausa ethnic group, was successfully removed by rigid bronchoscopy. We emphasize the need for more parental/care-givers' education on foreign body aspiration among children. **Conclusion:** Infants commonly play with objects by inserting them in various orifices of their body. This, therefore, predisposes them to aspiration, which will go unnoticed at the time of aspiration. There is a need for repeated parental/care-givers' education on dangers of allowing children to play alone. Parents/care-givers should be conversant with varied presentations of FB aspiration in children, as this will reduce the morbidity and mortality to the minimum.

Keywords

Foreign Body, Airway, Aspiration, Parental Education

*Corresponding author.

1. Introduction

Foreign body (FB) aspiration is a common incident in infants and young children and can be life threatening. Young children, with their inquisitive nature, often want to take everything in their mouths without having premolars and molars to grind food effectively. Moreover, with an immature cough reflex, morbidity, and mortality are higher in children. Delayed diagnosis of FBA can lead to serious problems for children, ranging from fatal airway obstruction to chronic wheezing, recurrent pneumonia or failure to thrive. This is a case report on a child who aspirated a 5 cm concrete nail. It is estimated that almost 600 children die annually in the United States following FB aspiration [1]-[5]. The peak age for FB aspiration is 2 - 3 years [2]. In Ibadan Nigeria, children under 12 years (81%) were most involved, of which 61.4% were under 5 years of age [6].

Different types of FB aspirated have been reported from the ordinary to the most bizarre, and geographic locations may differ in the types of FB seen. In the United States for instance, pea nuts are commonly aspirated by children, while watermelon and pumpkin seeds are common FB aspirated by children in Egypt and Greece respectively [7] [8]. In places where negligence is more by care-givers, children, even infants may be left alone to play with different kinds of objects like stones, toys, and more dangerous materials carelessly dropped on the floor by adults, as seen in this reported case who aspirated a concrete nail.

The symptoms and findings vary from an unaffected child in no apparent distress to impending airway failure. This will depend on the location, size and chronicity of the aspirated FB. Early presentation may include: sudden onset of choking, cough and shortness of breath. Other symptoms may be throat pain, stridor, dyspnoea, wheezing, hoarseness or fever. Many patients have only some or none of these signs and symptoms [1] [2] [4] [8] [9]. These early symptoms resolve when the mucosal cough receptors accommodate, and the patient may then be asymptomatic when evaluated. This may delay the diagnosis of a partial obstruction for weeks to months [9]. Retrieval of aspirated FB is essential due to the risk of asphyxia, atelectasis or bronchiectasis, granulation tissue, recurrent pneumonia and death [1] [8].

Better still, prevention is best achieved at the primary level where care-givers are more educated on the need to be more vigilant as they bring up children, knowing the dangers of FB aspiration in children if left them alone to play with objects. In this report, the possibility of a bizarre FB aspiration in a child is made clear, and we emphasize the need for more parental/care-givers vigilance in child upbringing.

2. Case Report

A 2-year-old male Nigerian child of the Hausa ethnic group, who was brought to the accident and emergency unit of the Usmanu Danfodiyo University Teaching Hospital by his parents, two (2) days after he was said to have aspirated an unknown FB. Although he had violent cough and choking episodes that lasted few minutes, all symptoms subsided thereafter, but parents decided to bring him to the hospital to confirm the resolved symptoms. On presentation, patient was not in respiratory or painful distress, but chest examination findings revealed slight decreased air entry and some transmitted breath sounds on the right hemi thorax. No crepitations. A plain chest X-ray was done that revealed a long, about 5 cm radio-opaque object with a distal rounded cap and a proximal sharp end (nail), in the right main bronchus. **Figure 1** and **Figure 2** show the patient's plain chest X-ray, anterior-posterior (AP) and lateral views, respectively.

Patient was then referred to the Cardiothoracic unit of the same hospital, who later invited the Otorhinolaryngology unit for co-management. He was prepared and had rigid bronchoscopy with removal of a 5 cm concrete nail from his right main bronchus, in the main theatre. **Figure 3** shows the FB removed from the patient's right main bronchus.

Patient was given prophylactic intravenous antibiotics and hydrocortisone at induction of anaesthesia. He did very well post operatively and was discharged 48 hours after removal.

3. Discussion

Foreign body (FB) aspiration claims thousands of lives each year [10]. It is one of the leading accidental causes of death under three years of age [11] [12]. The peak incidence of inhaled FB is between the ages of one and three, with a male: female ratio of 2:1 [13] [14]. In the United States, over the last quarter century the incidence of FB aspiration has not changed significantly and is unlikely to do so as long as children continue to put objects in their mouths to explore their surroundings. There has been a dramatic decrease in childhood deaths from

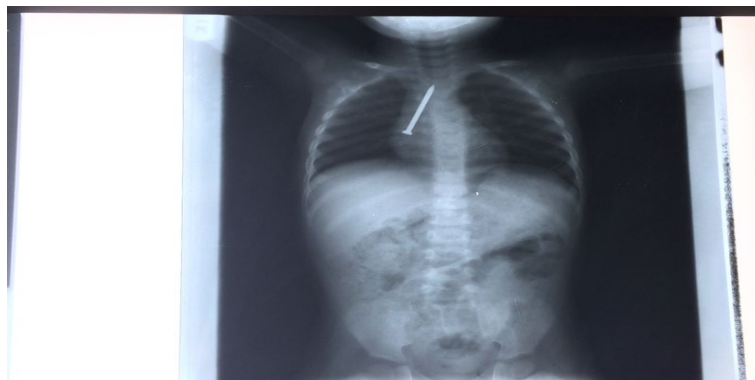


Figure 1. Plain chest X-ray of the patient AP view.

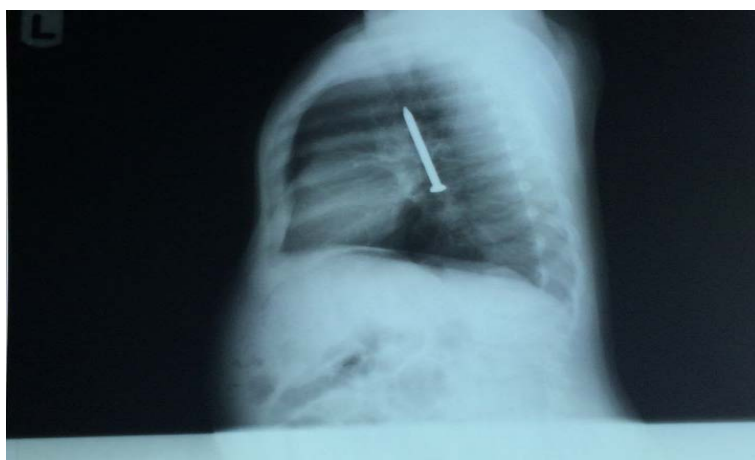


Figure 2. Plain chest X-ray of the patient lateral view.



Figure 3. Concrete nail removed from patient's right main bronchus.

asphyxiation by ingested objects; accounting for approximately 3000 deaths per year [15]. The associated morbidity in survivors of prolonged asphyxiation is considerable.

The most common age group affected being toddlers between 2 and 4 years of age. Case series from the last decade reflect that children younger than 5 years account for approximately 84% of cases, and children younger than 3 years account for 73% [16]. The high incidence in this age group reflects the oral tendency of these children, and, in addition, children this age do not have a full posterior dentition or mature neuromuscular mechanisms for appropriate swallowing and airway protection. Boys are affected more frequently than girls in a ratio of approximately 2:1. The acute episode is heralded by gagging and choking and is quite obvious. Because toddlers may be out of parents' view during the acute episode, the period of acute distress may not be witnessed by an adult, making it more difficult to be sure of the diagnosis. As the FB goes down the tracheobronchial axis, the active distress subsides. When the FB lands in its final resting place, the symptoms may vary in severity de-

pending on the object's size, the degree of obstruction, and surrounding tissue reactions.

Up to 50% of patients with FB aspirations do not have a contributing history available. When a patient is seen with nonspecific pulmonary complaints such as intermittent coughing or wheezing, the differential diagnosis is long. Without a high degree of suspicion of FB aspiration, physicians may proceed with allergy testing, initiation of asthma therapy, or treatment for various infections or search for a yet more exotic diagnosis while overlooking one of the most common etiologies. It is not uncommon for a patient to be treated for several months, including repeated hospitalizations for various erroneous ailments, before proceeding with bronchoscopy to establish a correct diagnosis and the removal of a retained FB. Therefore, any patient with a prolonged nonspecific pulmonary complaint, even without the history of acute aspiration, should raise the question of a retained FB.

The classic presentation was seen in our patient who initially had violent cough and choking that lasted only few minutes, after which he became asymptomatic. With this form of presentation, many care-givers can ignore the child during the second (asymptomatic) phase, when they would assume the FB was expelled or not even aspirated in the first place. This was not the case with our patient as the parents had to bring him to the hospital despite "complete resolution of symptoms". There is therefore need for parents to be more careful and seek for medical care whenever their child develops sudden cough and choking while eating or playing, even if when no object was seen with the child earlier. If there is total glottis obstruction by a FB, especially large food bolus, the patient will be aphasic with total upper airway obstruction which can lead to asphyxiation and even death at the spot. In such case, the parents/care-givers need to be conversant with some basic life support measures like the Heimlich manoeuvre. In infants, it entails placing the patient face down across the care-giver's forearm, supporting his/her head with your hand before giving four forceful blows to the back with the heel of your hand. This may have to be repeated several times to expel the FB.

Because of the carefree attitudes or ignorance of most care-givers, it is not surprising that a review by Cohen *et al.* [17] of 143 cases of FB aspirations in children indicated that only 41% were seen by a physician on the first day after the initial episode. Reilly *et al.* [18] noted that 85% of pediatric aerodigestive FB injuries were diagnosed on the first physician visit and that FB aspirations were seven times more likely to have a delay in diagnosis than FB ingestions.

Though it may be difficult to bring the incidence of FB aspiration in children to zero, we can achieve a good decrease if parents/care-givers are repeatedly educated on the dangers of dropping potential foreign bodies where children can reach them. The longer the duration before presentation to the health center, the more the complications from a FB aspiration. Therefore parents should understand the benefits of seeking medical care on the suspicion of FB aspiration by a child.

4. Conclusion

There is a need for repeated education of parents/care-givers on the dangers of allowing children to play alone. Parents/care-givers should be conversant with varied presentations of FB aspiration in children, as this will reduce the morbidity and mortality to the minimum.

Competing Interest

None.

Authors' Contribution

ADJ: Conceptualize and designed the study; AU: Critical review of the manuscript; SJH: Design and drafting of the manuscript; YSS: Contributed in manuscript drafting; RB: Contributed in manuscript drafting; SU: Contributed in manuscript drafting.

References

- [1] Zur, K.B. and Litman, R.S. (2009) Pediatric Airway Foreign Body Retrieval: Surgical and Anesthetic Perspectives. *Pediatric Anesthesia*, **19**, 109-117. <http://dx.doi.org/10.1111/j.1460-9592.2009.03006.x>
- [2] Saki, N., Nikakhlagh, S., Rahim, F. and Abshirini, H. (2009) Foreign Body Aspiration in Infancy: A 20-Year Experience. *International Journal of Medical Sciences*, **6**, 322-328. <http://dx.doi.org/10.7150/ijms.6.322>
- [3] Chik, K.K., Miu, T.Y. and Chan, C.W. (2009) Foreign Body Aspiration in Hong Kong Chinese Children. *Hong Kong*

Medical Journal, **15**, 6-11.

- [4] Wang, K., Harnden, A. and Thomson, A. (2010) Easily Missed? Foreign Body Inhalation in Children. *BMJ*, **341**, c3924. <http://dx.doi.org/10.1111/j.1749-4486.2010.02210.x>
- [5] Cutrone, C., Pedruzzi, B., Tava, G., Emanuelli, E., Barion, U., Fischetto, D., et al. (2011) The Complimentary Role of Diagnostic and Therapeutic Endoscopy in Foreign Body Aspiration in Children. *International Journal of Pediatric Otorhinolaryngology*, **75**, 1481-1485. <http://dx.doi.org/10.1016/j.ijporl.2011.08.014>
- [6] Adegboye, V.O. and Adebo, O.A. (2001) Epidemiology of Tracheobronchial Foreign Bodies in Ibadan. *Nigerian Journal of Clinical Practice*, **4**, 51-53.
- [7] Daniilidis, J., Symeonidis, B., Triaridis, K. and Kouloulas, A. (1977) Foreign Body in the Airways: A Review of 90 Cases. *Archives of Otolaryngology—Head and Neck Surgery*, **103**, 570. <http://dx.doi.org/10.1001/archotol.1977.00780270038002>
- [8] Gaafar, H., Abdel-Dayem, M., Talaat, M. and Mandour, M. (1982) The Value of X-Ray Examination in the Diagnosis of Tracheobronchial Foreign Bodies in Infants and Children. *ORL Journal for Oto-Rhino-Laryngology and Its Related Specialties*, **44**, 340. <http://dx.doi.org/10.1159/000275614>
- [9] Paksu, S., Paksu, M.S., Kilic, M., Guner, S.N., Baysal, K., Sancak, R. and Ozturk, F. (2012) Foreign Body Aspiration in Childhood. Evaluation of Diagnostic Parameters. *Pediatric Emergency Care*, **28**, 259-264. <http://dx.doi.org/10.1097/PEC.0b013e3182494eb6>
- [10] Geetanjali, S. (2010) Airway Foreign Bodies in Children. *Elsevier*, **11**, 67-71.
- [11] Black, R.E., Choi, K.J., Syme, W.C., Johnson, D.G. and Matlak, M.E. (1984) Bronchoscopic Removal of Aspirated Foreign Bodies in Children. *American Journal of Surgery*, **148**, 778-781. [http://dx.doi.org/10.1016/0002-9610\(84\)90436-7](http://dx.doi.org/10.1016/0002-9610(84)90436-7)
- [12] Gibson, S.E. (1999) Aerodigestive Tract Foreign Bodies. *Practical Pediatric Otolaryngology*, 34-562.
- [13] Rovin, J.D. and Rodger, M.B. (2000) Pediatric Foreign Body Aspiration. *Pediatric Review*, **21**, 86-90. <http://dx.doi.org/10.1542/pir.21-3-86>
- [14] Andazola, J.J. and Sapien, R.E. (1999) The Choking Child: What Happens before the Ambulance Arrives? *Prehospital Emergency Care*, **3**, 7-10. <http://dx.doi.org/10.1080/10903129908958897>
- [15] Burton, E.M., Brick, W.G., Hall, J.D., Riggs Jr., W. and Houston, C.S. (1996) Tracheobronchial Foreign Body Aspiration in Children. *Southern Medical Journal*, **89**, 195-198. <http://dx.doi.org/10.1097/00007611-199602000-00007>
- [16] Kramer, T.A., Riding, K.H. and Salkeld, L.J. (1986) Tracheobronchial and Esophageal Foreign Body in the Pediatric Population. *Journal of Otolaryngology*, **15**, 355-358.
- [17] Darrin, D.H. and Holinger, L.D. (1995) Foreign Body of the Larynx, Trachea and Bronchi. In: Bluestone, C.D., Stool, S. and Kenna, M.A., Eds., *Paediatric Otolaryngology*, 3rd Edition, WB Saunders, Philadelphia, 1390.
- [18] Cohen, S.R., Herbert, W.I., Lewis Jr., G.B. and Geller, K.A. (1980) Foreign Body in the Airway, Five-Year Retrospective Study with Special Reference to Management. *Annals of Otolaryngology, Rhinology Laryngology*, **89**, 437-442. <http://dx.doi.org/10.1177/000348948008900513>