

Massive Thromboembolism from an Abdominal Aortic Aneurysm after Successful Thrombolysis for an Acute Myocardial Infarction

Fernando Luiz de Melo Bernardi¹, Paulo Cury Rezende¹, Cibele Larrosa Garzillo¹, Eduardo Gomes Lima¹, Diogo Arantes Behling Pereira da Luz¹, Vera Demarchi Aiello², Whady Hueb^{1*}

¹Department of Atherosclerosis, Heart Institute of the University of Sao Paulo, Sao Paulo, Brazil

²Department of Pathology, Heart Institute of the University of Sao Paulo, Sao Paulo, Brazil

Email: *whady.hueb@incor.usp.br

Received 15 January 2015; accepted 28 January 2015; published 2 February 2015

Copyright © 2015 by authors and Scientific Research Publishing Inc.

This work is licensed under the Creative Commons Attribution International License (CC BY).

<http://creativecommons.org/licenses/by/4.0/>



Open Access

Abstract

Thrombolytic therapy is indicated to the treatment of patients with ST-elevation myocardial infarction or pulmonary embolism. Its indication should especially consider the risk of bleeding, but other complications might pose harm to patients. Although rarely reported, fibrinolysis can trigger thromboembolic phenomena from emboligenic sources such as aortic aneurysms. Clinicians should be aware of this life-threatening complication. In this case report, we present one patient admitted due to a ST-segment elevation acute myocardial infarction successfully treated with fibrinolytic treatment, but who evolved with a massive microembolism from an abdominal aortic aneurysm. Despite intensive medical care, the patient evolved with multiorgan failure due to distal microembolism to the guts and lower limbs, severe rhabdomyolysis and ultimately to death. In this challenging case, clinical, anatomical and histopathologic features are presented and discussed.

Keywords

Thromboembolism, Abdominal Aortic Aneurysm, Fibrinolysis, Myocardial Infarction

*Corresponding author.

1. Introduction

Thromboembolic phenomenon from aortic aneurysms in the setting of thrombolytic therapy for acute occlusive vascular syndromes is a rare but severe event. The mortality in such cases is comparable with aortic rupture [1]. Thus, clinicians should be aware that vascular aneurysms, like aortic aneurysms, are potential sites of embolic showers and should be thought and carefully considered in patients with vascular diseases especially before fibrinolytic treatment is accomplished. In such cases, the identification of the source of the embolization and the definition of the characteristics of the emboli are central to the best treatment option that should be applied in order to add survival chances in this life-threatening complication.

2. Case Report

A 67-year-old male patient with no previous history of cardiovascular disease was admitted to the emergency room of a secondary hospital with a history of 4 hours of chest pain. Diagnosis of an infero-posterior ST-elevation myocardial infarction (STEMI) was done. Immediate pharmacologic thrombolysis with streptokinase was performed and clinical and electrocardiographic reperfusion criteria were achieved. However, the patient developed two episodes of ventricular fibrillation, which were immediately resolved with electrical cardioversion and controlled with amiodarone infusion. Due to the electrical instability, he was transferred to a tertiary cardiologic center. Upon admission, the patient still met reperfusion criteria, with no chest pain. However, he started complaining of pain on both legs and feet. Physical examination showed pale and cold feet with bilateral peripheral pulses present. The pain on his lower limbs worsened needing continuous morphine infusion and his abdomen started to distend. Due to the signs of lower limbs ischemia, cardiac catheterization was deferred and a doppler ultrasonography of the limbs was performed. Diffuse atherosclerosis and decreased arterial blood flow were found, with no signs of gross obstructive lesions, suggesting an impairment of the microcirculation. Over the next hours the abdominal distention got worse and abdominal pain developed. Furthermore, laboratory exams showed rising levels of BUN and creatinine and very high levels of serum creatine phosphokinase (CPK 15,554 U/L), amylase (258 U/L) and aminotransferases (AST 2111 U/L; ALT 1621 U/L). The patient was transferred to an intensive care unit. He evolved with acute renal failure and severe lactic metabolic acidosis. Hemodialysis therapy was started. Transesophageal echocardiography revealed an ejection fraction of 55% with akinesia of the inferior wall and no signs of aortic dissection or intraventricular thrombus. Abdominal ultrasonography revealed a large abdominal aortic aneurysm (8.5×7.5 cm in diameter and 16.0 cm of extension) with a high burden of thrombus. Lactic acidosis continued to worsen and CPK levels reached 35,230 U/L. After the second day, despite intensive medical care, multiple organ failure developed and the patient died. On necropsy, a large abdominal aortic aneurysm (AAA) was found (Figure 1 and Figure 2) filled with a big, friable, and mobile thrombus. Signs of systemic microembolization and diffuse mesenteric, hepatic, kidney and skeletal muscle ischemia were also observed (Figure 3).

3. Discussion

In this case report, we present a catastrophic thromboembolic event from an AAA triggered by thrombolytic therapy in a patient with acute STEMI. Unlike the hemorrhagic complications of thrombolytic therapy, this patient developed a fatal embolic complication with the definitive diagnosis confirmed by histopathology. Of note, in the literature, most of the few cases similar to the present one had only presumptive diagnosis [1].

Thromboembolism from an AAA is a serious clinical manifestation of this disease. It is the first manifestation of an AAA in 5% of patients [1]. Mortality in these cases is comparable with rupture [1]. Series of reports describe mortality higher than 70% in patients with embolic events after thrombolysis [2].

Clinically, this patient presented signs of lower limbs ischemia few hours after fibrinolysis, but pulses were palpable. Interestingly, Wingo and colleagues have reported that only 15% of the patients had a pulse deficit in cases similar to the present one [2].

In this patient, systemic inflammation following acute myocardial infarction [3]-[5] associated with the lysis of the thrombus laid on the surface of the aneurysm by thrombolytic treatment acted synergistically, leading to the disruption of a chronic thrombus and to distal and massive embolization.

Both AAA and atherosclerotic plaques of the aorta are manifestations of systemic atherosclerosis, and are common in the elderly and in patients with coronary artery disease [6]. Main risk factors for thromboembolic

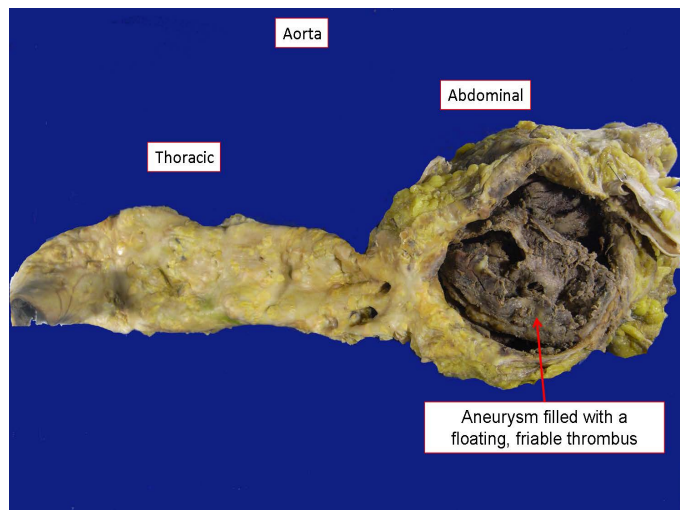


Figure 1. Opened aorta showing diffuse atherosclerosis and a huge abdominal aneurysm filled with a friable thrombus.

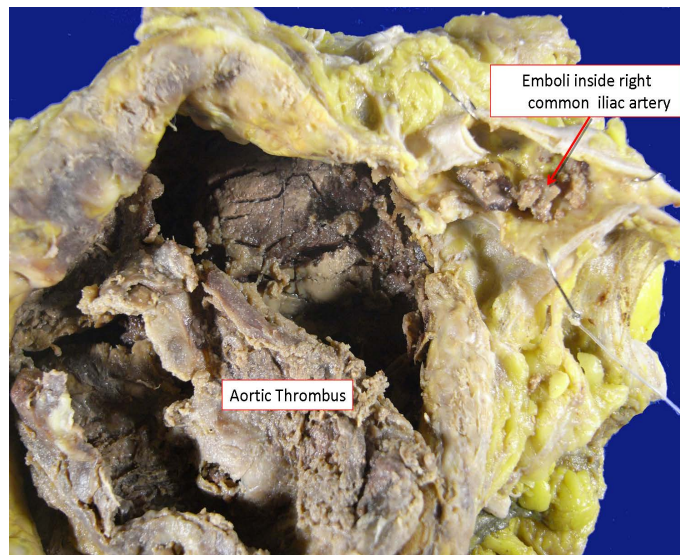


Figure 2. Detail of the thrombus filling the aneurism with emboli inside the common iliac artery.

events include the thickness of the plaque, the presence of thrombus and/or ulceration, plaque mobility and cardiovascular procedures [1]. Although thromboembolic phenomena from an AAA are rarely reported, it's frequently described that fibrinolytic and anticoagulant therapy might provoke atheroembolism (embolism of cholesterol) [7].

The indication for fibrinolytic treatment in an attempt to open the occluded coronary artery frequently underestimates systemic complications. Furthermore, the emergency condition of an acute coronary syndrome restricts an investigation of risk factors for complications, before the indication of the thrombolytic procedure. So, the benefit of an early thrombolysis for an acute myocardial infarction should balance the risks of possible complications related to treatment. In patients with aortic aneurism or other emboligenic sources, the choice of treatment should be carefully considered.

Due to unavailability of primary percutaneous coronary intervention (PCI) at the first hospital, thrombolysis was indicated and accomplished its initial target. The patient didn't have any contra-indications for thrombolysis. He had a large AAA unknown so far, but even if he had this diagnosis previously, this would not be a formal contra-indication for thrombolytic therapy.

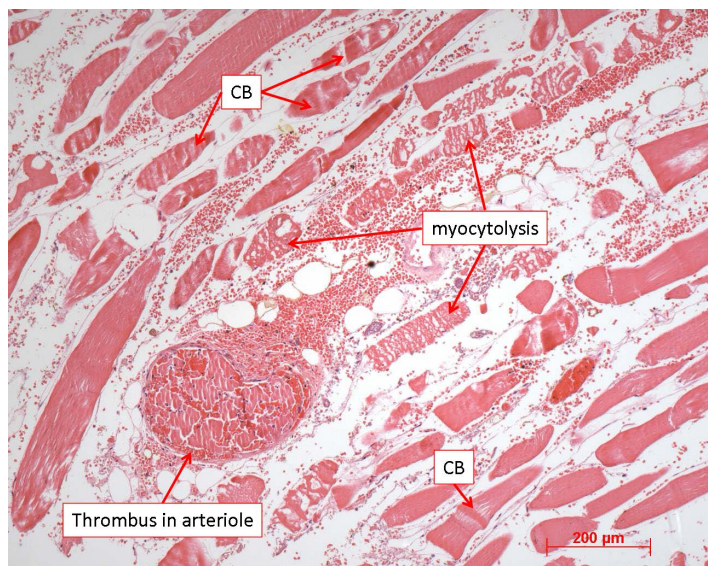


Figure 3. Photomicrography of skeletal muscle from the right inferior limbs showing recent necrosis, myocytolysis and contraction bands (CB). An arteriole is seen at the left inferior corner, completely occluded by a thromboembolus. Hematoxylin-eosin staining, objective magnification = 10×.

If thromboembolism occurs in great arteries, surgical or percutaneous embolectomy procedures may be effective treatments [8] [9]. However, in the present case, treatment of microembolic showers is less effective and is based on the use of heparin sodium, intensive support and treatment of end-organ dysfunction. The use of high-dose heparin is indicated due to its potential to reduce tissue damage [10], as it may improve collateral flow and decrease permeability changes [11]-[13]. Moreover, heparin may suppress tissue plasminogen activator and matrix metalloproteinase production [14]. These two substances can contribute to plaque instability.

In summary, aortic aneurysms and emboligenic sources must be considered in patients with clinical indications for thrombolytic therapy.

4. Conclusion

Besides bleeding complications, the indication of thrombolytic therapy should take into account factors related to embolic complications, like aortic aneurysms. These aneurysms should always be concerned in patients with vascular disease, especially during fibrinolytic treatment.

Acknowledgements

We would like to thank all the members of MASS research group for putting together all the forces to publish this paper.

Funding

This work was supported by Zerbini Foundation.

References

- [1] Baxter, B.T., McGee, G.S., Flinn, W.R., *et al.* (1990) Distal Embolization as a Presenting Symptom of Aortic Aneurysms. *American Journal of Surgery*, **160**, 197-201. [http://dx.doi.org/10.1016/S0002-9610\(05\)80306-X](http://dx.doi.org/10.1016/S0002-9610(05)80306-X)
- [2] Wingo, J.P., Nix, M.L., Greenfield, L.J., *et al.* (1986) The Blue Toe Syndrome: Hemodynamics and Therapeutic Correlates of Outcome. *Journal of Vascular Surgery*, **3**, 475-480. [http://dx.doi.org/10.1016/0741-5214\(86\)90111-4](http://dx.doi.org/10.1016/0741-5214(86)90111-4)
- [3] Herskowitz, A., Choi, S., Ansari, A.A., *et al.* (1995) Cytokine mRNA Expression in Postischemic/Reperfused Myocardium. *American Journal of Pathology*, **146**, 419-428.

-
- [4] Pannitteri, G., Marino, B., Campa, P.P., *et al.* (1997) Interleukins 6 and 8 as Mediators of Acute Phase Response in Acute Myocardial Infarction. *American Journal of Cardiology*, **80**, 622-625. [http://dx.doi.org/10.1016/S0002-9149\(97\)00434-7](http://dx.doi.org/10.1016/S0002-9149(97)00434-7)
- [5] Koten, K., Hirohata, S., Miyoshi, T., *et al.* (2008) Serum Interferon-Gamma-Inducible Protein 10 Level Was Increased in Myocardial Infarction Patients, and Negatively Correlated with Infarct Size. *Clinical Biochemistry*, **41**, 30-37. <http://dx.doi.org/10.1016/j.clinbiochem.2007.10.001>
- [6] Tunick, P.A. and Kronzon, I. (2000) Atheromas of the Thoracic Aorta: Clinical and Therapeutic Update. *Journal of the American College of Cardiology*, **35**, 545. [http://dx.doi.org/10.1016/S0735-1097\(99\)00604-X](http://dx.doi.org/10.1016/S0735-1097(99)00604-X)
- [7] Hitti, W.A., Wali, R.K., Weinman, E.J., *et al.* (2008) Cholesterol Embolization Syndrome Induced by Thrombolytic Therapy. *American Journal of Cardiovascular Drugs*, **8**, 27. <http://dx.doi.org/10.2165/00129784-200808010-00004>
- [8] Matchett, W.J., McFarland, D.R., Eidt, J.F., *et al.* (2000) Blue Toe Syndrome: Treatment with Intra-Arterial Stents and Review of Therapies. *Journal of Vascular and Interventional Radiology*, **11**, 585-592. [http://dx.doi.org/10.1016/S1051-0443\(07\)61610-8](http://dx.doi.org/10.1016/S1051-0443(07)61610-8)
- [9] Wissgott, C., Kamusella, P. and Andresen, R. (2011) Percutaneous Mechanical Thrombectomy: Advantages and Limitations. *Journal of Cardiovascular Surgery*, **52**, 477-484.
- [10] Chauvapun, J.P. and Dryjski, M. (2005) Distal Peripheral Microembolism. *Vascular*, **13**, 50-57. <http://dx.doi.org/10.1258/rsmvasc.13.1.50>
- [11] Blaisdell, F.W., Steele, M. and Allen, R.E. (1978) Management of Acute Lower Extremity Arterial Ischemia Due to Embolism and Thrombosis. *Surgery*, **84**, 822-834.
- [12] Wright, J.G., Kerr, J.C., Valeri, C.R., *et al.* (1988) Heparin Decreases Ischemia-Reperfusion Injury in Isolated Canine Gracilis Model. *Archives of Surgery*, **123**, 470-472. <http://dx.doi.org/10.1001/archsurg.1988.01400280080014>
- [13] Becker, M., Menger, M.D. and Lehr, H.Á. (1994) Heparin-Released Superoxide Dismutase Inhibits Postischemic Leukocyte Adhesion to Venular Endothelium. *American Journal of Physiology*, **267**, H925-H930.
- [14] Clowes, A.W., Clowes, M.M., Kirkman, T.R., *et al.* (1992) Heparin Inhibits the Expression of Tissue-Type Plasminogen Activator by Smooth Muscle Cells in Injured Rat Carotid Artery. *Circulation Research*, **70**, 1128-1136. <http://dx.doi.org/10.1161/01.RES.70.6.1128>