

***Strongyloides stercoralis* in an immunocompetent adult: An unexpected cause of weight lost**

Lia Marques^{1*}, André Rodrigues¹, Elisa Vedes², Dores Marques¹

¹Serviço de Medicina III, Hospital de Pulido Valente, Centro Hospitalar Lisboa Norte, Lisboa;

*Corresponding Author: marques.lia@gmail.com

²Unidade de Cuidados Intensivos do Hospital da Luz, Lisboa

Received ***** 2013

Copyright © 2013 Lia Marques *et al.* This is an open access article distributed under the Creative Commons Attribution License, which permits unrestricted use, distribution, and reproduction in any medium, provided the original work is properly cited.

ABSTRACT

***Strongyloides stercoralis* infects at least 100 million humans worldwide each year, but its prevalence is underestimated. It is endemic in hot and humid climates as well as resource poor countries with inadequate sanitary conditions. The rise of international travel and immigration has a positive impact in strongyloidiasis. Due to its unique auto infection life-cycle, *Strongyloides* may lead to chronic infections remaining undetected for decades. Strongyloidiasis is most often asymptomatic but it has a wide range of clinical presentations. The two most severe forms of strongyloidiasis are hyperinfection and disseminated syndromes. These occur most often in patients with impaired cell mediated immunity. A 42-year-old immunocompetent man presented with chronic watery diarrhea, malaise, upper abdominal pain, anorexia and weight lost. *Strongyloides stercoralis* was identified in stool samples and duodenal biopsy. The patient was successfully treated with albendazole. The authors report a case of strongyloidiasis hyperinfection in an immunocompetent host 20 years away from an endemic area and make a literature review.**

Keywords: *Strongyloides stercoralis*;
Immunocompetent; Hyperinfection

1. INTRODUCTION

Strongyloides stercoralis (*S. stercoralis*) is an intestinal nematode endemic in tropical and subtropical countries and in the Southeastern United States [1-5]. The helminth is also present in some restricted areas of the European Union such as northern Italy, rural Romania or

southeastern Spain [4]. *S. stercoralis* affects 30 - 100 million people worldwide [4,6,7], but this current estimate dates back to review articles published between 1989 and 1996 [2,8]. Recent publications state that strongyloidiasis remains an underestimated public health problem [1,4,9, 10]. A 10-year multicenter surveillance program performed in Spain and published in 2013, highlights the high prevalence of *S. stercoralis* cases imported by immigrants, most being asymptomatic and with eosinophilia [4].

Strongyloidiasis is caused by the female nematode *S. stercoralis*. Its life cycle is comprised of 2 parts: a free-living cycle outside of the host as rhabditiform larvae and a parasitic life cycle as infective filariform larvae [5, 11-14]. During the free-living cycle in the soil, *Strongyloides* transform from rhabditiform larvae into infective filariform larvae, which penetrate the human skin and proceed into the submucosa, then into the venous circulation, and then toward the right heart and lungs [5,11-14]. During the pulmonary maturation process, *Strongyloides* larvae induce alveolar capillary bleeding and potent eosinophilic inflammation, resulting in eosinophilic pneumonitis [5,11-14]. From the alveoli, the larvae migrate up the pulmonary tree and trachea, reaching the larynx, where they are swallowed and travel to the stomach and small bowel [5,11,13]. Inside the GI tract, *Strongyloides* larvae mature into adult female worms that embed themselves in the mucosa of the small bowel and produce eggs via parthenogenesis. Within the intestinal lumen, the eggs hatch into non infective rhabditiform larvae, which are excreted, along with stool, into the environment [5,11]. Some larvae, however, re-enter the blood stream through the bowel wall and migrate through lungs, it reenters the host via enteral circulation (endo-autoinfection) or perianal skin (exoautoinfection) by-passing the soil cycle [1,4,5,11-14]. Thus, parasites can remain in the human body for the remainder of the host's

life. This ability for auto infection implies that infestation can be life-long and extremely heavy [1,4,5,15].

Strongyloidiasis is generally benign and asymptomatic, eosinophilia and larvae in stool may be the only indicators of infection, but eosinophilia is not obligatory [1,5, 16]. In immunocompromised host, it can cause substantial intestinal disease and can disseminate widely to extra-intestinal sites, this clinical form of the infection being called hyperinfection syndrome [1,4,5]. Hyperinfection means accelerated auto infection characterized by development or enhanced GI and pulmonary symptoms with increased numbers of larvae seen in stool or sputum, restricted to the organ of auto infective cycle [1,5]. Typically, hyperinfection syndrome occurs in patients from endemic areas of *S. stercoralis* who receive immunosuppressive therapy. The diagnosis in such patients may be difficult because of a lower incidence of eosinophilia. Disseminated disease is defined by the presence of parasites outside of the traditional life cycle (*i.e.*, in organs other than the skin, GI tract, or lungs) [1,5,15-19]. Involvement of brain, heart, gall bladder, and kidney has been reported [1,6]. Although hyperinfection syndrome can occur in any host, disseminated disease occurs mainly in immunocompromised individuals [5,14,18].

In immunocompetent hosts, *Strongyloides* typically cause a low-grade chronic infection, which has been seen even up to 40 years after exposure [1,19]. Most patients are completely asymptomatic. Some have mild gastrointestinal, cutaneous, or pulmonary symptoms with or without fever. These symptoms may be acute or they may wax and wane chronically before spontaneous resolution. Gastrointestinal presentations include diarrhea and abdominal discomfort, nausea, anorexia, weight loss caused by gastritis, or enteritis with ulceration. Patients also can have occult gastrointestinal blood loss or fat and vitamin B12 malabsorption [20]. Pulmonary symptoms include cough and dyspnea, sometimes associated with wheezing, caused by larval migration through the lungs, or eosinophilic pneumonia [20]. The pathognomonic rash of *Strongyloides* infection is larva *currens* that likely represents an allergic response to migrating larvae [20].

The clinical presentation of hyperinfection syndrome is similar to that of classic strongyloidiasis [5]. However, due to increased parasite turnaround and dissemination, patients with hyperinfection syndrome and disseminated disease often have catastrophic clinical manifestations such as shock, disseminated intravascular coagulation, meningitis, renal failure, and/or respiratory failure [5,12]. Mortality with hyperinfection can be up to 87% in the immunosuppressed patients [20].

The diagnosis of *S. stercoralis* is often delayed due to the presence of sub clinical or poorly symptomatic cases, the usually low parasite load and irregular larvae output and the lack of a gold standard diagnostic test [4]. Diag-

nosis is based on detection of larvae in the stool or sputum. The sensitivity of a single examination is only 25 to 30%, but increases to 70% to 85% with three consecutive stool samples using the agar plate method of larval detection [5,20-23]. Detection of larvae in the duodenal aspirates is more sensitive and hence should be considered when there is a clinical suspicion of hyperinfection [24]. In the past years serological and immunological stool tests have been developed in order to improve diagnostic sensibility in immunocompromised and post transplant patients [24-26]. *S. stercoralis* serological assays can simplify the diagnosis and overcome the poor sensitivity of single stool exams, but its specificity is less well defined [27]. Problems of cross-reactivity seem to arise especially in areas where other nematodes are also endemic. New and promising tools such as serological methods based on recombinant antigens or PCR are also available in some referral centers. However, the optimal diagnostic strategy, both for epidemiological surveys and for individual diagnosis and screening, has yet to be defined [28,29].

Strongyloides infection is treated with the aim to eradicate strongyloidiasis. In chronic infection, ivermectin (200 mg/kg orally, once daily) for 1 - 2 days or albendazole (400 mg orally, twice daily) for 7 days is sufficient. A number of randomized clinical trials have been carried out, showing that ivermectin is the drug of choice, and a single dose is highly effective (over 90%) [9,28,29]. However, drug efficacy may have been overestimated, as faecal-based methods alone have been used to assess cure in almost all studies. Multiple doses may be necessary to obtain the goal of eradication in a patient, and the current indications by World Health Organization refer to a schedule of two consecutive days as a possible alternative to the single dose [28].

In recent years there has been an increasing number of papers concerning strongyloidiasis in medical literature, mainly case reports in immunocompromised and post transplant patients, but also some reports of strongyloidiasis in immunocompetent patients and with atypical presentations [1,17,20]. The actuality of this re emerging infection justifies the present case report of strongyloidiasis in an immunocompetent otherwise healthy patient.

2. CASE REPORT

A 42-year-old man was admitted to our hospital with chief complaints of chronic diarrhea for the previous three months. He had a history of passing watery and foul smelling stool. He complained of upper abdominal pain, anorexia and weight lost (4 kilograms over three months). He was natural from Guinea Bissau, and had lived in Portugal for the past 20 years, during this time

he hadn't return Guinea Bissau. He had been recently medicated with proton pump inhibitor (omeprazole) after a normal upper endoscopy that was performed for upper abdominal pain in the previous month. From the past medical history only to point alcoholic habits of 46 g/ethanol/day. The patient denied other symptoms namely vomits or fever. He had no history of tick exposure, contact with sickness, or recent travel.

Physical examination revealed a weight of 59.6 kg (body mass index of 18 Kg/m²), dehydration, abdominal examination was notable for diffuse pain and tenderness. Anal exam was not possible due to painful anal fissure and systemic examination findings were normal. There was no lymphadenopathy, clubbing, skin lesions and/or pedal edema.

His laboratory investigations were as follows: Total leucocyte count: 13,050 × 10⁹/L with normal differential, reactive C protein mildly elevated (2.8 mg/dL), no thrombocytopenia and no anemia, mild renal impairment (urea 30.70 mmol/L; Creatinine 141.44 mmol/L), hyponatremia (127 mmol/L), hypokalemia (2.7 mmol/L). Chest roentogram (**Figure 1**) has shown left hilar opacity suggestive of lymph node enlargement. Abdomen ultrasound was normal.

During the hospital staying the patient remained apyretic, with liquid diarrhea (5 to 6 passages of liquid brown stools without blood or mucus). The investigations revealed: Serology for human immunodeficiency virus and acute hepatitis A, B, and C infection were negative, thyroid function was in the normal range, erythrocyte sedimentation rate 103 mm in 1 h. Stool fat content was in the normal range. Colonoscopy wasn't performed due to painful anal fissure.

The patient underwent upper endoscopy revealing mild esophagitis and duodenitis with nematodes most suggestive of *S. stercoralis* visualized within the crypts. To investigate consumptive symptoms and clarify the x-ray abnormality a computer tomography (CT) was performed and showed (**Figure 2**): pulmonary micro nodules the

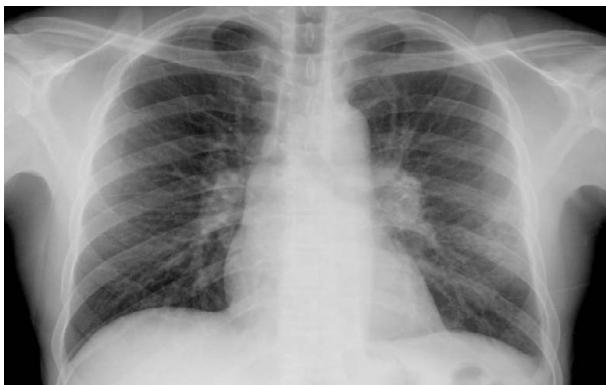

Figure 1. Chest roentogram—left hilar opacity suggestive of lymph node enlargement.

left inferior lobe and the right superior lobe suggesting inflammatory or infectious focus; lymph node enlargement in the left hilar area; intestinal distension without enlargement of abdominal lymph nodes. Bronchial Fibroscopy revealed generalized inflammatory signs. Bronchoalveolar lavage analysis was negative for mycobacterias, bacteria and neoplastic cells. Bacteriological and *mycobacterium* stool and blood analysis were negative. Serial stool samples were collected and subsequently revealed many *S. stercoralis* larvae. Treatment with oral albendazole (400 mg twice daily) was initiated and the patient completed a 7 day regime with good clinical and laboratory responses. Three months after hospital discharge the patient was reevaluated and remained asymptomatic, diarrhea subsided and he had a 10 Kilograms weight gain. Serial stool analysis was obtained and consistently negative for ova and parasites.

3. DISCUSSION

The presented case represents a *S. stercoralis* infection in an immunocompetent adult. In our patient, stool samples were positive possibly because of a high parasitic burden. The chest roentogram and CT findings may be attributed to the pulmonary phase of the parasite life circle. In fact, chest radiography can reveal diffuse alveolar or diffuse interstitial infiltrates, segmental alveolar infiltrates, or pleural effusions [20]. Endoscopic findings also support the diagnosis. The endoscopic manifestations of strongyloidiasis are broad, ranging from normal appearing mucosa to ulcerative and catarrhal duodenitis [5]. Patients with a clinical and histopathologic diagnosis of “idiopathic” eosinophilic gastroenteritis should also be thoroughly evaluated for *Strongyloides* because larvae may not always be apparent on initial evaluation, and therapy with corticosteroids may lead to fatal hyperin-

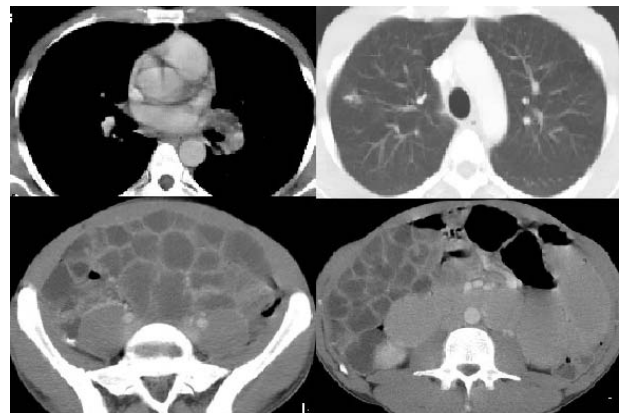


Figure 2. Computerized tomography imagery with pulmonary micro nodules the left inferior lobe and the right superior lobe suggesting inflammatory or infectious focus; lymph node enlargement in the left hilar area; intestinal distension without enlargement of abdominal lymph nodes.

fection if the diagnosis of strongyloidiasis is missed [5]. Thus, evaluation should include several stool examinations and upper endoscopy procedures with duodenal biopsies. Multiple biopsy specimens should be taken to increase the histopathologic yield, even if the duodenal mucosa does not manifest any major abnormalities [5].

In this patient there was no eosinophilia, but it is present in 50% to 80% of patients with mild infection. In contrast, a low eosinophil count occurs in patients with hyperinfection and disseminated disease [20,30], as seems to be the present case.

Low socioeconomic status, alcoholism, white race, and male gender have been associated with higher prevalence of *Strongyloides* stool positivity [31]. The patient had all of these factors and was original from an endemic region (Guinea Bissau) and was probably a chronic host for *S. stercoralis* acquired before his immigration to Portugal, 20 years earlier. It is postulated that the steady immigrant influx to the European Union has increased the number of infected carriers with *S. stercoralis* [4]. But presently there is no data on portuguese epidemiology for *S. stercoralis*, thus epidemiological studies are needed. To support this need there is widespread agreement in the scientific community that its prevalence is largely underestimated [1,10,19].

The clinical manifestation of hyperinfection syndrome varies widely and the onset may be acute or insidious. There is no quantitative definition, but it is characterized by an increase in gastrointestinal or pulmonary symptoms with an increased larval load in the stool or sputum. GI syndrome manifestations include watery diarrhea, weight loss, vomiting, and occasional bleeding. Usually symptoms of pulmonary strongyloidiasis include cough, dyspnea, wheezing, pulmonary hemorrhage, and pleural effusion [30]. A recent report was however able to identify through questionnaires and stool evaluations that individuals infected by *S. stercoralis* were more likely to complain of stomach ache [32,33]. This patient presented with an insidious form of disease, but his clinical manifestations fit the hyperinfection syndrome diagnosis.

Strongyloidiasis is commonly reported in immunocompromised patients; however, our patient was immunocompetent as his HIV status was negative, the history of alcoholism may have induced some immunosuppression contributing to susceptibility to hyperinfection. The patient responded well to albendazole therapy and there were no *Strongyloides* larvae in the stool when examined after therapy. That and his favorable clinical evolution all support the diagnosis.

The present patient was unusual in that he was otherwise healthy and immunocompetent who presented with pulmonary and gastrointestinal symptoms of strongyloidiasis hyperinfection syndrome. He had risk factors for strongyloidiasis: he was natural from an endemic area

and had heavy alcohol consumption. The authors highlight the importance of correctly diagnose and treat strongyloidiasis.

REFERENCES

- [1] Tiwari, S., Rautaraya, B. and Tripathy, K.P. (2012) Hyperinfection of *Strongyloides stercoralis* in an immunocompetent patient. *Tropical Parasitology*, **2**, 135-137. <http://dx.doi.org/10.4103/2229-5070.105182>
- [2] Genta, R.M. (1989) Global prevalence of strongyloidiasis: Critical review with epidemiologic insights into the prevention of disseminated disease. *Reviews of Infectious Diseases*, **11**, 755-767. <http://dx.doi.org/10.1093/clinids/11.5.755>
- [3] Gill, G.V., Welch, E., Bailey, J.W., Bell, D.R. and Beeching, N.J. (2004) Chronic *Strongyloides stercoralis* infection in former British Far East prisoners of war. *QJM*, **97**, 789-795. <http://dx.doi.org/10.1093/qjmed/hch133>
- [4] Valerio, L., Rourea, S., Fernández-Rivas, G., Basilec, L., Martínez-Cuevas, O., Ballesteros, Á.-L., *et al.* (2013) *Strongyloides stercoralis*, the hidden worm. Epidemiological and clinical characteristics of 70 cases diagnosed in the North Metropolitan Area of Barcelona, Spain, 2003-2012. *Transactions of the Royal Society of Tropical Medicine and Hygiene*, **107**, 465-470. <http://dx.doi.org/10.1093/trstmh/trt053>
- [5] Kassalik, M. and Mönkemüller, K. (2011) *Strongyloides stercoralis* hyperinfection syndrome and disseminated disease. *Gastroenterology & Hepatology*, **7**, 766-768.
- [6] CDC, DPDx (2009) Parasites and health: Strongyloidiasis. Centers for Disease Control & Prevention. <http://www.dpd.cdc.gov/dpdx/html/Strongyloidiasis.htm>
- [7] Grove, D.I. (1996) Human strongyloidiasis. *Advances in Parasitology*, **38**, 251-309. [http://dx.doi.org/10.1016/S0065-308X\(08\)60036-6](http://dx.doi.org/10.1016/S0065-308X(08)60036-6)
- [8] Jorgensen, T., Montresor, A. and Savioli, L. (1996) Effectively controlling strongyloidiasis. *Parasitology Today*, **12**, 164. [http://dx.doi.org/10.1016/0169-4758\(96\)80806-4](http://dx.doi.org/10.1016/0169-4758(96)80806-4)
- [9] Bisoffi, Z., Buonfrate, D., Montresor, A., Requena-Méndez, A., Muñoz, J., Krolewiecki, A.J., *et al.* (2013) *Strongyloides stercoralis*: A plea for action. *PLOS Neglected Tropical Diseases*, **7**, Article ID: e2214. <http://www.plosntds.org/article/info%3Adoi%2F10.1371%2Fjournal.pntd.0002214> <http://dx.doi.org/10.1371/journal.pntd.0002214>
- [10] Montes, M., Sawhney, C. and Barros, N. (2010) *Strongyloides stercoralis*: There but not seen. *Current Opinion in Infectious Diseases*, **23**, 500-504. <http://dx.doi.org/10.1097/QCO.0b013e32833df718>
- [11] Liu, L.X. and Weller, P.F. (1993) Strongyloidiasis and other intestinal nematode infections. *Infectious Disease Clinics of North America*, **7**, 655-682.
- [12] Roxby, A.C., Gottlieb, G.S. and Limaye, A.P. (2009) Strongyloidiasis in transplant patients. *Clinical Infectious Diseases*, **49**, 1411-1423. <http://dx.doi.org/10.1086/630201>

- [13] Thompson, B.F., Fry, L.C., Wells, C.D., *et al.* (2004) The spectrum of GI strongyloidiasis: An endoscopic-pathologic study. *Gastrointestinal Endoscopy*, **59**, 906-910. [http://dx.doi.org/10.1016/S0016-5107\(04\)00337-2](http://dx.doi.org/10.1016/S0016-5107(04)00337-2)
- [14] Marcos, L.A., Terashima, A., Dupont, H.L. and Gotuzzo, E. (2008) *Strongyloides* hyperinfection syndrome: An emerging global infectious disease. *Transactions of the Royal Society of Tropical Medicine and Hygiene*, **102**, 314-318. <http://dx.doi.org/10.1016/j.trstmh.2008.01.020>
- [15] Vigg, A., Mantri, S., Reddy, V.A. and Biyani, V. (2006) Acute respiratory distress syndrome due to *Strongyloides stercoralis* in non-Hodgkin's lymphoma. *Indian Journal of Chest Disease and Allied Science*, **48**, 67-69.
- [16] Azira, N.M. and Zeehaida, M. (2010) *Strongyloides stercoralis* hyperinfection in a diabetic patient: Case report. *Tropical Biomedicine*, **27**, 115-119.
- [17] Murali, A., Rajendiran, G., Ranganathan, K. and Shan-thakumari, S. (2010) Disseminated infection with *Strongyloides stercoralis* in a diabetic patient. *Indian Journal of Medical Microbiology*, **28**, 407-408. <http://dx.doi.org/10.4103/0255-0857.71854>
- [18] Ganesh, S. and Cruz Jr., R.J. (2011) Strongyloidiasis: A multifaceted disease. *Journal of Gastroenterology and Hepatology*, **7**, 194-196.
- [19] Gill, G.V. and Bell, D.R. (1979) *Strongyloides stercoralis* infection in former far east prisoners of war. *British Medical Journal*, **2**, 572-574. <http://dx.doi.org/10.1136/bmj.2.6190.572>
- [20] Neumann, I., Ritter, R. and Mounsey, A. (2012) Strongyloides as a cause of fever of unknown origin. *JABFM*, **25**, 390-393. <http://dx.doi.org/10.3122/jabfm.2012.03.110101>
- [21] Siddiqui, A.A. and Berk, S.L. (2001) Diagnosis of *Strongyloides stercoralis* infection. *Clinical Infectious Diseases*, **33**, 1040-1047. <http://dx.doi.org/10.1086/322707>
- [22] Segarra-Newnham, M. (2007) Manifestations, diagnosis, and treatment of *Strongyloides stercoralis* infection. *Annals of Pharmacotherapy*, **41**, 1992-2001. <http://dx.doi.org/10.1345/aph.1K302>
- [23] Dreyer, G., Fernandes-Silva, E., Alves, S., Rocha, A., Albuquerque, R., *et al.* (1996) Patterns of detection of *Strongyloides stercoralis* in stool specimens: Implications for diagnosis and clinical trials. *Journal of Clinical Microbiology*, **34**, 2569-2571.
- [24] Kishimoto, K., Hokama, A., Hirata, T., Ihama, Y., Nakamoto, M., Kinjo, N., *et al.* (2008) Endoscopic and histopathological study on the duodenum of *Strongyloides stercoralis* hyperinfection. *World Journal of Gastroenterology*, **4**, 1768-1773. <http://dx.doi.org/10.3748/wjg.14.1768>
- [25] Krolewiecki, A.J., Ramanathan, R., Fink, V., McAuliffe, I., Cajal, S.P., *et al.* (2010) Improved diagnosis of *Strongyloides stercoralis* using recombinant antigen-based serologies in a community-wide study in northern Argentina. *Clinical and Vaccine Immunology*, **17**, 1624-1630. <http://dx.doi.org/10.1128/CVI.00259-10>
- [26] Requena-Méndez, A., Chiodini, P., Bisoffi, Z., Buonfrate, D., Gotuzzo, E., *et al.* (2013) The laboratory diagnosis and follow up of strongyloidiasis: A systematic review. *PLOS Neglected Tropical Diseases*, **7**, Article ID: e2002. <http://www.plosntds.org/article/info%3Adoi%2F10.1371%2Fjournal.pntd.0002002>
- [27] Pitisuttithum, P., Supanaranond, W. and Chindanond, D. (1995) A randomized comparative study of albendazole and thiabendazole in chronic Strongyloidiasis. *The Southeast Asian Journal of Tropical Medicine and Public Health*, **26**, 735-738.
- [28] WHO (2008) WHO model formulary. http://whqlibdoc.who.int/publications/2009/9789241547659_eng.pdf
- [29] Marti, H., Haji, H.J., Savioli, L., Chwaya, H.M., Mgeni, A.F., *et al.* (1996) A comparative trial of a single-dose ivermectin versus three days of albendazole for treatment of *Strongyloides stercoralis* and other soil-transmitted helminth infections in children. *The American Journal of Tropical Medicine and Hygiene*, **55**, 477-481.
- [30] Romero-Cabello, R., Villagroy Gómez, J., Hernández González, M. and Romero Feregrino, R. (2012) Hyperinfection with *Strongyloides stercoralis*. *BMJ Case Reports*, 785-786.
- [31] Keiser, P.B. and Nutman, T.B. (2004) *Strongyloides stercoralis* in the immunocompromised population. *Clinical Microbiology Reviews*, **17**, 208-217. <http://dx.doi.org/10.1128/CMR.17.1.208-217.2004>
- [32] Krolewiecki, A.J., Lammie, P., Jacobson, J., Gabrielli, A.-F., Levecke, B., Socias, E., *et al.* (2013) A public health response against *Strongyloides stercoralis*: Time to look at soil-transmitted helminthiasis in full. *PLOS Neglected Tropical Diseases*, **7**, Article ID: e2165. <http://www.plosntds.org/article/info%3Adoi%2F10.1371%2Fjournal.pntd.0002165>
- [33] Becker, S.L., Sieto, B., Silue, K.D., Adjossan, L., Kone, S., *et al.* (2012) Diagnosis, clinical features, and self-reported morbidity of *Strongyloides stercoralis* and hookworm infection in a Co-endemic setting. *PLOS Neglected Tropical Diseases*, **5**, Article ID: e1292. <http://www.plosntds.org/article/info%3Adoi%2F10.1371%2Fjournal.pntd.0001292>