

# Laryngeal sarcoidosis—A case report\*

Hemanth Kowdley Subrahmanyam<sup>#</sup>, P. Gana, R. J. Lee

Department of ENT-Head & Neck Surgery, Kettering General Hospital, Kettering, UK; <sup>#</sup>Corresponding Author: [hks175@yahoo.co.uk](mailto:hks175@yahoo.co.uk)

Received 19 July 2013; revised 5 August 2013; accepted 12 August 2013

Copyright © 2013 Hemanth Kowdley Subrahmanyam *et al.* This is an open access article distributed under the Creative Commons Attribution License, which permits unrestricted use, distribution, and reproduction in any medium, provided the original work is properly cited.

## ABSTRACT

**Laryngeal sarcoidosis while involvement of the vocal cords in the disease process is exceptionally rare. Involvement of the larynx is frequently limited to the supraglottis that is rich in lympho epithelial tissue and usually presents with difficulty in breathing of varying severity. We present a rare case of isolated sarcoidosis involving the vocal cord in a patient with the previous history of cutaneous sarcoidosis.**

**Keywords:** Laryngeal Sarcoidosis

## 1. INTRODUCTION

Sarcoidosis is a chronic granulomatous disease involving in multiple organs in the body. Common sites of involvement include lungs, hilar & mediastinal lymph nodes, liver, eyes, skin, bone and the nervous system. Diagnosis is based on a correlation between the clinical, radiological and histological findings [1]. Supraglottic involvement is a very common finding in the larynx. True vocal cord involvement is a rarity. We present an interesting case report who presented to us with chronic cough as the only primary laryngeal symptom.

## 2. CASE REPORT

A 36-year-old female Caucasian smoker was referred by respiratory physicians with complaints of hoarseness for 8 months duration. She had received multiple courses of antibiotics for a presumed URTI with no effect on her hoarseness. There was no odynophagia or dysphagia. She had no loss of weight or appetite. No history of voice abuse was recorded. She was diagnosed with cutaneous sarcoidosis in 2002. Her co-morbidities included hay fever and Type II diabetes. Flexible nasolaryngoscopy revealed left vocal cord and ventricular band thickening. Her ACE level was elevated and CXR revealed bilateral

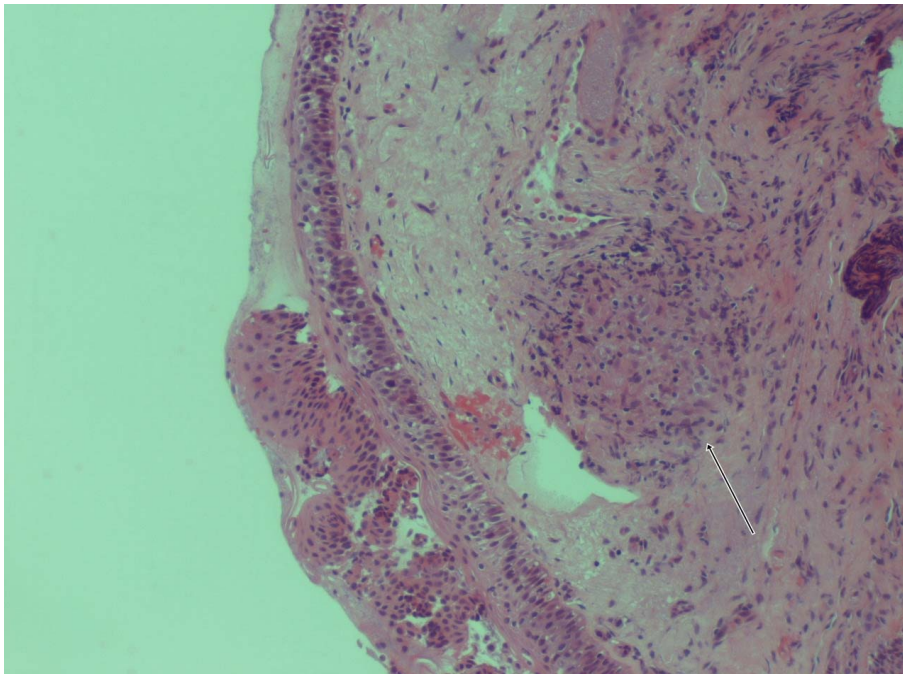
hilar lymph node enlargement signifying an active period of her systemic sarcoidosis. Microlaryngoscopy and biopsy suggested a narrow glottic area. Biopsy of the left vocal cord revealed features consistent with Sarcoidosis showing florid granulomatous inflammation alongside well formed epitheloid granulomas and occasional multinucleated giant cells (**Figure 1**). There was no evidence of caseous necrosis or malignancy. A diagnosis of laryngeal sarcoidosis was made. Treatment with inhalational and systemic corticosteroids significantly improved her condition. She has symptomatically remained stable and on regular follow up.

## 3. DISCUSSION

The first confirmed case of laryngeal sarcoidosis was by Poe in 1940 according to the literature [3]. Sarcoidosis is an idiopathic phenomenon characterised by non caseating granulomas. Prevalence does vary in the ethnic groups and is found to be 50 per 100,000 in Scandinavian countries and African Americans. It is a multi system disorder which typically affects population between 20 and 40 years of age. Laryngeal sarcoidosis prevalence is 0.5% to 8.3% in patients with a past history of sarcoidosis [1]. It affects the supraglottis typically with isolated evidence affecting the glottis. Interestingly it is theorized that sarcoidosis affects the reticuloendothelial system and hence vocal fold involvement is relatively uncommon due to lack of lymphoid tissue [1,4].

Common symptoms at presentation are hoarseness and stridor. Less commonly dysphagia, globus and cough could be presenting features. Disease does tend to fluctuate between active and latent periods [2] and therefore calls for prolonged period of follow up. In the supraglottis, epiglottis is the most common site of involvement though any part of larynx could be affected [4]. Hoarseness could be due to direct vocal fold involvement or as a result of peripheral neuropathy affecting the vocal folds and can usually be confirmed by laryngeal EMG [1]. Diagnosis is essentially established by histology demonstrating non caeseous granulomatous inflammation thus

\*Conflict of interest: Nil.



**Figure 1.** Well formed epithelioid granulomas with florid granulomatous inflammation and occasional multinucleated giant cells suggestive of sarcoidosis (arrow).

excluding other causes of granulomatous laryngitis [4]. The disease however, being multi-systemic in nature, ancillary screening tests such as chest X-ray, fbc, serum calcium levels, liver and renal function are necessary [1].

Treatment regimen includes systemic steroids, intraleSIONAL steroids for well localised lesions, laser resection, surgical excision, low dose radiation and tracheostomy. Recent literature has suggested an improvement with use of inhaled steroid and Clofazimine [4]. However treatment modality does depend on the degree and severity of symptoms.

#### 4. CONCLUSION

Sarcoidosis is found to affect mainly the reticuloendothelial system, thus in this case vocal cord involvement makes it a rare and interesting presentation. As this case and review of literature suggest that there is little evidence to forecast the prognosis due to paucity of reported cases and limited duration of follow-up. The role of combined modalities of treatment of laryngeal sarcoid re-

quires further objective assessment. In view of the propensity to relapse, a close and long term follow-up is essential.

#### REFERENCES

- [1] Schwartzbauer, H.R. and Tami, H.A. (2003) Ear nose and throat manifestations of sarcoidosis. *Otolaryngologic Clinics of North America*, **36**, 673-684. [doi:10.1016/S0030-6665\(03\)00030-6](https://doi.org/10.1016/S0030-6665(03)00030-6)
- [2] Dean, C.M., Sataloff, R.T., Hawkshaw, M.J. and Pribikin, E. (2002) Laryngeal sarcoidosis. *Journal of Voice*, **16**, 283-288. [doi:10.1016/S0892-1997\(02\)00099-1](https://doi.org/10.1016/S0892-1997(02)00099-1)
- [3] Poe, D.L. (1940) Sarcoidosis of the larynx. *Archives of Otolaryngology*, **32**, 315-320. [doi:10.1001/archotol.1940.00660020318007](https://doi.org/10.1001/archotol.1940.00660020318007)
- [4] Vijay, A.R., Karthikeyan, K., Jayawardena, S., Muhammed, U.R., Rashmikant, D. and Padmanabhan, K. (2005) Persistent hoarseness of voice in a sarcoid patient: A clue to laryngeal sarcoidosis; a potential cause of upper airway obstruction. *Chest*, **128**, 465S.