

A late dissociation of the ceramic component of a sandwich liner cup in a total hip arthroplasty

—Case report and review of the literature

Pieter-Jan De Roo^{1,2}, Franky Steenbrugge^{1,2}, Martijn Raaijmakers^{1*}

¹Department of Orthopaedic Surgery & Traumatology, Aalst, Belgium;

*Corresponding Author: martijn.raaijmakers@gmail.com

²Department of Orthopaedic Surgery & Traumatology, Ghent University Hospital, Ghent, Belgium

Received 3 March 2013; revised 20 April 2013; accepted 4 May 2013

Copyright © 2013 Pieter-Jan De Roo *et al.* This is an open access article distributed under the Creative Commons Attribution License, which permits unrestricted use, distribution, and reproduction in any medium, provided the original work is properly cited.

ABSTRACT

We present a case of a 71-year-old woman with unexplained instability of her total hip arthroplasty 12 years after implantation due to loosening of the ceramic component of a sandwich ceramic in polyethylene liner. She experienced in total 2 dislocations in 6 months. These events occurred without fracture of the ceramic liner. Sandwich ceramic liners were introduced with the idea of combining the benefits of ceramic and polyethylene bearings in total hip arthroplasty in order to reduce wear and to allow a ceramic on ceramic bearing to be used in a cup designed for polyethylene inserts only. Although some reports showed promising early results, case reports and later on retrospective analysis showed high fracture rates of the ceramic liner component. We believe that loosening of the ceramic component may precede fracture of the liner and that a ceramic on ceramic configuration is preferable.

Keywords: Total Hip Arthroplasty; Sandwich Cup; Complication; Hip Instability; Cup Revision

1. INTRODUCTION

Osteolysis resulting from a chronic inflammatory reaction to particulate debris is one of the main reasons for aseptic loosening of prosthetic components. It's related to the amount and origin of debris formed at the articular interface [1]. Ultra high molecular weight polyethylene debris is indicated as the main responsible for processes of loosening of an arthroplasty [2]. Other bearing surfaces were introduced in order to reduce the debris. Alumina ceramic-on-ceramic total hip arthroplasty (THA)

has been widely used clinically since its introduction in the seventies by Boutin in France [3]. It has the advantages of low surface roughness, high scratch resistance and high wettability, which produces very low friction and reduces adhesive-abrasive and third-body wear [4]. These advantages make the ceramic-ceramic bearing for THA an attractive alternative to other bearing surfaces such as metal-on-metal or ultra high molecular weight polyethylene on ceramic or metal. However, due to its inherent stiffness, alumina bearings are susceptible to fractures. Theoretical, an ideal acetabular component should combine ceramics and polyethylene's favorable features. A liner introduced by the Lima Society in 1993 tried to cope with these problems by commercializing a ceramic liner set with polyethylene. The advantages of a ceramic-ceramic bearing surface were maintained while having a much lower structural stiffness than a full ceramic acetabular liner [5]. Ravasi and Sansone reported good-to-excellent outcomes with this liner at 5 years follow up [2]. However, recently reports are published with high fracture rates of the liner component [5-8]. To the best of our knowledge, this is the first report of a late dissociation of the ceramic-polyethylene interface of a sandwich cup resulting in instability of the hip.

2. CASE REPORT

In 2000, an Allofit S acetabular component (Zimmer[®]) with a sandwich Alfa Cerasul liner (Zimmer[®]) and a cementless Emeraude femoral component (Zimmer[®]) with a 28 mm medium ceramic Cerasul head (Zimmer[®]) were placed in a 59-year-old woman for right hip osteoarthritis. In 2011 she experienced a traumatic dislocation (**Figure 1**). Intra operative testing after reduction revealed a stable hip and fluoroscopy showed no abnormalities. The patient was instructed to avoid deep hip flexion. In 2012 a second dislocation occurred with intra operative testing

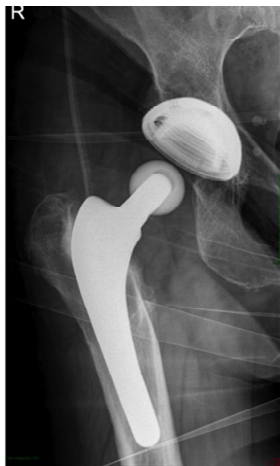

Figure 1. Radiograph of the dislocated THA.

revealing instability in deep flexion and endorotation. Afterwards the patient reports an intermittent crunch and unstable feeling. Radiography revealed neither ceramic debris nor signs of loosening. Due to the clinical symptoms a revision of the acetabular component was performed. On arthrotomy of the hip we noticed loosening of the ceramic component within the sandwich cup (**Figures 2(A)** and **(B)**). Flexion and endorotation of the hip resulted in motion in retroversion of the ceramic shell thus leading to a posterior dislocation of the hip. No signs of fracture or ceramic debris were seen. The liner could easily be removed and the Allofit shell revealed no signs of wear or loosening and had a stable fixation. A high wall all polyethylene liner was inserted. A 32 mm medium ceramic head was placed to augment stability (**Figure 3**). Rehabilitation was initiated with full weight bearing and crutches were used as necessary. The patient was seen at 6 and 12 weeks post-operatively. A normal mobility of the hip was noted, no residual pain.

3. DISCUSSION

Since its introduction by Boutin, ceramic on ceramic liners have been clinically used with good results. A 95% survivorship is reported at 3 to 10 year follow up [9]. Due to its geometric form, wettable surface and hardness ceramic liners maintain lubrication and increase the resistance to third body wear [10]. The main risk of the alumina ceramic coupling remains fracture of the head of the liner. To our knowledge, we are the first to encounter a loosening of the ceramic shell from the polyethylene in a sandwich cup. Ravasi *et al.* published their five-year follow up results from a ceramic sandwich cup in 2002. The study included 51 patients and didn't notice any lines of periprosthetic radiolucency nor migration. No fracture of the liner occurred and from their series only one revision after two weeks due to excessive cup retro-




Figure 2. The sandwich cup with the ceramic insert in-place (B) and out-of-place (A).

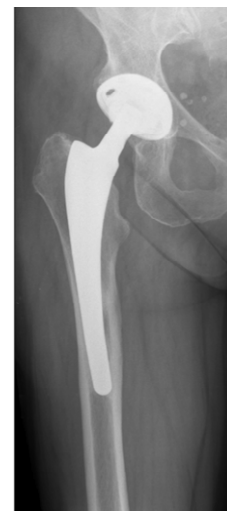

Figure 3. Radiograph of the revision THA.

version was necessary [2]. In a ten-year follow-up study by Park *et al.* 102 sandwich cup were reviewed [11]. Three revisions, one acetabular loosening and two liner fractures were reported. Their Kaplan-Meier survival probability at ten years was 95.3%. They state that ten-year results of cementless THA with a sandwich-type alumina ceramic bearing are encouraging. In the literature only a few case reports [10,12] and in the last few years retrospective reports have been published with rates of liner fractures in sandwich-type cups ranging from 2% to 18%. One case report has been published of a dissociation between the polyethylene and the metal shell [4]. The authors state that the failure mode is attributed to increased rotational torque secondary to peripheral wear. In a retrospective study by Lopes *et al.*, 353 ceramic-polyethylene sandwich liner acetabular components were reviewed [5]. Seven of these (2%) fractured at a mean of 4.3 years. No trauma or abnormal physical activity was observed; neither were there dislocations preceding liner fracture. Viste and coworkers published

their results of 124 consecutive THA with a sandwich liner [8]. They reported five cases (3.7%) of liner fracture at a mean follow-up of 9.9 years. No unusual traumatic event was noted, but some patients complained of hip pain and cracking noises for several months. Poggie *et al.* published in 2007 their results of a prospective study with 315 sandwich-type cups [13]. They encountered fourteen liner failures (4.4%) with ceramic fracture in twelve of them. All of the failures were at the ceramic-polyethylene interface. Biomechanical in vitro testing could not reproduce the mechanism of ceramic component dissociation. Although they did find a correlation between liner rupture and body weight, other authors do not consider body-weight to be a direct risk factor [5,10,12]. Szymanski and coworkers reported seven liner fractures (5.3%) after a mean follow-up of 32 months [7]. They looked at 132 Atlas III™ sandwich cups with a 28 mm Biolox head. None of these fractures involved trauma. In one patient a liner fracture was discovered during revision after two episodes of dislocation. Kircher *et al.* published in their paper of 2009 a failure of cup design with a fracture rate of 18% [6]. They state that next to cup design, intraoperative range of motion testing and impeccable surgical technique are keystones for good results in ceramic-ceramic bearings. Other risk factors contributing to ceramic component fracture risk include hyperflexion position, high BMI, malposition of the cup and activity [5,7,8,10,11,12].

4. CONCLUSION

Ceramic on ceramic implants have good clinical results [9]. In the late nineties and early years 2000 sandwich cup were introduced to combine the benefits of polyethylene and ceramic implants. Although some reports showed good results [2,11], case reports and recent retrospective analyses have demonstrated a high risk of fracture of the ceramic liner [5-8,10,12,13]. Several authors are expecting an increase of fracture rate over time [7,8,10]. In order to avoid this complication the use of a sandwich cup should be abandoned and that a ceramic-on-ceramic or ceramic-on-polyethylene configuration is preferable.

REFERENCES

- [1] Rubash, H.E., Sinha, R.K., Shanbhag, A.S. and Kim, S.Y. (1998) Pathogenesis of bone loss after total hip arthroplasty. *Orthopedic Clinics of North America*, **292**, 173-186.
- [2] Ravasi, F. and Sansone, V. (2002) Five-year follow-up with a ceramic sandwich cup in total hip replacement. *Archives of Orthopaedic and Trauma Surgery*, **122**, 350-353.
- [3] Boutin, P. (1972) Total arthroplasty of the hip by fritted aluminum prosthesis. Experiment study and 1st clinical applications. *Revue de Chirurgie Orthopedique et Reparatrice de l'Appareil Moteur*, **583**, 229-246.
- [4] Akagi, M., Nonaka, T., Nishisaka, F., Mori, S., Fukuda, K. and Hamanishi, C. (2004) Late dissociation of an alumina-on-alumina bearing modular acetabular component. *Journal of Arthroplasty*, **195**, 647-651. [doi:10.1016/j.arth.2004.02.027](https://doi.org/10.1016/j.arth.2004.02.027)
- [5] Lopes, R., Philippeau, J.M., Passuti, N. and Gouin, F. (2012) High rate of ceramic sandwich liner fracture. *Clinical Orthopaedics and Related Research*, **4706**, 1705-1710. [doi:10.1007/s11999-012-2279-6](https://doi.org/10.1007/s11999-012-2279-6)
- [6] Kirchner, J., Bader, R., Schroeder, B. and Mittelmeier, W. (2009) Extremely high fracture rate of a modular acetabular component with a sandwich polyethylene ceramic insertion for THA: A preliminary report. *Archives of Orthopaedic and Trauma Surgery*, **129**, 1145-1150. [doi:10.1007/s00402-008-0662-2](https://doi.org/10.1007/s00402-008-0662-2)
- [7] Szymanski, C., Guériot, S., Boniface, O., Deladerrière, J.Y., Luneau, S. and Maynou, C. (2011) Sandwich type ceramic liner fracture with the Atlas III™ socket: A study of 144 primary total hip replacements at a mean 74 months' follow-up. *Orthopaedics & Traumatology: Surgery & Research*, **975**, 494-500.
- [8] Viste, A., Chouteau, J., Desmarchelier, R. and Fessy, M.H. (2012) Fractures of a sandwich ceramic liner a ten year follow-up. *International Orthopaedics*, **36**, 955-960. [doi:10.1007/s00264-011-1375-7](https://doi.org/10.1007/s00264-011-1375-7)
- [9] Zywił, M.G., Sayeed, S.A., Johnson, A.J., Schmalzried, T.P., Mont, M.A. (2011) Survival of hard-on-hard bearings in total hip arthroplasty: A systematic review. *Clinical Orthopaedics and Related Research*, **469**, 1535-1546. [doi:10.1007/s11999-010-1658-0](https://doi.org/10.1007/s11999-010-1658-0)
- [10] Hasegawa, M., Sudo, A., Hirata, H. and Uchida, H. (2003) Ceramic acetabular liner fracture in total hip arthroplasty with a ceramic sandwich cup. *Journal of Arthroplasty*, **185**, 658-661. [doi:10.1016/S0883-5403\(03\)00193-1](https://doi.org/10.1016/S0883-5403(03)00193-1)
- [11] Park, Y.S., Park, S.J. and Lim, S.J. (2010) Ten-year results after cementless THA with a sandwich-type ceramic bearing. *Orthopaedics*, **3311**, 796.
- [12] Popescu, D., Gallart, X., Garcia, S., Bori, G., Tomas, X. and Riba, J. (2008) Fracture of a ceramic liner in a total hip arthroplasty with a sandwich cup. *Archives of Orthopaedic and Trauma Surgery*, **128**, 783-785. [doi:10.1007/s00402-007-0536-z](https://doi.org/10.1007/s00402-007-0536-z)
- [13] Poggie, R.A., Turgeon, T.R. and Coutts, R.D. (2007) Failure analysis of a ceramic bearing acetabular component. *Journal of Bone & Joint Surgery*, **89**, 367-375. [doi:10.2106/JBJS.F.00148](https://doi.org/10.2106/JBJS.F.00148)