

Anterior Mitral Valve Orifice in a Dog

Başar Ulaş Sayilkan*, Yücel Meral, Emre Küllük, Duygu Dalgin

Department of Internal Medicine, Faculty of Veterinary Medicine, Ondokuz Mayıs University, Samsun, Turkey

Email: *basarulas.sayilkan@omu.edu.tr

How to cite this paper: Sayilkan, B.U., Meral, Y., Küllük, E. and Dalgin, D. (2021) Anterior Mitral Valve Orifice in a Dog. *Open Journal of Veterinary Medicine*, 11, 117-123.
<https://doi.org/10.4236/ojvm.2021.113007>

Received: March 9, 2021

Accepted: March 28, 2021

Published: March 31, 2021

Copyright © 2021 by author(s) and Scientific Research Publishing Inc.
This work is licensed under the Creative Commons Attribution International License (CC BY 4.0).
<http://creativecommons.org/licenses/by/4.0/>



Open Access

Abstract

The patient was admitted to Ondokuz Mayıs University Animal Hospital Internal Medicine outpatient clinic with complaints of epileptic seizures and hypothyroidism. A description of the patient's owner is available in the history information. There was no physician information. Bradycardia was found in the electrocardiography of the patient. 2-D, M-Mode, PW, CW and Color doppler examinations were performed. Left-ventricular hypokinetic and mitral and tricuspidal valve movements were observed with limited M-Mode imaging. Anterior mitral orifice of 2 mm width was detected on septal mitral valve by PW doppler and color doppler. With this orifice, the presence of regurgitant jet, which covers LA at a rate of 1/3 and was 3.2 m/sec, together with mitral regurgitation (0.5 m/sec.), was demonstrated. PISA calculations; VFR (mL/s), ERO (mm²) and RVol (mL/pulse) values were calculated as if there were mitral regurgitation and data were obtained for mild-moderate mitral regurgitation. Therefore, no operative treatment of the orifice was recommended. Mitral valve orifice is a rare pathology and this is the first report in canine veterinary practice with degenerative mitral valve disorder. We aimed to underline the possibility of mitral orifice development in degenerative mitral valve disorders, known to present with vegetations and varying degrees of prolapsus, conventionally.

Keywords

Dog Echocardiography, Anterior Mitral Valve Orifice, Degenerative Mitral Valve Disorder, Mitral Regurgitation, Doppler Echocardiography

1. Introduction

Mitral valve insufficiency is one of the most common cardiac disorders in dogs. As the result of mitral regurgitation, congestive heart failure can arise if left atrial pressure increases. Mitral regurgitation may be caused by both congenital (Mitral dysplasia) and acquired (Degenerative mitral valve disease, Infective endo-

carditis, Dilated cardiomyopathy) [1]. The aim of this case report is to underline the presence of mitral valve orifice in rare cases of mitral valve disorders. This is also the first report of mitral valve orifice in canine veterinary practice.

2. Case Presentation

The physical examination of an 8-year-old Golden Retriever dog weighing 33.5 kg, who came to our hospital with a complaint of seizures, bruising on the tongue, hypothyroidism, fatigue when exercising by the definition of the patient owner, did not show any abnormalities. There was wheezing in the thoracic occlusion. Pulse quality and pulse from the femoral artery were normal. Jugular vein fullness was normal. Hemogram and serum biochemistry examinations were normal. Cardiac troponin I measurement value was 1.2 mg/dl (normal reference range < 0.10 ng/mL). T4 measurement value was founded 2 µg/dL (normal reference range 1.0 - 4.0 µg/dL). The patient's ECG recordings of 5 mm/mV - 25 mm/sec, presented bradycardia (57 beats/min) with a normal rhythm.

Two-Dimensional (2-D) echocardiography, Motion Mode (M-Mode) echocardiography, Pulse wave (PW) doppler echocardiography, Continuous wave (CW) Doppler echocardiography and Color doppler echocardiography examinations were performed. Echocardiographic data obtained by right parasternal long axis, right parasternal short axis and left parasternal 4 and 5 space imaging with M-Mode imaging of the patient under the guidance of 2-D ultrasonography. Left ventricular hyperkinetic and mitral, tricuspidal valve movement was observed to be limited. The Tei index value was founded 0.70. (**Figure 1 & Figure 2**)

Anterior mitral valve orifice with a width of 2 mm was determined on the septal mitral valve by PW doppler and color doppler. With this orifice, the presence of a regurgitation jet with a velocity of 3.2 m/sec covering 1/3 of the left atrium (LA) was demonstrated. Normal Left Ventricle Outflow Tract (LVOT) and Right Ventricle Outflow Tract (RVOT) width and Proximal Isovelocity Surface Area calculations, PISA; Volume flow rate, VFR (mL/s), Effective Regurgitant Orifice, ERO (mm²) and Regurgitant volume, RVol (mL/pulse) values and estimation of cardiac systolic function (dP/dt) were calculated referring mitral regurgitation presence and data were obtained for mild mitral regurgitation [2]. With this orifice, the presence of regurgitant jet, which covers LA at a rate of 1/3 and was 3.2 m/sec, together with mitral regurgitation (0.5 m/sec.) and dP/dt_{orifice} : 3.02 mmHg/s was demonstrated by continuous wave doppler. The history information given by the owner was unrelated to thyroid and epileptic seizures. The symptoms he described as seizures were related to syncope due to heart failure. Because of the limitations of the conventionally indicated surgical graft and prosthetic valve placement and even if it can be done, because the patient owner does not accept fees, the two regurgitation jets were calculated together and medical treatment was designed according to the present situation, including pimobendan (0.3 mg/kg, SID, orally—Vetmedin, Boehringer Ingelheim,

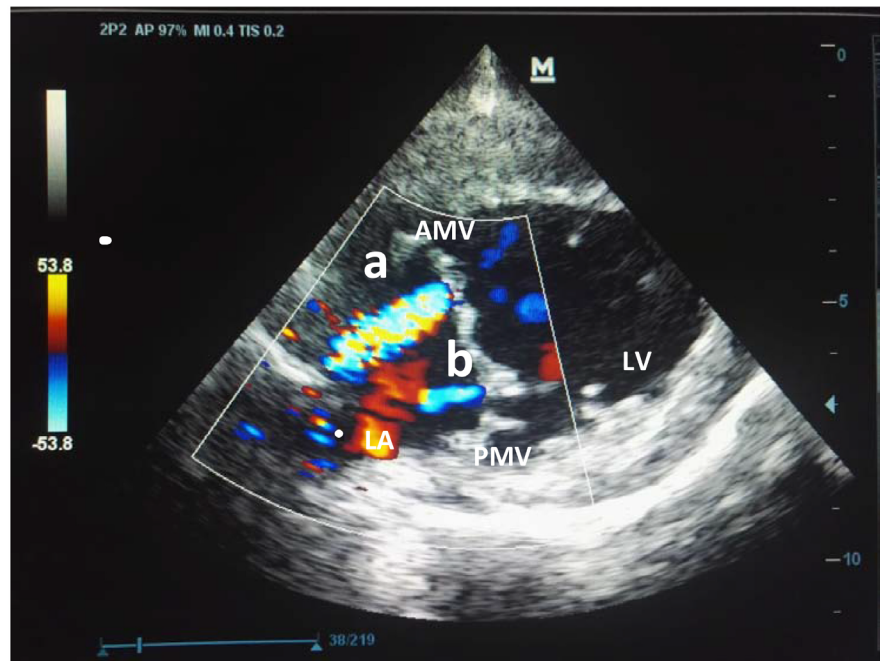


Figure 1. Right parasternal long axis View/5 Mhz probe. (a) Mitral Orificial Regurgitation Area; (b) Mitral Regurgitation Area. AMV: Anterior Mitral Valve, PMV: Posterior Mitral Valve, LV: Left Ventricle, LA: Left Atrium.

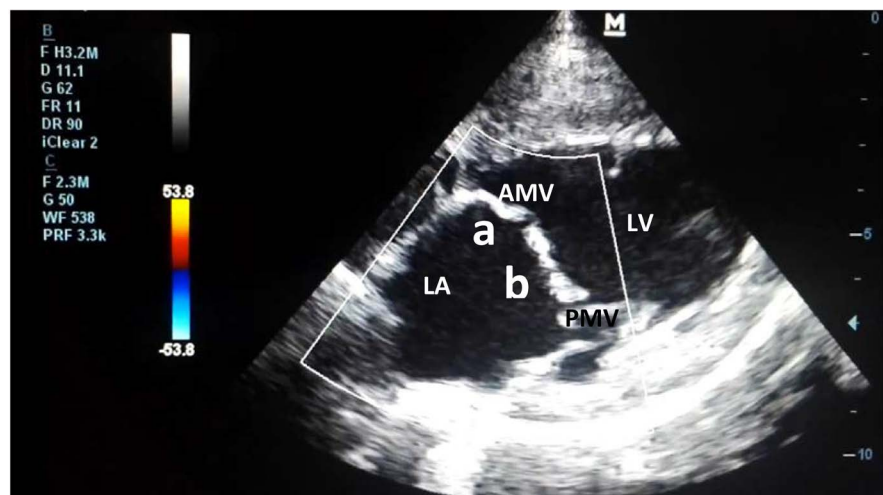


Figure 2. Right parasternal long axis View/5 Mhz probe. (a) Mitral Orificial Regurgitation Area; (b) Mitral Regurgitation Area. AMV: Anterior Mitral Valve, PMV: Posterior Mitral Valve, LV: Left Ventricle, LA: Left Atrium.

Germany), enalapril (0.5 mg/kg, BID, orally—Enapril, Sandoz Novartis, Switzerland), furosemide (2 mg/kg, BID, orally—Lasix, Sanofi Aventis, France) [3].

Valve development involves a complex process that had not been completely understood yet. In addition to the biomechanical properties of the valve, signaling pathways that regulate migration and differentiation of cellular components are thought to be responsible for the embryogenesis and pathogenesis of acquired valve diseases. It was reported that some genes involved in mitral and

aortic valve pathogenesis regulate general differentiation and morphogenesis of all valves [4]. For example, NOTCH-1 signaling involved in the pathogenesis of aortic valve disease has been shown to play important roles in normal valvulogenesis of all valves, by regulating the activity of various other genes and transcription factors [5].

Degenerative mitral valve disease (DMVD) is the most common heart disease in dogs [6]. It is usually a disease of small breed dogs and diagnosed in middle age to geriatric dogs. It is rarely diagnosed in cats [1] [4] [6]. DMVD results from unidentified procedures that cause mitral valve deterioration between the left atrium and left ventricle. In a study, it was reported that genes causing mutation in humans with DMVD, do not cause the same mutation in dogs [7].

The degenerative process causes the valves to thicken and retract, creating its incomplete closure and systolic regurgitation [8]. The chorda tendinea of the mitral valve may rupture and may leak from the left ventricle to the left atrium. If severe enough, this leak may cause congestive heart failure [9]. In myxomatous mitral valve disease, changes in the thickness of the mitral annulus occur. The mitral valve annulus may rupture at a fragile point and cause mitral regurgitation [2]. The presence of orifice in our case may be due to thinning and thickening of the annulus as a result of myxomatous mitral valve disease, or it may be due to gene mutation congenitally. Since the patient's history is unknown, there is no information about whether the disease is congenital or acquired.

Echocardiography is the most commonly used method in the diagnosis of mitral valve diseases [10]. In addition to 2D echocardiography, Doppler echocardiography, 3D echocardiography and 3D transesophageal echocardiography are also used. 3D echocardiography can be used to better monitor the changes in heart structure [11] [12].

Mitral valve replacement or repair is a method in people with mitral valve disease. Studies are underway in dogs to place prosthetic valves or reduce the size of the leak, but these are only experimental and many complications have developed, promising for the future [13] [14].

Because of the limitations of the conventionally indicated surgical graft and prosthetic valve placement, the two regurgitation jets were calculated together and medical treatment was designed according to the present situation, including pimobendan (0.3 mg/kg, SID, orally—Vetmedin, Boehringer Ingelheim, Germany), enalapril (0.5 mg/kg, BID, orally—Enapril, Sandoz Novartis, Switzerland), furosemide (2 mg/kg, BID, orally—Lasix, Sanofi Aventis, France) [3]. The purpose of this treatment improved the patient's quality of life. The treatment plan was based on stage C heart failure reported by ACVIM. (American College of Veterinary Internal Medicine) It is also ranked 3rd in the Tei index by The New York Heart Association. In this way, medical treatment was directed to be given as a result of heart failure (less than normal movement, fatigue in short-term work) [3] [15]. (**Table 1**)

Table 1. Result of echocardiography. LVIDd: Left ventricular internal dimension at end-diastole, LVIDs: Left ventricular internal dimension at end-systole, LVPWd: Left ventricular posterior wall thickness at end-diastole, LVPWs: Left ventricular posterior wall thickness at end-systole. IVSd: Interventricular septum thickness at end-diastole, IVSs: Interventricular septum thickness at end-systole. Aod: Aorta diameter, LAd: Left Atrium diameter, LAd/Aod: Left Atrium diameter/Aorta diameter, EF: Ejection Fraction, EDV: End-diastolic volume, FS: Fractional Shortening, HR: Heart Rate, CO: Cardiac output, MVDESlope: Mitral Valve D-E Slope, MVEFSlope: Mitral Valve E-F Slope, EPSS: E Point Septal Separation, Qp/Qs: Pulmonary flow/systolic flow.

Parameters	Value (with reference range)	Parameters	Value (with reference range)
LVIDd	4.23 cm (3.9 - 5.0)	EF	%59.17 (50 - 70)
LVIDs	2.91 cm (3.4 - 4.5)	EDV	79.77 ml (49 - 93)
LVPWd	<u>1.66 cm</u> (0.8 - 1.2)	FS	%31.08 (27 - 55)
LVPWs	<u>2.11 cm</u> (1.0 - 1.9)	HR	<u>57 bpm</u> (60 - 120)
IVSd	<u>1.94 cm</u> (1.3 - 1.7)	CO	<u>3.089 L/min</u> (3.894 - 6.402)
IVSs	<u>2.80 cm</u> (2.3 - 2.6)	MVDESlope	48.16 cm/sn (28.3 - 60.3)
Aod	2.17 cm (2.2 - 2.9)	MVEFSlope	7.15 cm/sn (5.4 - 17.5)
LAd	3.55 cm (3.3 - 4.3)	EPSS	<u>1.37 cm</u> (0.1 - 1)
LAd/Aod	<u>1.64 cm</u> (< 1)	Qp/Qs	<u>1.7 mm</u> (0.71 - 1.29)

In human medicine, LV Tei index is associated with systolic or diastolic functions due to ischemic or dilated cardiomyopathy. A study measuring global myocardial performance showed LV systolic and diastolic functions in dogs under anesthesia. Thus in humans the LV Tei index is a potential marker for the global function of the heart. LV Tei index was significantly increased in mitral regurgitation animals compared to normal animals. According to The New York Heart Association classification, the Association of the LV Tei index with mitral insufficiency is largely due to the prolongation of ICT + IRT and the reduction of the ejection time. According to NYHA, the ejection time increases as the degree increases. The duration of ejection is largely associated with heart rhythm. In small animal medicine, the TEI index has been reported to be correlated with disease severity and may be important as an early imaging parameter in Dilated Cardiomyopathy disease [15]. The measured Tei index value confirms an abnormality in myocardial function.

Hypothyroidism is a clinical syndrome caused by insufficient production of thyroid hormones. Thyroiditis may show non-obvious clinical signs (such as polyuria). This is due to the destructive effect of possible destructive thyroiditis. In thyroiditis, bradycardia, weak peripheral pulse, apex pulse and low voltage ECG findings are seen. A number of metabolic, dermatological, reproductive, endocrine, neuromuscular, gastrointestinal, hematological and biochemical findings are revealed. Total T4 concentration is a useful test in the diagnosis of hypothyroidism. Sensitivity of the test was reported in dogs with hypothyroidism from 89% to 100%. If the concentration of T4 is low, free T4 and TSH (Thyroid Sti-

mulating Hormone) are evaluated. If the T4 concentration is below the normal value, this alone does not confirm the diagnosis of hypothyroidism. Some drug applications and daily fluctuations can alter this course. Low TT4 and elevated plasma TSH concentration are diagnostic for primary hypothyroidism. The T4 concentration was measured as a result of the persistent attitude of the owner in thyroid disease despite the absence of clinical symptoms [16].

Troponins are cardiac biomarkers that are widely used in animal medicine as well as in human medicine. Increased cardiac troponin in intensive care patients is an independent risk factor for short-and long-term mortality. Cardiac troponins increase in acute heart damage as well as in pericardial diseases. In healthy animals, the level of troponin in the blood is about zero, so any increase represents damage to the heart muscle [17]. The value put forward in our case documents the heart muscle damage. The problem that emerges as a global dysfunction is in correlation with other examinations.

In conclusion, mitral valve orifice is a rare pathology and this is the first report in canine veterinary practice with degenerative mitral valve disorder. We aimed to underline the possibility of mitral orifice development in degenerative mitral valve disorders, known to present with vegetations and varying degrees of prolapsus, conventionally.

Further studies are needed to better understand the mitral valve diseases and develop treatment principles. We believe that this case will shed light on future scientific studies.

Authors' Contributions

B.U. Sayilkan, D. Dalgin, Y. Meral and E. Küllük have performed the clinical procedures. E. Küllük and B.U. Sayilkan have performed laboratory analysis. D. Dalgin and Y. Meral have been involved in drafting the manuscript or revising it critically for important intellectual content and have given final approval of the final version of the manuscript. All authors read and approved the final manuscript.

Conflicts of Interest

The authors declared no potential conflicts of interest with respect to the research, authorship, and/or publication of this article.

References

- [1] Borgarelli, M. and Buchanan, J.W. (2012) Historical Review, Epidemiology and Natural History of Degenerative Mitral Valve Disease. *Journal of Veterinary Cardiology*, **14**, 93-101. <https://doi.org/10.1016/j.jvc.2012.01.011>
- [2] Boswood, A. (2018) Improving Outcomes of Myxomatous Mitral Valve Disease in Dogs. *In Practice*, **40**, 12-15. <https://doi.org/10.1136/inp.k915>
- [3] Keene, B.W., Atkins, C.E., Bonagura, J.D., Fox, P.R., Häggström, J., Fuentes, V.L., Oyama, M.A., Rush, J.E., Stepien, R. and Uechi, M. (2019) ACVIM Consensus Guidelines for the Diagnosis and Treatment of Myxomatous Mitral Valve Disease in Dogs. *Journal of Veterinary Internal Medicine*, **33**, 1127-1140.

- <https://doi.org/10.1111/jvim.15488>
- [4] Şaylik, F., Mutluer, F.O., Tosu, A. and Selçuk, M. (2015) Double Orifice Mitral Valve and Bicuspid Aortic Valve: Pieces of the Same Single Puzzle? *Case Reports in Cardiology*, **2015**, Article ID: 305142. <https://doi.org/10.1155/2015/305142>
 - [5] Borgarelli, M., Abbott, J., Braz-Ruvio, D., Chiavegato, D., Crosara, S., Lamb, K., Ljungvall, I., Poggi, M., Santilli, R.A. and Haggstrom, J. (2015) Prevalance and Prognostic Importance of Pulmonary Hypertension in Dogs with Myxomatous Mitral Valve Disease. *Journal of Veterinary Internal Medicine*, **29**, 569-574. <https://doi.org/10.1111/jvim.12564>
 - [6] Rishniw, M. (2018) Mitral Valve Disease. <https://veterinarypartner.vin.com>
 - [7] Meurs, K.M., Friedenber, S.G., Williams, B., Keene, B.W., Atkins, C.E., Adin, D., Aona, B., Defrancesco, T., Tou, S. and Mackay, T. (2018) Evaluation of Genes Associated with Human Myxomatous Mitral Valve Disease in Dogs with Familial Myxomatous Mitral Valve Degeneration. *The Veterinary Journal*, **232**, 16-19. <https://doi.org/10.1016/j.tvjl.2017.12.002>
 - [8] Sargent, J., Mujzii, R., Mukherjee, R., Somarathne, S., Schranz, K., Stephenson, H., Connolly, D., Brodbelt, D. and Fuentes, V.L. (2015) Echocardiographic Predictors of Survival in Dogs with Myxomatous Mitral Valve Disease. *Journal of Veterinary Cardiology*, **17**, 1-12. <https://doi.org/10.1016/j.jvc.2014.11.001>
 - [9] Kellihan, H.B. and Stepien, R.L. (2012) Pulmonary Hypertension in Canine Degenerative Mitral Valve Disease. *Journal of Veterinary Cardiology*, **14**, 149-164. <https://doi.org/10.1016/j.jvc.2012.01.001>
 - [10] Chetboul, V. and Tissier, R. (2012) Echocardiographic Assesment of Canine Degenerative Mitral Valve Disease. *Journal of Veterinary Cardiology*, **14**, 127-148. <https://doi.org/10.1016/j.jvc.2011.11.005>
 - [11] Kim, Y.H., Choi, G.J. and Park, C. (2018) Rate of Left Ventricular Pressure Change by Doppler Echocardiography in Dogs with Chronic Mitral Valve Disease at Different Stages of Congestive Heart Failure. *Veterinary Radiology & Ultrasound*, **59**, 758-766. <https://doi.org/10.1111/vru.12664>
 - [12] Müller, S., Menciotti, G. and Borgarelli, M. (2017) Anatomic Regurgitant Orifice Area Obtained Using 3D-Echocardiography as an Indicator of Severity of Mitral Regurgitation in Dogs with Myxomatous Mitral Valve Disease. *Journal of Veterinary Cardiology*, **19**, 433-440. <https://doi.org/10.1016/j.jvc.2017.07.001>
 - [13] Borgarelli, M. and Haggstrom, J. (2010) Canine Degenerative Myxomatous Mitral Valve Disease: Natural History, Clinical Presentation and Therapy. *Veterinary Clinics of North America: Small Animal Practice*, **40**, 651-663. <https://doi.org/10.1016/j.cvsm.2010.03.008>
 - [14] Kanemoto, I., Taguchi, D., Mihara, K., Kawase, K., Sato, K., Iwata, K. and Iwanaga, K. (2017) Long-Term Survival of Two Dogs after Mitral Valve Plasty. *Veterinary Science Development*, **7**, 51-54. <https://doi.org/10.4081/vsd.2017.6335>
 - [15] Teshima, K., Asano, K., Iwanaga, K., Koie, H., Uechi, M., Kato, Y., Kutara, K., Kanno, N., Seki, M., Edamura, K., Hasegawa, A. and Tanaka, S. (2007) Evaluation of Left Ventricular Tei Index (Index of Myocardial Performance) in Healthy Dogs and Dogs with Mitral Regurgitation. *Journal of Veterinary Medical Science*, **69**, 117-123.
 - [16] Ferguson, D.C. (2007) Testing for Hypothyroidism in Dogs. *Veterinary Clinics of North America: Small Animal Practice*, **37**, 647-669. <https://doi.org/10.1016/j.cvsm.2007.05.015>
 - [17] Langhorn, R. and Willesen, J. L. (2016) Cardiac Troponins in Dogs and Cats. *Journal of Veterinary Internal Medicine*, **30**, 36-50. <https://doi.org/10.1111/jvim.13801>