

# Appendicular Abscess in General Surgery at the Bocar Sidi Sall University Hospital in Kati

Abdoulaye Diarra<sup>1\*</sup>, Koniba Keita<sup>1</sup>, Amadou Traoré<sup>2</sup>, Assitan Koné<sup>1</sup>, Idrissa Tounkara<sup>2</sup>, Issa Traore<sup>1</sup>, Souleymane Thiam<sup>2</sup>, Fadima K. Tall<sup>3</sup>, Daouda Diallo<sup>3</sup>, Madiassa Konate<sup>2</sup>, Aboubacar Koné<sup>1</sup>, Deborah Sanra Sanogo<sup>4</sup>, Ismaël Konare<sup>1</sup>, Alhassane Traoré<sup>2</sup>, Adégné Togo<sup>2</sup>

<sup>1</sup>Department of General Surgery, CHU of Kati, Kati, Mali

<sup>2</sup>General Surgery Department, CHU Gabriel Touré, Bamako, Mali

<sup>3</sup>Department of Anesthesia and Resuscitation, CHU of Kati, Kati, Mali

<sup>4</sup>Gastroenterology Department, Point G Hospital, Bamako, Mali

Email: \*abdoulayeg2004@yahoo.fr

**How to cite this paper:** Diarra, A., Keita, K., Traoré, A., Koné, A., Tounkara, I., Traore, I., Thiam, S., Tall, F.K., Diallo, D., Konate, M., Koné, A., Sanogo, D.S., Konare, I., Traoré, A. and Togo, A. (2020) Appendicular Abscess in General Surgery at the Bocar Sidi Sall University Hospital in Kati. *Surgical Science*, 11, 479-485.

<https://doi.org/10.4236/ss.2020.1112050>

**Received:** November 16, 2020

**Accepted:** December 25, 2020

**Published:** December 28, 2020

Copyright © 2020 by author(s) and Scientific Research Publishing Inc.

This work is licensed under the Creative Commons Attribution-NonCommercial International License (CC BY-NC 4.0).

<http://creativecommons.org/licenses/by-nc/4.0/>



Open Access

## Abstract

**Introduction:** Appendicular abscess is a progressive complication of acute appendicitis in which the spread of infection is contained by the greater omentum and the slender loops resulting in the formation of a true septate abscess of the large peritoneal cavity. **Materials and Methods:** This was a retrospective study from January 2010 to December 2019 carried out at the Bocar Sidi Sall University Hospital in Kati (CHU BSS in Kati) in general surgery. It concerned all patients operated on for appendicular abscess in the department. **Results:** 75 cases of appendicular abscess were collected, which represented 5.76% of surgical emergencies and 25% of acute appendicitis. The average age of the patients was 29 years. The male sex represented 67% of our patients with a sex ratio of 2. The average consultation time was 5 days. Abdominal pain was noted in all patients. It was localized in the right iliac fossa in 80% (n = 60) and diffuse in 2.7% of cases (n = 2). It was accompanied by nausea and vomiting in 93% of cases (n = 70), urinary disorders in 20% (n = 15), fever in 94% (n = 71), cessation of materials and gas in 1.33% (n = 1). Abdominal ultrasound was performed in 86% (n = 65). It made it possible to suggest a peri-appendicular effusion. Biological examination revealed a neutrophilic hyperleukocytosis greater than 20,000/mm<sup>3</sup> in 47 patients, or 63%. All the patients were operated on by laparotomy (Marc Burney or midline subumbilical) under general anesthesia. The length of hospitalization was 6 days. We have not recorded any deaths. Morbidity was 8% (n = 6) represented by parietal suppuration. The postoperative course was straightforward in 92% of cases (n = 69). **Conclusion:** Appendicular abscess is a frequent medico-surgical emergency, the prognosis of which depends greatly on early diagnosis and

adequate and immediate management.

## Keywords

Appendicular Abscess, Surgery, Kati, Mali

---

## 1. Introduction

Appendicular abscess is a progressive complication of appendicular perforation, in which the spread of infection is contained by the greater omentum and the slender loops, resulting in the formation of a true septate abscess of the large peritoneal cavity [1]. It constitutes a medico-surgical emergency and accounts for 10% of acute appendicitis in adults in Africa [2]. The diagnosis is purely clinical, but if in doubt ultrasound is the first line examination. This ultrasound has a sensitivity of 80% for diagnosis, and can provide additional information on the topography in case of doubtful diagnosis [2]. This is an exam that is often operator-dependent and difficult when there is too much intestinal gas.

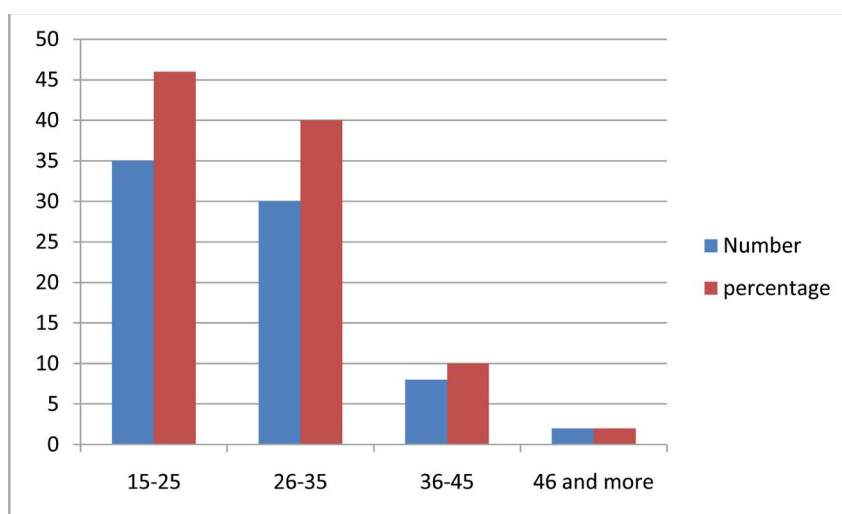
Any appendicular abscess diagnosed must be operated on as soon as possible in order to remove the infectious focus and thus prevent its spread into the large peritoneal cavity. The risk of contamination of the peritoneal cavity in the form of a three-stage peritonitis and digestive fistulas after attempts at appendectomies have made the practice of extra-peritoneal drainage if possible and a delayed appendectomy accepted as therapeutic [3]. Others are for appendectomy and drainage at the same time of operation [4]. Emergency drainage can be done by interventional radiology or by laparotomy associated with appropriate antibiotic therapy [5]. We did not have data concerning the management of this pathology in our department, which motivated us to initiate this work with the objectives of determining the frequency of appendicular abscesses, to describe the diagnostic and therapeutic aspects and to analyze postoperative treatment.

## 2. Material and Methods

This was a retrospective study from January 2010 to December 2019 carried out at the CHU Bocar Sidi Sall in Kati in general surgery. It concerned all patients operated on for appendicular abscess in the department. Generalized appendicular peritonitis and acute appendicitis were not included in this study. We did an exhaustive recruitment of all patients operated on for appendicular abscess who met the inclusion criteria. Our work support was based on the medical files of the patients, all the registers of outpatient consultations, operative reports and hospitalization. The parameters studied were socio-demographic data, clinical and paraclinical, therapeutic data and the course of the pathology. The pathological data were also reviewed. Data analysis was performed using Excel and Epi info 6.0 fr software. The statistical test used was Chi<sup>2</sup> with a significance level  $p < 0.05$ .

### 3. Results

During this study period 1300 patients were operated on urgently, including 300 cases of acute appendicitis, including 75 cases of appendicular abscess, *i.e.* 5.77% of surgical emergencies and 25% of acute appendicitis. The mean age of the patients was  $29 \pm 14.04$  years with extremes of 15 and 70 years. **Figure 1** shows the different age groups. The male sex represented 67% of our patients versus 33% of the female sex and the sex ratio was 2. The mean consultation time was  $5 \pm 3.1$  days (range: 2 and 60 days). Abdominal pain was noted in all patients with a sudden onset in 45.95% and progressive in 54.05%. It was localized in the right iliac fossa in 80% ( $n = 60$ ) and diffuse in 2.7% ( $n = 2$ ). It was accompanied by nausea and vomiting in 93% ( $n = 70$ ), urinary disorders in 20% of cases ( $n = 15$ ), fever in 94% of cases ( $n = 71$ ), stopping of materials and gas in 1.33% of cases ( $n = 1$ ). **Table 1** summarizes the functional signs. On physical examination there was a localized contracture in the right iliac fossa in 90% of cases. The physical signs are grouped together in **Table 2**. Abdominal ultrasound was performed in 86% of cases ( $n = 65$ ). She suggested a peri-appendicular effusion. Biological



**Figure 1.** Age group in years.

**Table 1.** Functional signs.

Functional signs	Number	Percentage
Pain	75	100
Stop of materials and gases	1	1,33
Urinary disorders	15	20
constipation	15	20
bloat	3	4
diarrhea	3	4
Nausea and vomiting	70	93
Rumbling of the right iliac fossa	5	6,6%

examination revealed a neutrophilic hyperleukocytosis greater than 20,000/mm<sup>3</sup> in 47 patients, (63% of cases). All patients were operated on by laparotomy under general anesthesia. The first approach was the Marc Burney incision in 93% of cases (n = 70) and a midline subumbilical incision in 7% of cases (n = 5).

The appendix was laterocecal in 90% of cases (n = 68), retro cecal in 7% of cases (n = 5), and mesoceliac in 3% (n = 2). **Table 3** summarizes the amount of pus aspirated. Macroscopically, the appendix was perforated in 80% of cases (n = 60), gangrenous in 13.3% of cases (n = 10), phlegmonous in 6.6% of cases (n = 5). **Figure 2** shows a necrotic appendix before appendectomy and **Figure 3** a surgical specimen from a necrotic appendix.

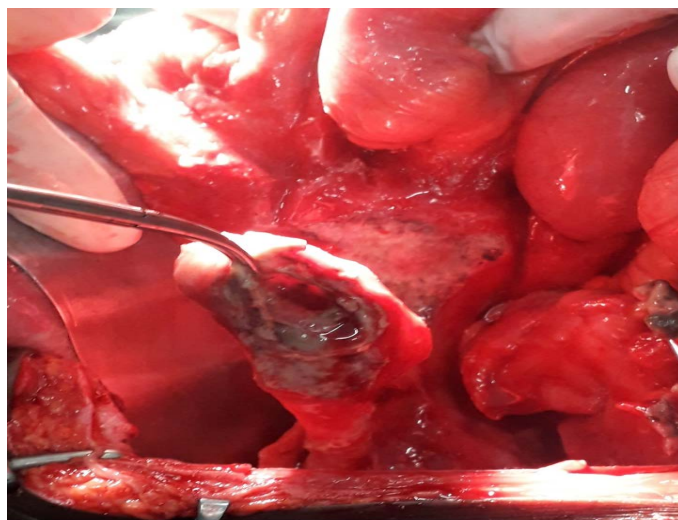
We performed appendectomy with burial of the appendicular stump in 73% of cases (n = 55), associated with drainage of the right iliac fossa with a Delbet drain; appendectomy without burial and drainage in 24% of cases (n = 18),

**Table 2.** Physical signs.

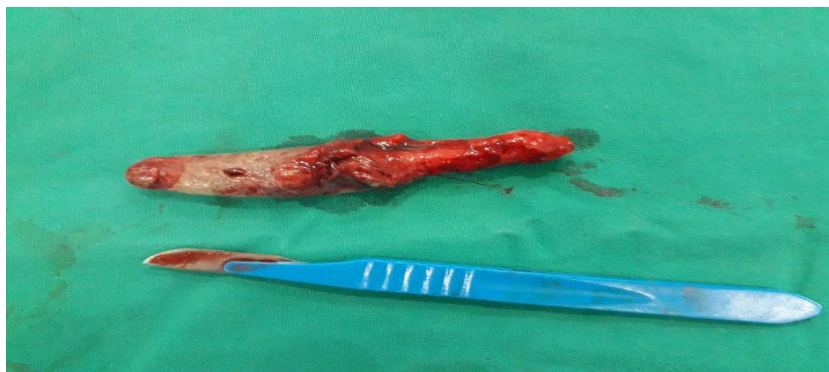Physical signs	Number	Percentage
Pain in Douglace's cul de sac	75	100
Right iliac fossa defense	7	9
Contracture of the right iliac fossa	68	90
Arch of the right iliac fossa	20	26

**Table 3.** Distribution according to the amount of pus aspirated.

Amount of pus in milliliter	Number	Percentage
<20	3	4%
30 - 50	10	13%
60 - 90	60	80%
>100	2	3%



**Figure 2.** Appendicular perforation abscess.



**Figure 3.** Appendectomy patch for appendicular abscess.

drainage alone (delayed appendectomy) in 3% of cases ( $n = 2$ ). The anatomopathological study was carried out on all surgical specimens, thus confirming the diagnosis of appendicular abscess. On cytobacteriological examination of the pus, the most found germs were *Escherichia coli* in 51%, *Klebsiella oxytoca* in 16%, *Klebsiella pneumoniae* 13%, *Enterobacter cloacae* 11% The germs found were 100% sensitive to imipenem. The length of hospitalization was 6 days (range: 2 and 17 days).

We have not recorded any deaths. Morbidity was 8% ( $n = 6$ ) represented by parietal suppuration. The postoperative course was straightforward in 92% of cases ( $n = 69$ ).

#### 4. Discussion

An appendicular abscess is a significant complication of acute appendicitis. It accounts for 10% of acute appendicitis in adults in Africa [2], versus 50% in young children [1]. In our series, it represented 25% of acute appendicitis. Acute appendicitis being an affection of the young subject, appendicular abscess is also it, the same observations were made in the Cameroonian and Nigerian series. Sex does not represent a risk factor [6], the sex ratio of our series is identical to that of the Nigerian and Cameroonian authors [2] [7].

The time to consultation is a determining factor in the prognosis of appendicitis, and therefore in the occurrence of a probable abscess [8] [9]. We observed a real delay in the consultation after the onset of symptoms in our study with an average duration of 5 days; which is the basis of the constitution of the abscess itself. The same is true for Hussain in Saudi Arabia who reported an average consultation time of 6 days [10].

The diagnosis of the abscess is usually clinical. Pain in the right iliac fossa and fever are the most constant signs in our study and that of Cameroonian and Saudi authors [2] [10]. This violent pain is generally non-variable (right iliac fossa) [5] [11].

The parietal defense of the right iliac fossa due to peritoneal irritation as well as the wheelbase are signs that strongly support appendicular abscess [5].

Ultrasound with a diagnostic sensitivity of 80% can provide additional infor-

mation on the topography in case of doubtful diagnosis [2]. This is an exam that is often operator-dependent and difficult when there is too much intestinal gas. Polynuclear neutrophilic hyperleukocytosis is constant, in our study it was greater than 20,000/mm<sup>3</sup> in 47 patients, or 63% of cases. Any appendicular abscess diagnosed must be operated on as soon as possible in order to remove the infectious focus and thus prevent its distribution into the large peritoneal cavity.

Laparoscopy is recommended for its advantages over the open approach, however it is not recommended by Bittner R and Frazée RC in very advanced cases [6] [8].

Mac Burney's approach is the most popular in terms of its elective and aesthetic character. It was performed in 85.71% of cases during our study. For the other patients, the wide midline approach was performed because of signs suggestive of generalized peritonitis in 14.29% of cases. These different approaches were guided by the clinic and often the intraoperative findings.

The therapeutic strategy to adopt is controversial. Previously, authors suggested drainage of the abscess and the appendectomy was postponed three to six months after [3] in order to avoid intraoperative complications. Others are for appendectomy and drainage at the same time of operation [4].

Appendectomy with drainage of the abscess is the treatment of choice with a low morbidity rate and shorter hospital stay [12]. The burial of the appendicular stump will depend on local conditions, in other words the degree of inflammation of the cecal wall.

Some authors systematically practice appendicular burying, others on the contrary condemn this practice because, according to them, the inflammation of the appendicular stump promotes perforation of the lower fundus cecal [13].

The morbidity in our series of 14.3% is higher than those of the Cameroonian [2] and Italian [14] series, this could be related to the size of our sample. Mortality is mainly a function of the degree of septicity of the cavity, the time taken to take charge and the associated defects. We have not recorded any deaths.

## 5. Conclusion

Appendicular abscess is a frequent medico-surgical emergency, the prognosis of which depends greatly on early diagnosis and adequate and immediate management.

## Conflicts of Interest

The authors declare no conflicts of interest regarding the publication of this paper.

## References

- [1] Garcia, S., Heloury, Y. and Plattner, V. (1990) Appendicite aigue et péritonite: Chirurgie digestive de l'enfant. Ed. Douin, Paris, 6.
- [2] Guifo, M.L., Takongmo, S. and Fokou, M. (2010) Abcès appendiculaire: Analyse de

- 19 cas traités au CHU de Yaoundé et Dédutions pratiques. *Pan African Medical Journal*, **5**, 236-239.
- [3] Menegaux, G. and Menegaux, J.C. (1965) Manuel de pathologie chirurgical. Masson et Cie Editeurs, Paris.
  - [4] Eriksson, S. and Styrud, J. (1998) Interval Appendicectomy: A Retrospective Study. *European Journal of Surgery*, **164**, 771-774. <https://doi.org/10.1080/110241598750005417>
  - [5] Valayer, J., et al. (1989) Appendicite et péritonite appendiculaire de l'enfant. *Encyclopédie Médicale de Chirurgie (Paris)*, **146**, 10-19.
  - [6] Reinhard, B. (2006) Laparoscopic Surgery—15 Years after Clinical Introduction. *World Journal of Surgery*, **30**, 1190-203. <https://doi.org/10.1007/s00268-005-0644-2>
  - [7] Okafor, P.I.S., Okafor, J.C. and Chianakwana, G.U. (2003) Management of Appendiceal Masses in Peripheral Hospital in Nigeria: Review of Thirty Cases. *World Journal of Surgery*, **27**, 800-803. <https://doi.org/10.1007/s00268-003-6891-1>
  - [8] Frazee, R.C., Roberts, J.W., Symmonds, R.E., Snyder, S.K., Hendricks, J.C., Smith, R.W., Custer3rd, M.D. and Harrison, J.B. (1994) A Prospective Randomized Trial Comparing Open Versus Laparoscopic Appendectomy. *Annals of Surgery*, **219**, 725-728. <https://doi.org/10.1097/00000658-199406000-00017>
  - [9] Farthouat, P., Fall, O., Goubemy; M.O., Sow, A. and Millo, A. (2005) Appendicectomy en milieu tropical: Etude prospective à l'Hopital principal de Dakar. *Médecine Tropicale*, **65**, 549-553.
  - [10] Hussain et al. (2011) Gestion des abcès appendiculaires: Département de Chirurgie King Saud Medical City, Riyad au Royaume uni d'Arabie Saoudite. Thèse de Médecine, 4.
  - [11] Mutter, D. and Marescaux, J. (2013) Appendicites aiguës, chirurgie A, Hôpital civil. Strasbourg. *Digestive Diseases*, **31**, 76-82.
  - [12] Brocoq, P., Poilleux, F. and Charbrut, R. (1925) Appendicite aigue vue tardivement. *Traité des urgences en Chirurgie Tome 1*, Masson, 588-590.
  - [13] Paulin, F. (1987) Les aspects épidémiologiques, cliniques et thérapeutiques de l'appendicite de l'enfant de zéro à dix-sept ans au CHU Yalgado Ouedraogo Burkina Faso. Thèse de Médecine, 36.
  - [14] Chir, M. (1997) Le rôle de la chirurgie dans le traitement de l'abcès appendiculaire. *Annales de Chirurgie*, **52**, 577-581.