

Convulsive Seizures Revealing Hashimoto's Encephalopathy

Djikoldinguem Marschall Mouandilmdji^{1,2*}, Coudjou Josue Dieu-Donne Ghislain de Chacus³, Kawtar Jamil¹, Maureen Vanessa Ngo Biem², Pape Amadou Niane², Fatou Bintou Thiam², Mame Pathé Diakhate², Nafy Ndiaye¹, Abdoulaye Leye¹

¹Department of Internal Medicine/Endocrinology-Diabetology and Nutrition, Pikine National Hospital Center, Dakar, Senegal

²Hann Maristes Health Center, Dakar, Senegal

³Neuroscience Clinic Ibrahima Pierre Ndiaye, National University Hospital of Fann, Dakar, Senegal

Email: *marschallmouandil@yahoo.fr

How to cite this paper: Mouandilmdji, D.M., de Chacus, C.J.D.-D.G., Jamil, K., Biem, M.V.N., Niane, P.A., Thiam, F.B., Diakhate, M.P., Ndiaye, N. and Leye, A. (2022) Convulsive Seizures Revealing Hashimoto's Encephalopathy. *World Journal of Neuroscience*, 12, 105-111.

<https://doi.org/10.4236/wjns.2022.123011>

Received: December 2, 2021

Accepted: August 2, 2022

Published: August 5, 2022

Copyright © 2022 by author(s) and Scientific Research Publishing Inc. This work is licensed under the Creative Commons Attribution International License (CC BY 4.0).

<http://creativecommons.org/licenses/by/4.0/>



Open Access

Abstract

Introduction: Hashimoto encephalopathy (HE) is an autoimmune disease with different neurological and psychiatric characteristics. It is associated with increased thyroperoxidase autoantibodies. The diagnosis of HE is clinical and involves the detection of serum thyroperoxidase (TPO) antibodies and the exclusion of other etiologies. A clinical response to corticosteroid therapy supports the diagnosis. We report a case of HE revealed by convulsive seizures and cognitive and behavioral disorders. **Observation:** She is a 7-year-old child followed in a neurology unit for convulsive seizures for one year. Clinical examination performed in the endocrinology unit later found tachycardia without goiter, behavioral disorders, difficulties to concentrate as well as psychomotor agitation. Biological work up revealed subclinical hypothyroidism, positive anti-TPO antibodies with normal thyroid ultrasound and brain MRI. The cerebrospinal fluid was clear, normotensive and absence of pleocytosis. The sleep-wake electroencephalogram was well organized for her age with a paroxysmal discharge in the left parieto-temporal region. Based on these clinical, biological and morphological data, the diagnosis of HE was retained. Corticosteroid therapy with prednisone at 1 mg/kg/day was initiated for 6 weeks while reducing the dose progressively. There was a good clinical and biological progress under treatment. **Conclusion:** Hashimoto's encephalopathy is a rare, but probably unrecognized entity. Over the past decades, knowledge about thyroid, brain, immunity interactions has increased. This indicates the importance of a multi-disciplinary approach of endocrinologists, neurologists, psychiatrists and pediatricians for early recognition and treatment.

Keywords

Hypothyroidism, Encephalopathy, Hashimoto's Thyroiditis,

1. Introduction

The encephalopathies associated with Hashimoto's thyroiditis were initially described by Brain *et al.* in 1966. Their prevalence is 2.1/100.000 [1]. However, it is rare in the pediatric population [2]. Hashimoto encephalopathy (HE) is a rare autoimmune disorder that is particularly corticosteroid-sensitive. It associates encephalopathy, autoimmune thyroiditis and high levels of anti-thyroid antibodies in plasma or in cerebrospinal fluid (CSF). The clinical presentation is often misleading, possibly associating cognitive and behavioral disorders such as seizures, abnormal movements, as well as vascular episodes.

Frequent changes in nomenclature and pathophysiology and the lack of uniform diagnostic criteria make diagnosis more difficult [3] [4].

We report the observation of a 7-year-old girl who presented convulsive seizures revealing Hashimoto's encephalopathy.

2. Observation

This is a 7-year-old girl followed up in Neurology Unit for tonic-clonic epileptic seizures for 1 year and under Sodium Valproate 500 mg daily. Analysis of her thyroid function revealed hsTSH at 0.005 mUI/L [0.027 - 4.22 mUI/L] and free T4 level at 20.6 pg/mL (N: 9 - 19 pg/mL). The patient consulted at our Endocrinology unit for the first time six months later. Upon examination, she presented with tachycardia, difficulties to concentrate and psychomotor agitation. There was no goiter and the rest of the clinical examination was unremarkable.

Her new biological work up revealed hsTSH at 12 mUI/L (0.027 - 4.22 mUI/L), free T4 level at 15.58 pg/mL (N: 9 - 19 pg/mL) and anti-TPO antibodies positive at 30 IU/mL [N < 13 IU/mL]. The thyroid ultrasound showed a thyroid in place with a normal volume and echostructure. There was no nodule as well as no hypervascularization on Doppler. The vascular axes were permeable as shown in **Figure 1**.

The brain MRI did not find any abnormality. The cerebrospinal fluid was clear in color, pressure was normal during puncture and there was no cell on cytology. On the sleep-wake electroencephalogram (EEG), the waves were well organized with paroxysmal discharges in the left parietotemporal region as shown in **Figure 2**.

The diagnosis for Hashimoto's encephalopathy in our patient was made based on the neurological and electroencephalographic disorders, positive antiTPO antibodies, good response to corticosteroids and exclusion of other diagnosis.

Hashimoto's encephalopathy is a rare and controversial disease, whose pathophysiology is still poorly understood, and can be presented in several forms. Symptoms can relate to neurological and psychiatric signs associated with an

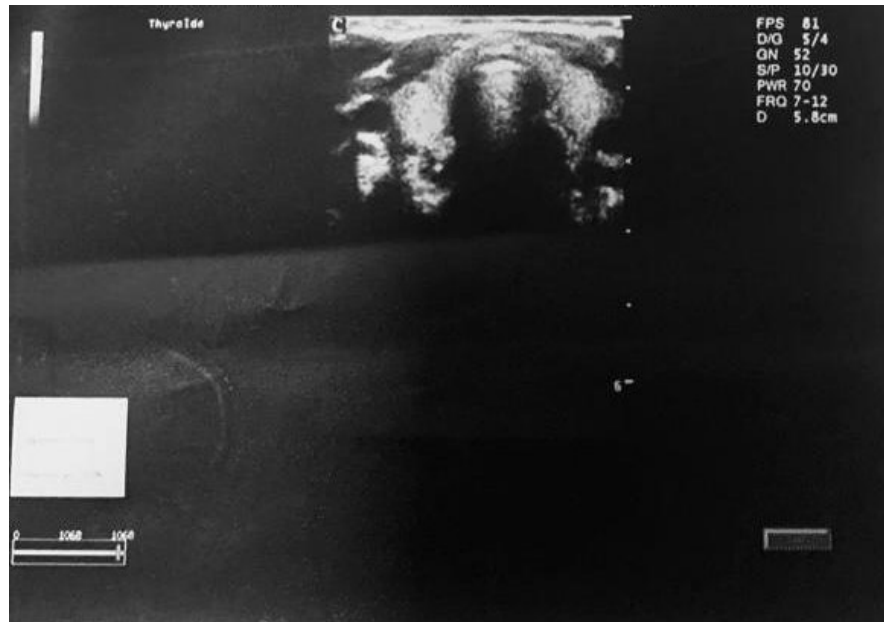

Figure 1. Thyroid ultrasound.

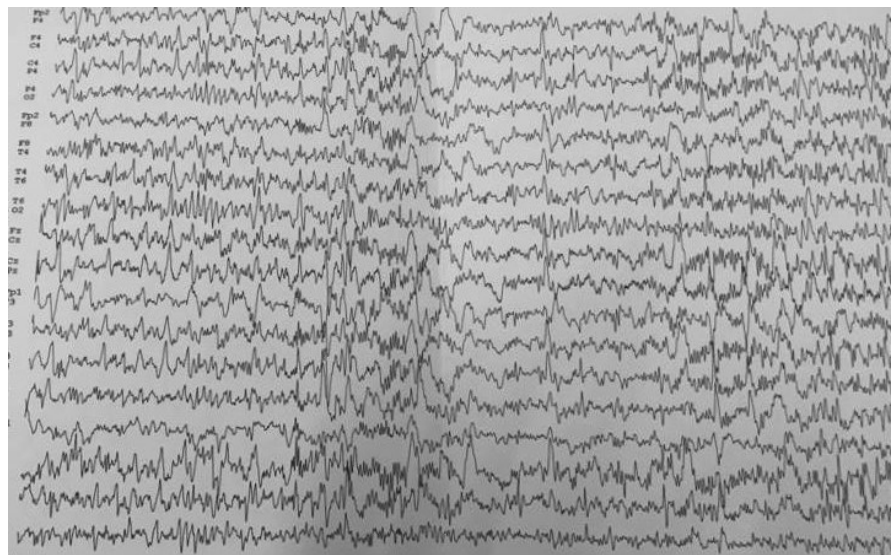


Figure 2. EEG.

increase of antithyroid antibodies, anti-thyroperoxidase antibodies (antiTPO) and antithyroglobulin, in the serum and sometimes in the cerebrospinal fluid of affected patients. Also found protein increase in the cerebrospinal fluid, some abnormalities on electroencephalography in the cerebral magnetic resonance imaging. It often and not always responds to corticosteroids and can start suddenly or progressively in the form of relapse and remission. It is a diagnosis of exclusion.

A substitution with 12.5 µg of levothyroxine was instituted and the patient was put on corticosteroid therapy with prednisone 1 mg/kg for 6 weeks with a decrease of 5 mg every two weeks associated with adjuvant therapy. After two

months of levothyroxine, the hsTSH level normalized within limits at 3.280 mIU/L. After 10 months of 5 mg of prednisone daily, anti TPO antibodies were negative. The evolution remained favorable with an improvement in cognitive and behavioral disorders. The patient did not have any relapse of epileptic seizures again. She maintained clinical and biological euthyroidism with hsTSH at 3.280 mIU/L (0.027 - 4.22 mIU/L). Since she had been on corticosteroid for ten months, a Synacthen test was performed at the end of corticosteroid therapy to confirm that her adrenal glands were still responding; allowing us to definitely stop corticosteroid.

3. Discussion

Hashimoto's encephalopathy is a rare, possibly underdiagnosed autoimmune condition first described in 1966 [2]. The prevalence is estimated at 2.1/100.000, but this number is probably largely underestimated [1]. The average age of onset is 45 years (12 - 84 years). The sex ratio is 4 women to 1 man. It is relatively rare in the pediatric population, with around 60 cases described to date and an unknown prevalence. The majority of pediatric cases are adolescents, with a median age of 14 years at diagnosis [4].

The pathophysiology of HE is still inconclusive. Three major mechanisms have been suspected in the pathogenesis: the vascular mechanism, the autoimmune mechanism (which can combine anti-thyroid autoantibodies, but also extra-thyroid antigens), the toxic mechanism - deregulation of certain hormones, excessively produced in response to hypothyroidism [5] [6].

The pathogenesis of HE remains unexplained. The epileptogenic effect of TRH on suprahypothalamic TRHergic receptors has been mentioned. An increase in their receptivity is also discussed. However, the autoimmune origin seems much more likely and had already been discussed by Brain *et al.* [2] and Mauriac *et al.* either in the form of acute encephalomyelitis or an autoimmune cerebral vasculitis with deposits of immune complexes. A thyroid - central nervous system antigen community was considered. Activated T lymphocytes are thought to cross the blood-brain barrier and cause vasculitis. Brain dysfunction linked to hypoperfusion was found during a SPECT scan [6].

In the greatest series of literature [7] [8], the most frequently reported clinical symptoms are: tremors (80% - 84%), transient aphasia (73% - 80%), headache (50% - 90%) and seizures (60% - 67%). We also find: sleep disorders (55%), myoclonus (38% to 65%), cognitive decline (33% to 100%), psychosis and hallucinations (25% to 50%), ataxia (16% to 65%).

The epileptic seizures present in our patient are found in only 12% of cases.

Always neurological or psychiatric, these signs are not specific and sometimes even frequent in the general population. Thus, their presence alone is necessary but insufficient for the diagnosis of HE.

As for the thyroid status, patients with Hashimoto's encephalopathy are most often moderately hypothyroid, but can also be euthyroid [8], exceptionally

hyperthyroidism has been reported. Our patient went through a phase of sub-clinical hyperthyroidism and then to subclinical hypothyroidism. Neurological explorations do little to help but eliminate other possible causes of encephalopathy (infectious, metabolic, toxic, vascular, neoplastic and paraneoplastic causes). The electroencephalogram often shows a diffuse slowing. Cerebrospinal fluid study found hyperproteinorachia in 75% of cases without pleocytosis. The absence of pleocytosis was also found in this case. Anti-TPO antibodies are sometimes found in cerebrospinal fluid. This assay is not performed systematically in the majority of cases described in the literature [2].

Brain computed tomography is most often normal but can show areas of hypodensity. Magnetic resonance imaging is normal or shows diffuse hyperintensity of white matter in T1 and T2 not enhanced by gadolinium. These abnormalities may disappear after corticosteroid therapy. During Hashimoto's encephalopathy, the plasma level of anti-TPO antibodies is always high and a sign of the disorder. These rates are not correlated with clinical status [4] [9].

HE is a diagnosis of exclusion. It is suspected in patients with neurological and neuropsychiatric conditions highly variable with normal or non-specific MRI results and detection of a high concentration of circulating serum anti TPO antibodies. Clinical response to corticosteroid therapy supports diagnosis [9].

The current standard treatment for HE is the use of corticosteroids in addition to the treatment of any concomitant dysthyroidism. Symptomatic treatment, either with anticonvulsants or neuroleptics, may be indicated depending on the clinical picture.

Usually symptoms improve or go away completely within a few months. The majority of cases, currently over 90% of them, are subject to glucocorticoid therapy with a high initial dose (500 - 1000 mg of methylprednisolone per day for adults or 30 mg/kg of body weight for children) given for 3 - 7 days, followed by an oral relay with prednisone (1 - 2 mg/kg/day, max 60 mg/day) for 6 to 8 weeks. The dose should be gradually reduced. Initially, doses of prednisone ranging from 50 mg to 150 mg per day were also used. No greater benefit of one treatment over another has been demonstrated.

Like our patient, the improvement is singular and often obtained within 72 hours, especially when there are disturbances in vigilance. In general, all the manifestations improve after a few weeks on corticosteroid therapy [2]. Corticosen-sitivity has been proposed as a diagnostic criterion for Hashimoto encephalopathy and the acronym "SREAT" (Steroid-responsive encephalopathy associated with autoimmune thyroiditis) recommended to replace this entity [4].

In cases resistant to corticosteroid therapy, immunosuppressive treatments may be used including plasma exchange, intravenous polyclonal immunoglobulins, methotrexate, azathioprine, cyclophosphamide and mycophenolate mofetil [10]. The first report of intravenous polyclonal immunoglobulin therapy in EH children was described by Berger and al. with a significant advantage. Some authors have reported achieving a lasting remission of 7 years after IVIG treatment in a patient with glucocorticoid resistant HE. Plasmapheresis has been used suc-

cessfully in steroid non-responders and in case of worsening after corticosteroids, possibly due to the elimination of certain autoantibodies or inflammatory mediators from the blood [10] [11].

4. Conclusions

Hashimoto's encephalopathy is a rare, but probably unrecognized entity.

This clinical case reminds us of the various often misleading clinical presentations, current hypotheses regarding its pathophysiology, but also its particular corticosenitivity is insufficient. The latter is a major diagnostic argument. Recognition of Hashimoto's encephalopathy and early initiation of high dose corticosteroid therapy may dramatically improve its clinical course.

Over the past decades, knowledge about thyroid, brain and immunity interactions has increased, which indicates the importance of the multidisciplinary approach associating endocrinologists, neurologists, psychiatrists and pediatricians for early treatment.

Conflicts of Interest

The authors declare no conflicts of interest regarding the publication of this paper.

References

- [1] Ferracci, F., Bertiato, G. and Moretto, G. (2004) Hashimoto's Encephalopathy: Epidemiologic Data and Pathogenetic Considerations. *Journal of the Neurological Sciences*, **217**, 165-168. <https://doi.org/10.1016/j.jns.2003.09.007>
- [2] Archambeaud, F., Galinat, S., Regouby, Y., Magy, L., Rebeyrotte, I., Vallat, J.M. and Teissier, M.P. (2001) Encéphalopathie de Hashimoto. Analyse de quatre observations. *La Revue de Médecine Interne*, **22**, 653-659. [https://doi.org/10.1016/S0248-8663\(01\)00403-9](https://doi.org/10.1016/S0248-8663(01)00403-9)
- [3] Adams, A.V., Mooneyham, G.C., Van Mater, H. and Gallentine, W. (2020) Evaluation of Diagnostic Criteria for Hashimoto's Encephalopathy among Children and Adolescents. *Pediatric Neurology*, **107**, 41-47. <https://doi.org/10.1016/j.pediatrneurol.2019.12.011>
- [4] Chiarello, P., Talarico, V., Nicoletti, A., Rodio, B., Arcuri, P.P., Bosco, D., Gigliotti, F., Galati, M.C. and Raiola, G. (2020) Hashimoto Encephalopathy: A Case Report and A Short Revision of Current Literature: Hashimoto Encephalopathy in Pediatric Age. *Acta Biomedica*, **91**, e2020087.
- [5] Watemberg, N., Greenstein, D. and Levine, A. (2006) Encephalopathy Associated with Hashimoto Thyroiditis: Pediatric Perspective. *Journal of Child Neurology*, **21**, 1-5. <https://doi.org/10.1177/08830738060210010201>
- [6] Graham, B.R., Shiff, N., Nour, M., Hasal, S., Huntsman, R. and Almubarak, S. (2016) Hashimoto Encephalopathy Presenting with Stroke-Like Episodes in an Adolescent Female: A Case Report and Literature Review. *Pediatric Neurology*, **59**, 62-70. <https://doi.org/10.1016/j.pediatrneurol.2016.02.003>
- [7] Castillo, P., Woodruff, B., Caselli, R., Vernino, S., Lucchinetti, C., Swanson, J., Noseworthy, J., Aksamit, A., Carter, J., Sirven, J., Hunder, G., Fatourechi, V., Mokri, B., Drubach, D., Pittock, S., Lennon, V. and Boeve, B. (2006) Steroid-Responsive

- Encephalopathy Associated with Autoimmune Thyroiditis. *Archives of Neurology*, **63**, 197-202. <https://doi.org/10.1001/archneur.63.2.197>
- [8] Chaigne, B., Beaufils, E., Jouan, Y., et al. (2012) Encéphalopathie d'Hashimoto. *La Revue de Médecine Interne*, **33**, 390-395. <https://doi.org/10.1016/j.revmed.2012.02.009>
- [9] Graus, F., Titulaer, M.J., Balu, R., Benseler, S., Bien, C.G., Cellucci, T., Cortese, I., Dale, R.C., Gelfand, J.M., Geschwind, M., Glaser, C.A., Honnorat, J., Höftberger, R., Iizuka, T., Irani, S.R., Lancaster, E., Leypoldt, F., Prüss, H., Rae-Grant, A., Reindl, M., Rosenfeld, M.R., Rostásy, K., Saiz, A., Venkatesan, A., Vincent, A., Wandinger, K.P., Waters, P. and Dalmau, J. (2016) A Clinical Approach to Diagnosis of Autoimmune Encephalitis. *The Lancet Neurology*, **15**, 391-404. [https://doi.org/10.1016/S1474-4422\(15\)00401-9](https://doi.org/10.1016/S1474-4422(15)00401-9)
- [10] Churilov, L.P., Sobolevskaia, P.A. and Stroev, Y.I. (2019) Thyroid Gland and Brain: Enigma of Hashimoto's Encephalopathy. *Best Practice & Research Clinical Endocrinology & Metabolism*, **33**, Article ID: 101364. <https://doi.org/10.1016/j.beem.2019.101364>
- [11] Bin Attique, H., Rao, A., Haider, L. and Trivedi, R. (2019) Successful Treatment of Hashimoto Encephalopathy with Therapeutic Plasma Exchange. *Therapeutic Apheresis and Dialysis*, **24**, 599-601. <https://doi.org/10.1111/1744-9987.13466>