

Atypical Presentation of Prostatic Cancer with Left Axillary and Supraclavicular Lymphadenopathy

Mohamed Izeldeen Ibrahim¹, Abdulgadir Elsunny Hamadelnil², Mutaz Mohamed³, Rehab Osman Abdelrhman⁴, Tamir A. Mahmmoud⁵, Ahmed M. Elnour⁵, Hala Yagoub⁶, Lyla M. Alagab⁶, Ahmed Gaper Hamad⁶

¹Department of Urology, Prince Osman Digna Referral Hospital, Portsudan, Sudan

²Department of Surgery, Red Sea University, Portsudan, Sudan

³Department of General Surgery, Ministry of Health, Sudan

⁴Department of Radiology, Port Corporation Hospital, Portsudan, Sudan

⁵Sudan Medical Specialization Board, Khartoum, Sudan

⁶Prince Osman Digna Referral Hospital, Portsudan, Sudan

Email: mohamedrigan@gmail.com

How to cite this paper: Ibrahim, M.I., Hamadelnil, A.E., Mohamed, M., Abdelrhman, R.O., Mahmmoud, T.A., Elnour, A.M., Yagoub, H., Alagab, L.M. and Hamad, A.G. (2022) Atypical Presentation of Prostatic Cancer with Left Axillary and Supraclavicular Lymphadenopathy. *Open Journal of Urology*, 12, 228-236.

<https://doi.org/10.4236/oju.2022.124022>

Received: December 18, 2021

Accepted: April 21, 2022

Published: April 24, 2022

Copyright © 2022 by author(s) and Scientific Research Publishing Inc.

This work is licensed under the Creative Commons Attribution International License (CC BY 4.0).

<http://creativecommons.org/licenses/by/4.0/>



Open Access

Abstract

Introduction: The burden of prostatic cancer is rising in Sudan. Usually, they present late in their disease with urinary tract obstruction, hematuria, bony pain, or cachexia because there is no screening program. Here we present a patient with prostatic cancer who presented with left axillary mass as his main concern. **Case Description:** 82-year-old Sudanese male presented with a left axillary and left supraclavicular lymphadenopathy of a few months' duration. He underwent a decisional biopsy which showed metastatic adenocarcinoma. Upper and lower GI endoscopy were performed but the latter was complicated by a sigmoid perforation with peritonitis. During laparotomy, multiple enlarged pelvic lymphnodes were encountered and a biopsy result suggested a metastatic prostatic neoplasm. Later, prostatic biopsy confirmed the diagnosis. The patient was treated with bilateral orchidectomy. **Clinical discussion:** Lymphatic metastasis to axillary lymph nodes is a very rare manifestation of prostate cancer and only a few cases have been reported in the literature. It can cause diagnostic difficulty since prostate cancer typically metastasizes to the pelvic lymph node and very rarely involves the supradiaphragmatic lymph node. **Conclusion:** Metastatic prostatic carcinoma should be considered among the causes of supra-diaphragmatic lymphadenopathy. Careful physical and imaging examinations combined with PSA and pathological analysis are essential in the diagnosis of advanced prostate cancer with unusual presentation.

Keywords

Prostatic Cancer, Adenocarcinoma, Axillary Metastasis, Supraclavicular Metastasis, Atypical Presentation

1. Introduction

Prostatic cancer is the third most commonly diagnosed malignancy in males after lung and colorectal cancer with 1,414,259 new cases registered by WHO in 2020. And it is one of the death-leading malignancies worldwide [1].

The risk of developing the disease is linked to factors such as age, race, and family history, with the highest incidence being in the elderly (over 55 years). The incidence and mortality rates are higher among African Americans than Caucasians [2].

The symptoms of advanced prostatic cancer are variable and sometimes not recognized which may lead to delayed diagnosis hematogenous spread frequently affects the bone but can occur in the lungs, liver, pleura, and adrenals. Metastasis to lymph nodes is commonly seen in the pelvic and abdominal groups [3].

The left supraclavicular or Virchow lymph node enlargement is classically linked to carcinoma of the stomach. Other causes include thoracic, abdominopelvic malignancy, lymphoma, tuberculosis, and hydatid disease [4]. Furthermore, the causes of axillary lymphadenopathy include metastatic breast carcinoma, melanoma [5] lymphoma leukemia, and various infections [6].

The combination of supraclavicular and left axillary lymph nodes in a patient may suggest carcinoma of the stomach or other abdominal malignancies [7].

Here we present an unusual presentation of prostatic adenocarcinoma with axillary and supraclavicular mass as the main presentation. This work has been reported in conformity with the SCARE 2020 criteria [8].

2. Case Report

An 82-year-old male presented with complains of left axillary and left side neck swellings for a period of 5 months duration. The patient noticed painless small swellings like the size of a bean mainly in the left axillary area and left side of the neck. They were painless and gradually increased in size with normal overlying skin. There were no swellings in other sites of the body. The patient denied any symptoms of fever, loss of weight or loss of appetite. He was complaining of burning micturition, but there was mild dysurea with no symptoms of obstruction or hematuria. His systemic review was unremarkable and he denied any GI complaints.

His systemic examination revealed a left supraclavicular lymph node and a left axillary lymph node. No neck mass or cervical LN involvement. His chest and abdominal examination were normal. The axillary lymph node was about 4 cm, hard, but mobile.

His labs were normal CBC: HB 11.7 g/dl, TWB CS $4.9 \times 10^3/\mu\text{l}$, PLT $270 \times 10^3/\mu\text{l}$, RFT: urea: 32 mg/dl, creatinine: 0.9 mg/dl, Na: 141, K: 3.5. Urine general: no hematuria.

Cervical and axillary ultrasonography showed suspiciously enlarged lymph nodes (**Figure 1**). Fine needle aspiration cytology was inconclusive. As a result decisional biopsy was done and showed metastatic adenocarcinoma (**Figure 2(A)** and **Figure 2(B)**).

The treating team's main suspicion was GI malignancy, hence, the patient was referred to the gastroenterology department where upper and lower GI endoscopies were done to exclude gastrointestinal malignancy and they revealed no pathology. Four days later, he presented with signs and symptoms of massive pneumoperitoneum and peritonitis. Therefore, colonic perforation was suspected (**Figure 3**). His rectum was empty and the prostate was mildly enlarged with hard palpable nodules bilaterally and obliterated median sulcus.

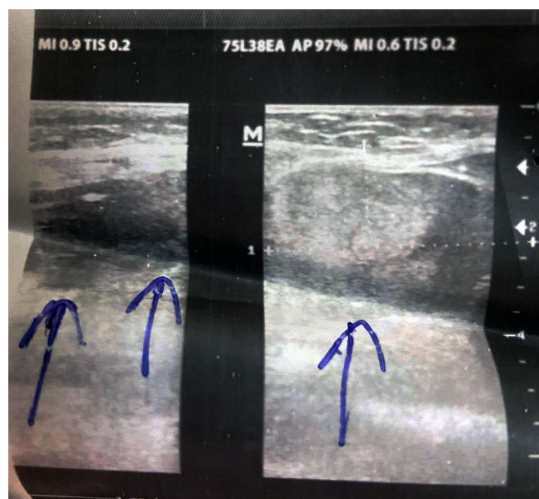


Figure 1. Left supraclavicular and axillary targeted ultrasonography, using linear soft tissue probe, showing enlarged lymph nodes with loss of the normal kidney shape and central fatty hilum.

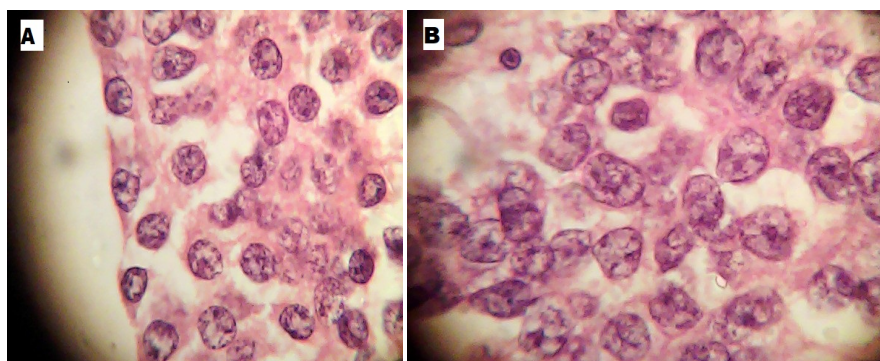


Figure 2. (A) Left supraclavicular and (B) left axillary lymph nodes. Affected lymph nodes by infiltrative tumor composed of diffuse infiltrative sheets. The tumor cells are monomorphic cells with enlarged vesicular nuclei and prominent large nucleoli with focal plasmacytoid features. Stain: H&E. Lens: $\times 100/1.25$ oil immersion.

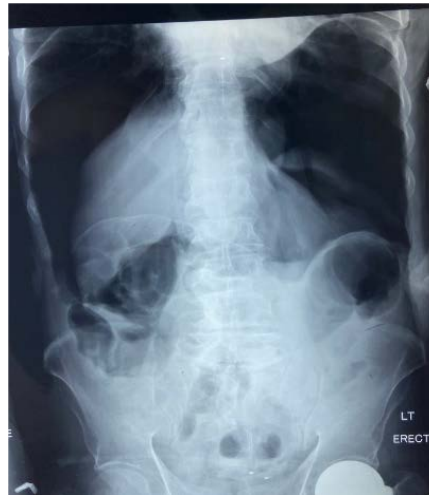

Figure 3. Erect abdominal X-ray showing massive pneumoperitoneum.

Exploratory laparotomy was performed and revealed moderate intraperitoneal pus collection and sigmoid perforation for which a colostomy was made. The rest of the abdomen was unremarkable apart from enlarged pelvic and para-aortic lymph nodes. A biopsy was taken from the iliac nodes and sent for histopathology. The PSA at that time was 449 ng/ml.

The histopathology of the pelvic lymph nodes resulted in metastatic adenocarcinoma of the prostate (**Figure 4**). Tru-cut biopsy from the prostate confirmed the diagnosis with a Gleason score of (3 + 4 = 7/10) (**Figure 5**). Then the patient was offered surgical castration, and a reversal of colostomy was done after he became fit again. Currently, the patient has no symptoms and his last PSA was 0.01ng/ml.

Staging CT chest and abdomen showed Significant enlarged LNs involving most of the abdominal groups and side pelvic wall with the largest on aortocaval (4.7 × 2.7 cm), no lung or mediastinal metastasis was detected (**Figures 6-8**).

3. Discussion

The prostatic cancer burden is increasing in Sudan [9] [10]. Three decades ago, prostate cancer ranked tenth among all men's cancers diagnosed at the Sudan Cancer Registry in 1978, less frequent than skin cancers and non-Hodgkin lymphoma [10]. However, it is now the most common cancer in Sudanese males. It ranked second among all cancers in both sexes after breast in 2012 [11].

Risk factor for prostate cancer includes older men and non-Hispanic Black men. About 6 cases in 10 are diagnosed in men who are 65 or older, and it is rare in men under 40. The average age of men at diagnosis is about 66 [12].

The most common presentation of Prostatic Cancer in the pre-PSA era was urinary complaints or retention, back pain, and hematuria. Currently, with PSA screening, most prostate cancers are diagnosed at an asymptomatic stage. When symptoms do occur, diseases other than prostate cancer may be the cause. For example, urinary frequency, urinary urgency, and decreased urine stream often

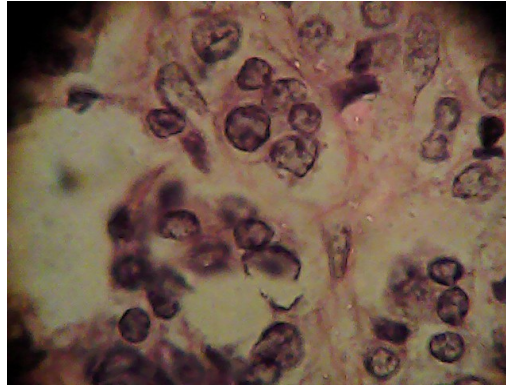


Figure 4. Lymph node biopsy suggesting prostatic origin. Stain: H&E. Lens: $\times 100/1.25$ Oil immersion.

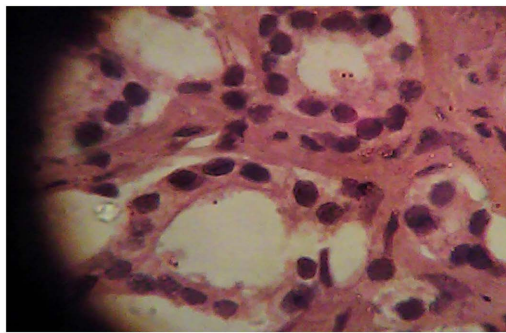


Figure 5. Prostatic tissue infiltrated by malignant gland with foci exhibiting cribriform pattern. Stain: H&E. Lens: $\times 100/1.25$ oil immersion.

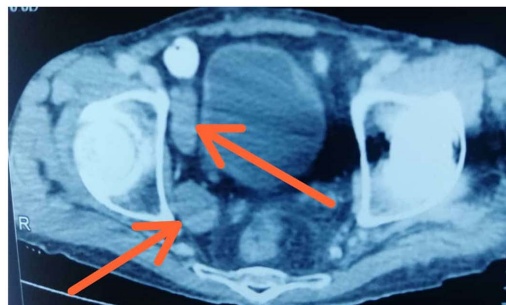


Figure 6. A selected axial cut of CT pelvis, portovenous phase, showing enlargement of the right obturator lymph nodes (arrows).

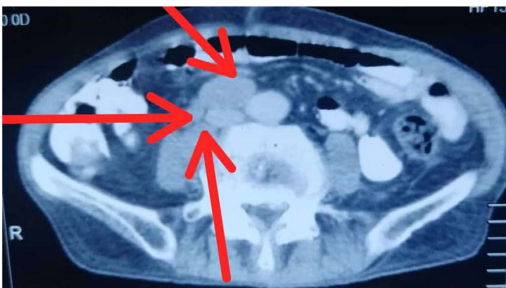

Figure 7. A selected axial cut of CT pelvis, portovenous phase, showing enlargement of the right pelvic sidewall lymph nodes (arrows).

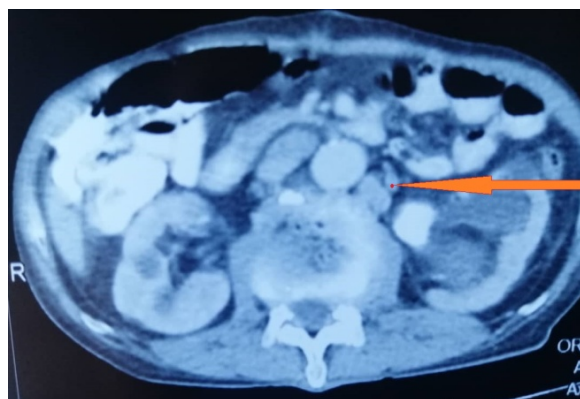


Figure 8. A selected axial cut of CT abdomen, portovenous phase, at the level of the kidneys, showing left para-aortic lymph node and a left renal pelvic stone as an incidental finding.

result from benign prostatic hyperplasia [13]. Our patient was having minimal urinary tract symptoms and only presented to seek medical care after he noticed an axillary mass. This pattern of presentation is very rare and only seldom physicians include prostate cancer in their list of differential diagnosis [14]. Our patient is a male patient so exclusion of breast cancer is very easy based on clinical examination. Next head and neck malignancy was ruled out because no clinical abnormality was present. Hematological malignancy was unlikely based on his CBC and peripheral blood picture. When we received the result of lymph node histopathology which was showing metastatic adenocarcinoma, we diverted our attention to the GI cause (esophagi gastric/pancreatic/colonic origin). Prostatic cancer was not entertained as a differential diagnoses until DRE and exploratory laparotomy was done for the sigmoid perforation.

Metastatic prostate cancer has a recognizable pattern of spread, most often to regional lymph nodes and the bones. Pelvic and abdominal retroperitoneal lymph nodes typically occur in the obturator and internal iliac nodes. Any lymphadenopathy occurring outside the abdomen and pelvis is considered atypical [15]. In one study, the most frequent sites of atypical metastases were the lungs and pleura, liver, supradiaphragmatic lymph nodes, and adrenal glands [16].

Reports describing atypical metastatic sites such as single or generalized lymphadenopathy with the absence of other symptoms of the disease have been documented [17]. But axillary lymph node metastasis was extremely rare and only mentioned in literature as a case report [14] [16] [18]. Other described supraclavicular and mediastinal lymphadenopathy which caused confusion with bronchial carcinoma [19].

Theories behind spread to the left supraclavicular lymph node include spread via Batson's venous plexus. Another theory is that these nodes are located close to the entry of the thoracic duct into the subclavian vein predisposing to retrograde metastasis. Further studies in this regard are necessary to elucidate the exact way of such involvement [20].

Detection of lymph node metastasis is of major prognostic significance for many

cancers. This observation also holds true for prostate cancer where patients with lymph node metastases exhibit a poor prognosis with significantly decreased disease-specific and biochemical recurrence-free survival rates [21].

Our patient fell in grade group 2 according to the 2014 International Society of Urological Pathology (ISUP) Consensus Conference [22]. However, the presence of a left axillary lymph node places him on stage IV as it is regarded as a distant metastasis [23]. A review of the literature has shown that the survival and treatment should be approached with the same protocols used in the patient that initially presented with bony or visceral metastasis. Therefore, surgical castration was offered to him.

4. Conclusion

Atypical presentation in prostatic adenocarcinoma can include left axillary mass. Suspicion of prostate cancer should be included in all elderly patients present with signs suggestive of malignancy. Early PSA measurement could have spared our patients from unnecessary endoscopes.

Consent

Written informed consent was obtained from the patient for publication of this case report and accompanying images. A copy of the written consent is available for review if requested.

Conflicts of Interest

The authors declare no conflicts of interest regarding the publication of this paper.

References

- [1] Sung, H., Ferlay, J., Siegel, R.L., *et al.* (2021) Global Cancer Statistics 2020: GLOBOCAN Estimates of Incidence and Mortality Worldwide for 36 Cancers in 185 Countries. *A Cancer Journal for Clinicians*, **71**, 209-249. <https://doi.org/10.3322/caac.21660>
- [2] Gann, P.H. (2002) Risk Factors for Prostate Cancer. *Reviews in Urology*, **4**, S3-S10.
- [3] Bubendorf, L., Schöpfer, A., Wagner, U., *et al.* (2000) Metastatic Patterns of Prostate Cancer: An Autopsy Study of 1,589 Patients. *Human Pathology*, **31**, 578-583. <https://doi.org/10.1053/hp.2000.6698>
- [4] Zdilla, M.J., Aldawood, A.M., Plata, A., Vos, J.A. and Lambert, H.W. (2019) Troisier Sign and Virchow Node: The Anatomy and Pathology of Pulmonary Adenocarcinoma Metastasis to a Supraclavicular Lymph Node. *Autopsy and Case Reports*, **9**, e2018053. <https://doi.org/10.4322/acr.2018.053>
- [5] Carson, C., Murphy, B. and Kerr, O. (2019) Metastatic Malignant Melanoma: Axillary Lymphadenopathy and the Ugly Duckling Sign. *Annals of Breast Surgery*, **3**, 1-3. <https://doi.org/10.21037/abs.2019.01.03>
- [6] Mohseni, S., Shojaiefard, A., Khorgami, Z., Alinejad, S. and Ghorbani, A. (2014) Peripheral Lymphadenopathy: Approach and Diagnostic Tools. *Iranian Journal of Medical Sciences*, **39**, 158-170.
- [7] Wong, T.Y.E. and Nishihara, K. (2017) Virchow's Node together with an Irish

- Node. *Clinical Case Reports*, **5**, 1046-1047. <https://doi.org/10.1002/ccr3.967>
- [8] Agha, R.A., Franchi, T., Sohrabi, C., et al. (2020) The SCARE 2020 Guideline: Updating Consensus Surgical CAse REport (SCARE) Guidelines. *International Journal of Surgery*, **84**, 226-230. <https://doi.org/10.1016/j.ijssu.2020.10.034>
- [9] Elamin, A., Ibrahim, M.E., Abuidris, D., Mohamed, K.E.H. and Mohammed, S.I. (2015) Part I: Cancer in Sudan—Burden, Distribution, and Trends Breast, Gynecological, and Prostate Cancers. *Cancer Medicine*, **4**, 447-456. <https://doi.org/10.1002/cam4.378>
- [10] Khalid, K., Brair, A., Elhaj, A. and Ali, K. (2011) Prostate-Specific Antigen Level and Risk of Bone Metastasis in Sudanese Patients with Prostate Cancer. *Saudi Journal of Kidney Diseases and Transplantation*, **22**, 1041-1043.
- [11] Hutt, M. (1987) Cancer Occurrence in Developing Countries. *Journal of Clinical Pathology*, **40**, Article No. 474. <https://doi.org/10.1136/jcp.40.4.474-a>
- [12] Rawla, P. (2019) Epidemiology of Prostate Cancer. *World Journal of Oncology*, **10**, 63-89. <https://doi.org/10.14740/wjon1191>
- [13] Ferlay, J., Soerjomataram, I., Dikshit, R., et al. (2015) Cancer Incidence and Mortality Worldwide: Sources, Methods and Major Patterns in GLOBOCAN 2012. *International Journal of Cancer*, **136**, E359-E386. <https://doi.org/10.1002/ijc.29210>
- [14] Collins, G.R., Lopez, Y. and Abreo, F. (2012) Prostatic Adenocarcinoma Metastatic to Axillary Lymph Node Diagnosed by Fine-Needle Aspiration Biopsy. *Diagnostic Cytopathology*, **40**, 751-753. <https://doi.org/10.1002/dc.21679>
- [15] Vinjamoori, A.H., Jagannathan, J.P., Shinagare, A.B., et al. (2012) A Typical Metastases from Prostate Cancer: 10-Year Experience at a Single Institution. *American Journal of Roentgenology*, **199**, 367-372. <https://doi.org/10.2214/AJR.11.7533>
- [16] Mremi, A., Mbwambo, O.J., Bright, F., Mbwambo, J.S., Mteta, K.A. and Ngowi, B.N. (2021) Left Axillary Lymphadenopathy as Initial Presentation of Metastatic Prostate Cancer: A Rare Case Report. *International Journal of Surgery Case Reports*, **82**, Article ID: 105889. <https://doi.org/10.1016/j.ijscr.2021.105889>
- [17] Cho, K.R. and Epstein, J.I. (1987) Metastatic Prostatic Carcinoma to Supradiaphragmatic Lymph Nodes. A Clinicopathologic and Immunohistochemical Study. *The American Journal of Surgical Pathology*, **11**, 457-463. <https://doi.org/10.1097/00000478-198706000-00006>
- [18] Pinaquy, J.B., Allard, J.B., Cornelis, F., Pasticier, G. and De Clermont, H. (2015) Unusual Lymph Node Metastases of Prostate Cancer Detected by 18F-Fluorocholine PET/CT. *Clinical Nuclear Medicine*, **40**, e255-e257. <https://doi.org/10.1097/RLU.0000000000000708>
- [19] Tsujino, K., Sasada, S., Kawahara, K., et al. (2007) A Case of Prostatic Adenocarcinoma Clinically Presenting as Supraclavicular and Mediastinal Lymphadenopathy. *The Journal of the Japanese Respiratory Society*, **45**, 648-653. (In Japanese)
- [20] Mupamombe, C.T., LoGiurato, B., Kampel, L. and Cohen, J.M. (2018) Unilateral Upper Extremity Lymphedema in Metastatic Prostate Cancer. *Clinical Case Reports*, **6**, 1014-1019. <https://doi.org/10.1002/ccr3.1367>
- [21] Datta, K., Muders, M., Zhang, H. and Tindall, D.J. (2010) Mechanism of Lymph Node Metastasis in Prostate Cancer. *Future Oncology*, **6**, 823-836. <https://doi.org/10.2217/fon.10.33>
- [22] Mohler, J.L., Antonarakis, E.S., Armstrong, A.J., et al. (2019) Prostate Cancer, Version 2 NCCN Clinical Practice Guidelines in Oncology. *Journal of the National Comprehensive Cancer Network*, **17**, 479-505.

<https://doi.org/10.6004/jnccn.2019.0023>

- [23] The American Cancer Society Medical and Editorial Content Team (2019) Prostate Cancer Stages and Other Ways to Assess Risk.

<https://www.cancer.org/cancer/prostate-cancer/detection-diagnosis-staging/staging.html>.