

# Ureteric Stone Containing Gas: First Case Report with Review of Cases of Urolithiasis with Gas within the Stone and Its Clinical Implications

Rohan Valsangkar\*, Sameer Jog, Jaydeep Date, Subodh Shivde

Deenanath Mangeshkar Hospital and Research Center, Pune, India

Email: \*rsvalsangkar@gmail.com

**How to cite this paper:** Valsangkar, R., Jog, S., Date, J. and Shivde, S. (2022) Ureteric Stone Containing Gas: First Case Report with Review of Cases of Urolithiasis with Gas within the Stone and Its Clinical Implications. *Open Journal of Urology*, 12, 203-208.

<https://doi.org/10.4236/oju.2022.124020>

**Received:** February 14, 2022

**Accepted:** April 3, 2022

**Published:** April 6, 2022

Copyright © 2022 by author(s) and Scientific Research Publishing Inc.

This work is licensed under the Creative Commons Attribution International License (CC BY 4.0).

<http://creativecommons.org/licenses/by/4.0/>



Open Access

---

## Abstract

We report the first case of a ureteric stone containing gas. This rare stone with gas within it was found during the management of a diabetic patient with urosepsis as the initial presentation. Literature review of cases of renal stone containing gas, mechanisms of gas within the stone, and clinical implications of stone containing gas are discussed. Also, a new terminology is proposed to describe this phenomenon.

## Keywords

Urolithiasis Containing Gas, Pyelonephritis, Pneumourolithiasis

---

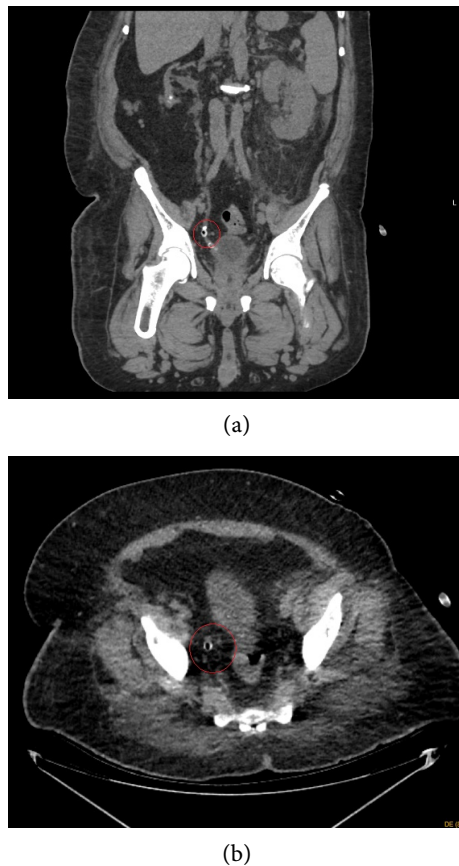
## 1. Introduction

Gas in the pelvicalyceal system (pyelitis) and/or gas in the renal parenchyma (emphysematous pyelonephritis-EPN) is a relatively common finding. However, gas trapped inside a stone (we propose a new term pneumourolithiasis to describe this condition) is exceedingly rare and was reported for the first time in 1998 [1]. Renal or ureteric stones containing gas are rare with 14 cases reported so far in our literature review. We report the first case of ureteric stone containing gas along with a literature review and discuss its pathogenesis, implications of these findings.

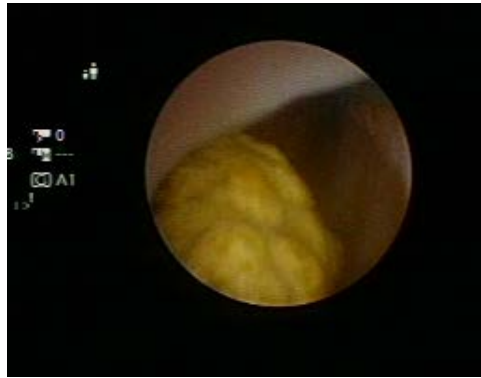## 2. Case Report

A fifty-six-year-old diabetic male presented with abdominal distention, fever, and reduced urine output. On evaluation, he had generalized abdominal disten-

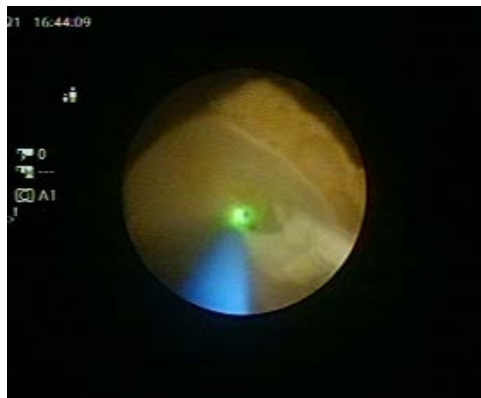tion, along with high creatinine of 5.2 mg/dL, neutrophilic leucocytosis of 30,000/dL and pyuria. Non-contrast CT scan showed bilateral perinephric stranding (but no gas in the pelvicalyceal system or renal parenchyma), a small right kidney and a stone in the right ureter containing air within it (**Figure 1**). He required meropenem (for pyelonephritis) along with bilateral double J (DJ) stenting, after which sepsis settled, counts normalized and abdominal distention reduced. Intraoperative finding of turbid urine efflux from both ureteric orifices was noted during cystoscopy at the time of DJ stenting. The urine culture of this turbid urine showed *E. coli* sensitive to meropenem which was continued for 14 days. He settled clinically with antibiotics and DJ stenting but nadir creatinine remained at 3.8 mg/dL after 2 weeks. At that time, a functional study with a renal scan showed a right renal split function of 12%. He underwent a right ureteroscopy with stone fragmentation along with left DJ stent removal. During fragmentation, once the stone was fragmented with a holmium laser, the inner hollow part of the stone was exposed (**Figure 2**, **Figure 3**). The stone was rather soft easily breakable only with jaws of the ureteroscopic grasper. Stone analysis showed predominant calcium oxalate monohydrate stone (**Figure 4**). Stone culture corresponded to the urine culture. He had an uneventful recovery and the stent was removed after 2 weeks. Creatinine however remained 3.3 mg/dL after a period of 2 months of follow-up and urine culture became negative.



**Figure 1.** CT scan showing the stone and the gas within the stone.

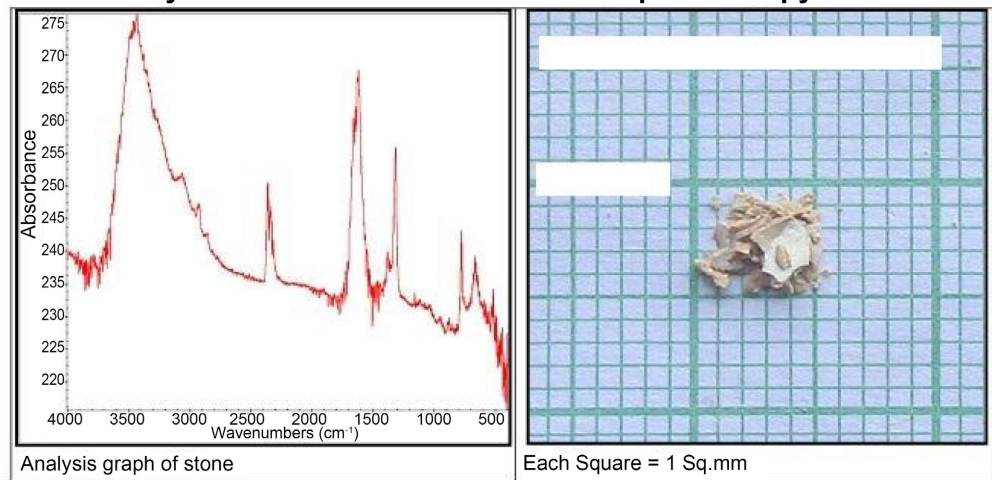


**Figure 2.** Intact stone visualised in the ureter before start of fragmentation.



**Figure 3.** The stone broken with laser and the inner hollow shell exposed.

**FT-IR Analysis: Fourier Transform Infrared Spectroscopy**



**Principal Stone Components (Results):**

Chemical Name	Approximate Percentage	Mineralogical Name	Formula
Calcium Oxalate Monohydrate	76%	Whewellite	$CaC_2O_4 \cdot H_2O$
Calcium Oxalate Dihydrate	16%	Whewellite	$CaC_2O_4 \cdot 2H_2O$
Protein and Blood	08%		

**Figure 4.** Stone analysis showing calcium oxalate composition of the stone.

### 3. Discussion

Gas in the kidney (without any prior instrumentation or communication to the bowel) occurs due to gas-producing infection in the kidney (emphysematous pyelonephritis). A cumulative 14 cases of pneumourolithiasis so far are reported including a series of 5 cases in the last 15 years, which are summarised in **Table 1** [1]-[10]. Current case is the first case of ureteric stone containing gas to be best of our knowledge. (Rapport has mentioned ureteric stones containing gas in the abstract, but in the full-text article review, the stones in the kidney were containing gas, not ureteric stones)

In presence of obstruction by stone and emphysematous pyelitis, gas formed will not be cleared quickly and will be incorporated inside the stone as it is being formed. Pneumourolithiasis without emphysematous infection of the kidney can also be explained by the bacteria within the stone producing gas, as gas is not seen in the rest of the renal pelvicalyceal system in the imaging in the cases reported. Looking at the cases cited in **Table 1**, we are of the opinion that if the stones are of matrix composition, then both these theories may be implicated in the formation of gas within the stone. But in the case, the stone is made up of

**Table 1.** Pubmed summary of cases of urolithiasis with gas within the stone.

Author	Clinical details	Treatment	Stone characteristics
Simpson, 1998 [1]	Left non functioning kidney; left pelviureteric junction obstruction with stones, urosepsis as initial presentation (IP), urine culture <i>E. coli</i>	Left nephrectomy	Matrix
Nilsen 2001 [2]	Pyonephrosis, urine culture <i>E. coli</i>	DJ stenting, later Percutaneous nephrolithotomy (PCNL)	Uric acid
Paterson 2002 [3]	Recurrent febrile UTI as presentation, hyperparathyroidism, left partial staghorn calculus, urine culture Klebsiella		Hydroxyapatite, stone culture negative
Rapoport 2006 [4]	Radiopaque stones in kidney (containing gas) and ureter, sarcoidosis, diabetes, urosepsis as IP,	DJ stenting	Not mentioned
Manny 2012 [5]	5 young females with pelvic stones, 4 cases as urine culture — <i>E. coli</i> in 3 cases, Streptococcus and Staphylococci	PCNL (4 cases), Robot assisted pyelolithotomy (1)	Soft stones, hydroxyapatite, stone culture negative in 3
Durhan 2015 [6]	<i>E. coli</i> infection in nondiabetic 60 year female, sepsis	Death antibiotic treatment	CT scan reported as hyperdense stone
Wazzan 2019 [7]	1 <sup>st</sup> UTI episode in 32 yr female. Only radiological features discussed	Not mentioned	No stone analysis mentioned.
Peter 2020 [8]	Left staghorn stone with perinephric collection in 68 year female Urine culture <i>E. coli</i>	PCNL	Stone culture Klebsiella
Ying 2020 [9]	92 year female with fever	Settled with only antibiotics	-
Hammad 2020 [10]	30 year female, associated emphysematous pyelitis, pneumoureter and pneumobladder	PCNL after 6 weeks	Matrix stone

calcium oxalate, as in our case, the possibility of the bacteria forming the gas within the stone is more likely. As in our case, *E. coli* is the most common infection which ferments sugar, but *Klebsiella* is not uncommon. Importantly urine culture does not always correlate to stone culture in the majority of cases in the review of earlier cases [5] [6]. Diabetes is the most common risk factor for infection (EPN) as high sugars will aid in the formation of sugars. Other factors reported in addition to sarcoidosis, hyperparathyroidism and gout.

Radiologically, it may be possible to see gas within the stone on a plain Xray [2]. But it is best seen in CT scans and characteristically, these stones tend to float in the renal pelvis, which can be appreciated in a CT scan done in the supine and prone position [2].

These stones are soft stones due to infection playing a role in playing its formation [5]. Stone analysis in earlier cases shows those stones to be hydroxyapatite, matrix and uric acid stones. Again calcium oxalate monohydrate in the analysis in our case is less commonly reported. As compared to a standard calcium oxalate stone, we feel the stone was softer (very easily breakable with only a ureteroscopic grasper after initial breakage with a laser). This may be due to gas being present in the scaffolding of the stone [5].

Clinically, the detection of pneumourolithiasis has many implications. Even in absence of emphysematous infection in the kidney, aggressive treatment should be initiated as mortality in pneumourolithiasis without EPN is reported [6]. Stone culture should be sent routinely in such cases, as they do not always respond to urine culture [5]. Stone culture may be a better guide to antibiotic selection for any possible postoperative urosepsis [5]. Since the stones are soft, endourologic treatment options may be preferred to options like pyelolithotomy as there will be a high chance that stone may break down into fragments during removal and intact removal will be difficult [5].

#### **4. Conclusion**

Gas-containing stones are very rare and we report the first case of ureteric stone containing gas. It occurs due to gas-producing bacterial infection within the stone or the gas being incorporated into the stone during the emphysematous infection. Most commonly, these stones are found in diabetic patients. Finding gas within stone should prompt us to start aggressive antibiotic therapy guided by the stone culture which may be different from urine culture. Surgical therapy, initially DJ stenting and later definitive stone removal should consider the softness of the stones in decision making. Probably, endourologic options may be better than options like pyelolithotomy.

#### **Informed Consent**

Permissions were taken from the patients prior to the publication of case report.

#### **Conflicts of Interest**

The authors declare no conflicts of interest regarding the publication of this paper.

## References

- [1] Simpson, A.D., Rytina, E.R., Ball, R.Y. and Gaches, C.G. (1998) 'Stones, Gas and Gaiters': Gas-Filled Matrix Calculi of the Renal Pelvis. *British Journal of Urology*, **81**, 770-772. <https://doi.org/10.1046/j.1464-410x.1998.00594.x>
- [2] Nilsen, F.S., Karlsen, S.J. and Gjertsen, O. (2001) Gas-Containing Renal Stones Treated with Percutaneous Nephrolithotomy: Case Report. *Journal of Endourology*, **15**, 915-917. <https://doi.org/10.1089/089277901753284134>
- [3] Paterson, R.F., Welsch, J.M., Koerner, T. and Lingeman, J.E. (2002) Urinary Calculus Containing Gas. *Urology*, **60**, 164. [https://doi.org/10.1016/S0090-4295\(02\)01666-7](https://doi.org/10.1016/S0090-4295(02)01666-7)
- [4] Rapoport, M.J. and Sadah, A.Y. (2006) Gas-Containing Renal Stones. *Urology*, **68**, e13-e15. <https://doi.org/10.1016/j.urology.2006.05.017>
- [5] Manny, T.B., Mufarrij, P.W., Lange, J.N., Mirzazadeh, M., Hemal, A.K. and Assimos, D.G. (2012) Gas-Containing Renal Stones: Findings from Five Consecutive Patients. *Urology*, **80**, 1203-1208. <https://doi.org/10.1016/j.urology.2012.08.035>
- [6] Durhan, G., Ayyildiz, V., Özmen, M. and Akata, D. (2015) Gas Containing Renal Stone, a Fatal Sign. *CausaPedia*, **4**, Article No. 1188.
- [7] Wazzan, M.A. and Abduljabbar, A.H. (2019) Gas Containing Renal Stone—Case Report. *Urology Case Reports*, **25**, Article ID: 100887. <https://doi.org/10.1016/j.eucr.2019.100887>
- [8] Peter, J., Bhat, S. and Paul, F. (2020) Gas-Containing Renal Stones. *Indian Journal of Urology*, **36**, 67-68.
- [9] Benjamin, L.T.Y., Kiat, L.S. and Li-Tsa, K. (2020). Gas-Containing Renal Stones: A Case Report and Literature Review. *Surgery Case Reports*, 1-3. <https://doi.org/10.31487/j.JSCR.2020.01.08>
- [10] Hammad, F.T. (2020) Gas-Containing Renal Matrix Stones in a Patient with Emphysematous Pyelitis Treated with Delayed Percutaneous Nephrolithotomy. *Journal of Endourology Case Reports*, **6**, 445-447. <https://doi.org/10.1089/cren.2020.0092>