

Role of Plain Abdominal X-Ray in the Differential Diagnosis of Common Acute Abdominal Conditions in Children at Olabisi Onabanjo University Teaching Hospital, Sagamu, Ogun State, Nigeria

Nwokoro Chigbundu Collins^{1*}, Olatunji Ayodeji Anike², Adekanmbi Abiodun Folashade³, Amosu Lukmon Olusesan¹, Ogundele Olufemi Ibukunolu¹, Olarewaju Olufunke Yetunde¹, Oyelekan Abimbola Adeola¹

¹Departments of Surgery, Olabisi Onabanjo University Teaching Hospital, Sagamu, Ogun State, Nigeria

²Department of Radiology, Olabisi Onabanjo University Teaching Hospital, Sagamu, Ogun State, Nigeria

³Department of Paediatrics, Olabisi Onabanjo University Teaching Hospital, Sagamu, Ogun State, Nigeria

Email: *collinsnwokoro@gmail.com

How to cite this paper: Collins, N.C, Anike, O.A., Folashade, A.A., Olusesan, A.L., Ibukunolu, O.O., Yetunde, O.O. and Adeola, O.A. (2023) Role of Plain Abdominal X-Ray in the Differential Diagnosis of Common Acute Abdominal Conditions in Children at Olabisi Onabanjo University Teaching Hospital, Sagamu, Ogun State, Nigeria. *Open Journal of Radiology*, 13, 125-133. <https://doi.org/10.4236/ojrad.2023.133013>

Received: March 15, 2023

Accepted: July 29, 2023

Published: August 1, 2023

Copyright © 2023 by author(s) and Scientific Research Publishing Inc. This work is licensed under the Creative Commons Attribution International License (CC BY 4.0). <http://creativecommons.org/licenses/by/4.0/>



Open Access

Abstract

Background: The plain abdominal x-ray is one of the commonly requested investigations in the children emergency room, paediatric surgical ward and neonatal wards. The short interval required to carry out this investigative procedure and obtain results makes it the first imaging modality used to unravel the different causes of acute abdominal conditions in children. The safety of abdominal x-ray in children makes it attractive for use in paediatric surgical practice as part of routine work-up for undifferentiated acute abdominal conditions and also to diagnose specific causes of acute abdomen in children. **Setting:** Olabisi Onabanjo University Teaching Hospital, Sagamu, Ogun State. **Objectives:** Evaluation of the role of plain abdominal x-ray in diagnosing common acute abdominal conditions in children. **Materials and method:** Patients admitted to the children emergency room, paediatric surgical wards, children's ward and neonatal ward who had plain abdominal x-ray as part of their diagnostic work-up were included in the study. They were studied prospectively between March 2011 and April 2021. **Results:** Three Hundred and Ninety-nine patients who had plain abdominal x-rays as part of their diagnostic work-up were studied. Males were 240 while females were 159, a male to female ratio of 1.5:1. The patients were aged between 1 day to 16 years. Differential diagnoses made with plain abdominal x-ray were intes-

tinal obstruction in 298, perforated viscus 69 patients, intra-abdominal masses 13 patients and location of intra-abdominal foreign body 14. Intestinal obstruction cases in which plain abdominal x-ray played a role in their diagnosis and management included the following: intussusception 66, neonatal sepsis 60, malrotation 48, intestinal atresia 42, anorectal malformation 32, hirschsprung's disease in 30 cases, pyloric stenosis 24, obstructed hernia 22, post-operative adhesions 16 and intestinal helminthiasis 12. Perforated viscus accounted for 69 indications. Out of these indications, perforated gut in intussusception 19, perforated typhoid ileitis was responsible in 13 cases, gut perforation in blunt abdominal trauma 8, perforation in strangulated hernia 11 cases, perforated gut in malrotation 7, cecal perforation in hirschsprungs disease 6 and colonic perforation in necrotizing enterocolitis 5 cases. **Conclusion:** Plain abdominal x-ray remains a role to play in the differential diagnosis and management of common paediatric acute abdominal conditions.

Keywords

Plain, Abdominal, X-Ray, Differential Diagnosis, Acute, Abdominal Conditions, Children

1. Introduction

Acute abdominal conditions present commonly in the children emergency room and their management will require investigative modalities to aid the differential diagnosis of the underlying surgical abdominal condition [1]. Abdominal radiography remains one of the most readily available investigations in the emergency department. In spite of its usefulness in making quick provisional diagnosis for the paediatric patient with surgical abdominal conditions, it is limited by several factors such as low sensitivity and specificity in confirming definitive diagnosis and correctly excluding other differential diagnosis [2].

However, plain radiograph of the abdomen continues to be a great and useful diagnostic tool for quick and early identification of neonatal, infantile, childhood and adolescent abdominal conditions such as neonatal intestinal obstruction, neonatal sepsis, pyloric stenosis, intestinal perforation, swallowed foreign body and abdominal masses. In the past, it was the only available tool for radiological assessment of a paediatric patient with acute abdomen [3].

Presently, the advent of modern radiological modalities of investigations such as abdominal ultrasound, abdominal computerized tomography scan and magnetic resonance imaging techniques have further improved the usefulness of plain abdominal x-ray in resolving more complex surgical conditions of the abdomen in paediatric age group [4].

The non-invasive nature and low-risk of ionizing radiation make plain abdominal x-ray relevant and safe as a radiological modality for the differential diagnosis of children with acute abdominal conditions [5].

In assessing the surgical abdomen of the child using plain abdominal radiograph, the erect, supine and lateral views are usually employed. Other views that could provide useful information are decubitus film and cross-table lateral view [6].

Basic information regarding the size, shape and position of abdominal organs can also be obtained with plain abdominal x-rays. The presence of stones in the gallbladder, kidneys and ureters could be detected by the plain abdominal radiograph [7].

The aim in employing paediatric radiological diagnostic modalities is to obtain the required diagnostic information using the least radiation dosage. For instance, the well-known double-bubble sign is suggestive of duodenal atresia without the need for further radiologic investigations. Plain abdominal radiographs can suggest the presence of pyloric stenosis, intussusception, paralytic ileus, intestinal obstruction, pathologic calcification and abdominal masses [8].

They also provide information on intramural air, portal venous air, free intra-peritoneal air and air under the diaphragm secondary to intestinal perforation. It is important for the paediatrician to be familiar with normal findings of plain abdominal radiographs in infants and young children that are different from those in adults.

The reason for carrying out this study is to evaluate the usefulness of plain abdominal x-rays in making provisional and definitive for common acute abdominal condition in children at our centre.

2. Methodology

Patients admitted to the children emergency room, paediatric surgical wards, children's ward and neonatal ward and who had plain abdominal x-ray as part of their diagnostic work-up were included in the study. They were studied prospectively between March 2011 and April 2021 (10 years period).

The study site was paediatric surgery division of department of surgery, Olabisi Onabanjo University Teaching Hospital, Sagamu, Ogun State, Nigeria.

Ethical approval was obtained from the health and research committee of our institution before the commencement of this study.

Patients who presented with features of acute abdomen and who eventually had plain abdominal x-ray as part of the initial diagnostic investigative modality were enrolled into the study.

The bio-data, clinical features and indications for plain abdominal x-ray requests were documented in a structured proforma. The provisional diagnosis was initially documented before carrying out the plain abdominal x-ray. The features on the plain abdominal x-ray were also noted and recorded in the research proforma.

The relevant parameters seen on plain abdominal x-ray which assisted in assessing the role of plain abdominal x-rays in diagnosing acute abdominal conditions in children were single bubble gas shadow for pyloric stenosis, double bub-

ble gas shadow suggestive of duodenal atresia, triple bubble gas shadow suggestive of jejunal atresia, multiple air-fluid level suggestive of intestinal obstruction, free peritoneal air (pneumo-peritoneum) and air under the diaphragm which suggest intestinal perforation. Others include radiopaque objects for swallowed foreign bodies and soft tissue shadows seen in intra-abdominal masses.

Patients included in this study were those who had features of acute abdomen and associated symptoms and signs which required plain abdominal x-ray as relevant radiological investigation employed towards achieving a definitive pre-operative diagnosis.

Data collected were analyzed using SPSS version 25.

3. Results

Three hundred and ninety-nine patients who had plain abdominal x-rays as part of their diagnostic work-up to unravel the underlying aetiology of acute paediatric surgical abdomen. Males were 240 while females were 159, a male to female ratio of 1.5:1. The patients were aged between 1 day to 16 years. Differential diagnosis made with the plain abdominal x-ray were intestinal obstruction in 298, perforated viscus 69 patients, intra-abdominal masses 13 patients and location of intra-abdominal foreign body 14. Intestinal obstruction cases in which plain abdominal x-ray played a role in their diagnosis and management included the following: intussusception 66, neonatal sepsis 60, malrotation 48, intestinal atresia 42, anorectal malformation 32, hirschsprung's disease in 30 cases, pyloric stenosis 24, obstructed hernia 22, post-operative adhesions 16 and intestinal helminthiasis 12.

Perforated viscus accounted for 69 indications. Out of these indications, perforated gut in intussusception 19, perforated typhoid ileitis was responsible in 13 cases, gut perforation in blunt abdominal trauma 8, perforation in strangulated hernia 11 cases, perforated gut in malrotation 7, ceecal perforation in hirschsprung's disease 6 and colonic perforation in necrotizing enterocolitis 5 cases.

Predominant symptoms that were associated with surgical abdomen in the patients studied were abdominal pain, irritability, abdominal swelling, history of bilious vomiting, history of recurrent and persistent vomiting, history of inability to pass meconium and stool, passage of red currant jelly stool, intra-abdominal masses, history of swallowed foreign body and history of previous abdominal surgery.

Significant physical findings elicited from the patients at presentation were abdominal tenderness in the older child, abdominal distension, hyper-active bowel sounds, hypo-active bowel sounds passage of bloody stool and blood-stained finger on digital rectal examination.

4. Discussion

In our study, we evaluated the usefulness of plain abdominal x-rays in the differential diagnosis of acute abdominal conditions in children. Amongst the patient stu-

died, the commonest indication for using plain abdominal x-ray in children with acute surgical conditions was intestinal obstruction, this was followed by neonatal sepsis. Other indications observed in this study were swallowed foreign body, intestinal perforation from abdominal trauma, strangulated hernia, intussusception and perforated typhoid ileitis. Plain abdominal x-ray was also useful in identifying increments in organ and tissue sizes as seen in abdominal masses. These findings from our study are similar to the results of other workers [9] [10] [11].

Plain abdominal x-ray was useful in making pre-operative provisional and definitive diagnosis for our patients with intestinal obstruction, intestinal perforation, swallowed foreign body and abdominal masses.

Diagnostic features seen on plain abdominal x-rays which assisted in making provisional differential and definitive diagnosis for acute paediatric surgical abdominal conditions includes the single bubble shadow (**Figure 1**) which is suggestive of pyloric stenosis, the double bubble gas-shadow (**Figure 2**) which suggests duodenal atresia, triple bubble gas shadow (**Figure 3**) which suggests jejunal atresia, multiple air-fluid levels suggestive of small bowel obstruction (**Figure 4**), intra-abdominal radiopaque object (foreign body) in the descending colon (**Figure 5(a)**) and intra-abdominal radiopaque object (foreign body) in the stomach (**Figure 5(b)**), pneumo-peritonuem (**Figure 6**) which is in keeping with intestinal perforation. Air under the diaphragm suggests intestinal perforation (**Figure 7**). The usefulness of these features on plain abdominal radiographs in diagnosing acute paediatric surgical abdominal conditions has also been highlighted by some researchers [12] [13] [14]. Traditionally, the erect and supine plain abdominal x-ray views are mostly employed in diagnosing acute paediatric surgical abdominal conditions; these were the views used in our study and this findings is also in agreement with the results of other workers [15] [16].

On the other hand, an erect film can give extra information on the presence of intra-peritoneal free gas and the position of the diaphragm. Other useful views are lateral and lateral decubitus views [17].

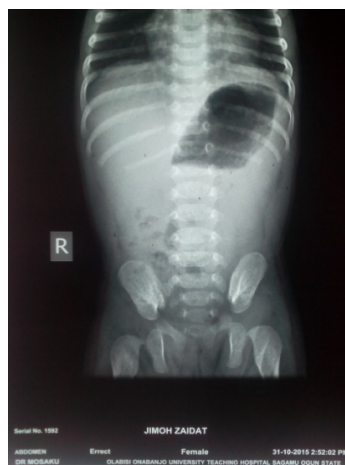

Figure 1. Plain abdominal x-ray showing the single bubble shadow of pyloric stenosis.

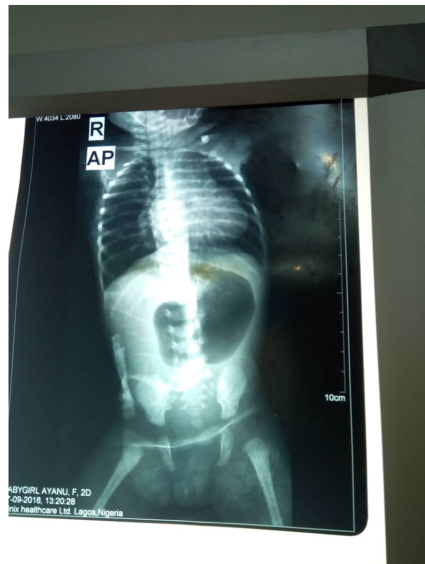

Figure 2. Double bubble gas shadow of duodenal atresia.

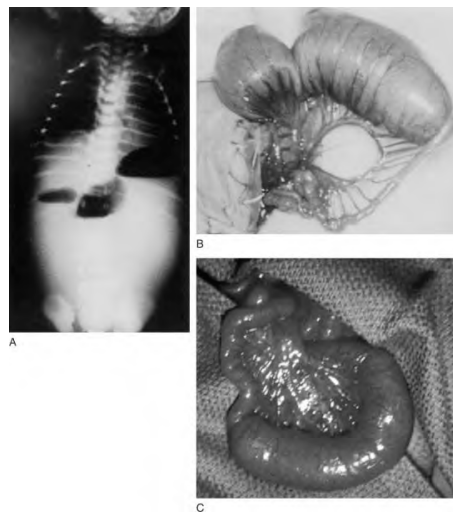


Figure 3. Triple bubble-gas shadow suggestive of jejunal atresia.

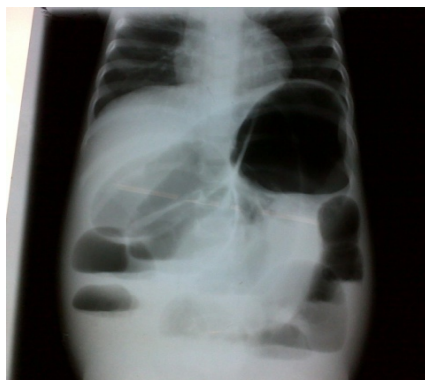

Figure 4. Multiple air-fluid levels with typical step-ladder pattern suggestive of ileal obstruction.

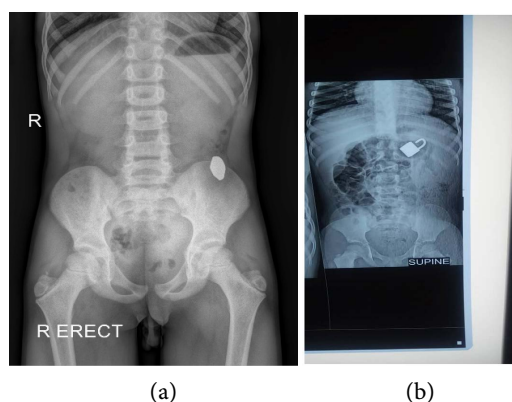


Figure 5. (a) Foreign body in the large bowel (descending colon); (b) Foreign body in the stomach.

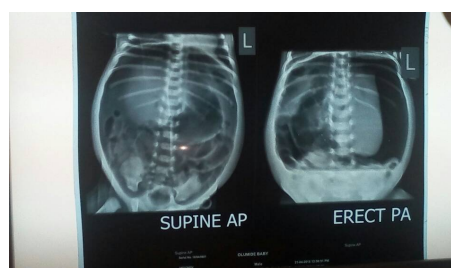


Figure 6. Extra-luminal intra-peritoneal gas suggestive of pneumo-peritoneum secondary to intestinal perforation.

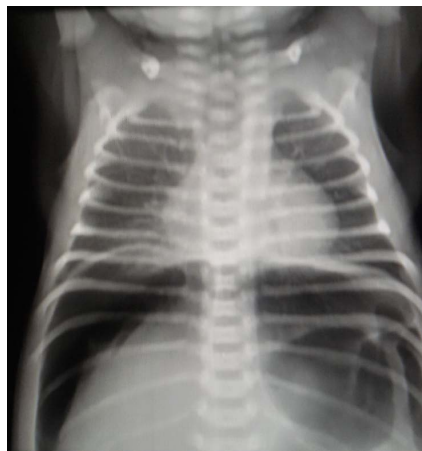


Figure 7. Air under the diaphragm from intestinal perforation.

In our study, the prominent symptoms that were associated with significant plain abdominal x-rays findings and surgical abdomen were abdominal pain and irritability, abdominal swelling, history of bilious vomiting, history of recurrent and persistent vomiting, history of inability to pass meconium and stool, passage of red currant jelly stool, intra-abdominal masses, history of swallowed foreign body and history of previous abdominal surgery. This is similar to the findings of Hampson *et al.* [18].

Physical findings that the agreed with radiological reports in diagnosing common surgical abdominal conditions in children were abdominal tenderness in the older child, abdominal distension, passage of bloody stool and blood-stained finger on digital rectal examination and hyper active bowel sounds [19].

5. Conclusion

Plain abdominal x-ray remains a useful radiological investigative tool for the diagnosis of acute surgical conditions in children.

Acknowledgements

I wish to acknowledge the contributions of Mr. Obafemi Abiodun and Dr. Kalesanwo Emmanuel.

Conflicts of Interest

The authors declare no conflicts of interest regarding the publication of this paper.

References

- [1] Rothrock, S.G., Green, S.M., Harding, M., *et al.* (1991) Plain Abdominal Radiography in the Detection of Acute Medical and Surgery Disease in Children: A Retrospective Analysis. *Pediatric Emergency Care*, **7**, 281-285. <https://doi.org/10.1097/00006565-199110000-00005>
- [2] Serah, J.M., Ramesh, S.I., Margnerite, T.P., Randolph, K.O., *et al.* (2017) Pediatric Abdominal Radiographs: Common and Less Common Errors. *American Journal of Roentgenology*, **209**, 417-429. <https://doi.org/10.2214/AJR.17.17889>
- [3] Parshotam, G., Ahmed, S. and Hollow, I. (2007) Single or Double Bubble: Sign of Trouble! Congenital Pyloric Atresia: Report of Two Cases and Review of Literature. *Journal of Paediatrics and Child Health*, **43**, 502-503. <https://doi.org/10.1111/j.1440-1754.2007.01123.x>
- [4] Prasannan, S., Zhueng, T.J. and Gul, Y.U. (2005) Diagnostic Value of Plain Abdominal Radiographs in Patients with Acute Abdominal Pain. *Asian Journal of Surgery*, **28**, 246-251. [https://doi.org/10.1016/S1015-9584\(09\)60354-7](https://doi.org/10.1016/S1015-9584(09)60354-7)
- [5] Robson, N. and Beasley, S. (2014) Role of Plain Abdominal Radiography in the Initial Investigation of Suspected Intussusception. *Journal of Paediatrics and Child Health*, **50**, 251-252. <https://doi.org/10.1111/jpc.12407>
- [6] Eklof, O. and Lette, E. (1978) Scanty Intestinal Gas in Infants and Children: Clinical Significance and Radiologic Diagnosis. *Acta Radiologica*, **19**, 259-267. <https://doi.org/10.1177/028418517801901B12>
- [7] Kellow, Z.S., MacInnes, M., Kurzenwgy, D., Rawal, S., Jaffer, R., Kovacina, B., *et al.* (2008) The Role of Abdominal Radiograph in the Evaluation of the Non-Trauma Emergency Patient. *Radiology*, **248**, 715-716. <https://doi.org/10.1148/radiol.2483071772>
- [8] Ratcliffe, J.F., Fong, S., Cheong, I. and O'Connell, P. (1992) The Plain Abdominal Film in Intussusception: The Accuracy and Incidence of Radiographic Signs. *Pediatric Radiology*, **22**, 110-111. <https://doi.org/10.1007/BF02011307>
- [9] Farrugia, M.K., Morgan, A.S., McHugh, K. and Kiely, E.M. (2003) Neonatal Ga-

- stro-Intestinal Perforation. *Archives of Disease in Childhood*, **88**, F65.
- [10] Feyler, S., Williamson, V. and King, D. (2002) Plain Abdominal Radiographs in Acute Medical Emergencies: An Abused Investigation. *Postgraduate Medical Journal*, **78**, 94-96. <https://doi.org/10.1136/pmj.78.916.94>
- [11] Hee, J.L. (2011) Plain Abdominal Radiography in Infants and Children. *Korean Journal of Pediatric Gastroenterology and Nutrition*, **14**, 130-136. <https://doi.org/10.5223/kjjpgn.2011.14.2.130>
- [12] Nilgun, E., Latife, O.Z., Meryem, K.B. and Gokhan, A. (2020) An Unexpected Image on Plain Radiograph in a Child with Abdominal Complaints: A Case Report. *Journal of Pediatric Emergency and Intensive Care Medicine*, **7**, 30-33. <https://doi.org/10.4274/cayd.galenos.2018.02486>
- [13] Roh, J.J., Thompson, J.S., Hamed, R.K. and Hodgson, P.E. (1983) Value of Pneumoperitoneum in the Diagnosis of Visceral Perforation. *The American Journal of Surgery*, **146**, 830-833. [https://doi.org/10.1016/0002-9610\(83\)90353-7](https://doi.org/10.1016/0002-9610(83)90353-7)
- [14] Seema, S. (2013) An Update on Common Gastrointestinal Emergencies. *Emergency Medicine Clinic of North America*, **31**, 775-793. <https://doi.org/10.1016/j.emc.2013.05.002>
- [15] Sargent, M.A., Babyn, P. and Alton, D.J. (1994) Plain Abdominal Radiography in Suspected Intussusception: A Reassessment. *Pediatric Radiology*, **24**, 17-20. <https://doi.org/10.1007/BF02017652>
- [16] Rothrock, S.G., Green, S.M. and Hummel, C.B. (1992) Plain Abdominal Radiography in the Detection of Major Disease in Children: A Prospective Analysis. *Annals of Emergency Medicine*, **21**, 1423-1429. [https://doi.org/10.1016/S0196-0644\(05\)80053-8](https://doi.org/10.1016/S0196-0644(05)80053-8)
- [17] Guo, W.L., Wang, J., Zhou, M., Sheng, M. and Fang, L. (2011) The Role of Plain Radiography in Assessing Intussusception with Vascular Compromise in Children. *Archives of Medical Science*, **7**, 877-881. <https://doi.org/10.5114/aoms.2011.25565>
- [18] Hampson, F. (2010) Assessment of the Acute Abdomen: Role of the Plain Abdominal Radiograph. *Reports in Medical Imaging*, **3**, 93-105. <https://doi.org/10.2147/RMI.S13837>
- [19] Robson, N. and Beasley, S. (2014) Role of Plain Abdominal Radiography in the Initial Investigation of Suspected Intussusception. *Journal of Paediatrics and Child Health*, **50**, 251-252. <https://doi.org/10.1111/jpc.12407>