

A New Classification for Retinitis Pigmentosa Including Multifocal Electroretinography to Evaluate the Disease Severity

Ayse Oner, Neslihan Sinim Kahraman

Department of Ophthalmology, Kayseri Acibadem Hospital, Kayseri, Turkey
Email: aysezoner@gmail.com, neslihansinim@gmail.com

How to cite this paper: Oner, A. and Kahraman, N.S. (2023) A New Classification for Retinitis Pigmentosa Including Multifocal Electroretinography to Evaluate the Disease Severity. *Open Journal of Ophthalmology*, 13, 37-47.
<https://doi.org/10.4236/ojoph.2023.131005>

Received: November 21, 2022

Accepted: February 7, 2023

Published: February 10, 2023

Copyright © 2023 by author(s) and Scientific Research Publishing Inc.
This work is licensed under the Creative Commons Attribution International License (CC BY 4.0).
<http://creativecommons.org/licenses/by/4.0/>



Open Access

Abstract

Aim: To establish a useful and objective classification for retinitis pigmentosa (RP) to evaluate the disease severity. **Methods:** This is a retrospective cross-sectional study. Visual acuity (VA), visual field (VF) width, ellipsoid zone width on optic coherence tomography (OCT) and multifocal electroretinography (mf ERG) values were obtained from medical records of patients with RP. A scoring criterion was developed wherein each variable was assigned a score from 0 to 5 depending on its distribution. The cumulative score (from 0 to 20) was used to classify disease severity from grade 0 to 5. The scores were correlated with each other and the final grade. **Results:** Data of 152 eyes of 92 patients who had the results of all tests were reviewed. The mean age was 41.2 years. The mean VA of the patients was 0.13 ± 0.16 Snellen lines. The majority of patients had a VA less than 20/40 (88.6%), a visual field smaller than 20° (78%), and an ellipsoid zone width smaller than 7° (84.4%). The majority of the patients (85.4%) were in advanced stage of the disease (Grade 4 and 5). **Conclusions:** We present a simple, objective and easy to use disease severity classification for RP which can be used to categorize patients and to evaluate and compare treatment results.

Keywords

Classification, Multifocal Electroretinography, Retinitis Pigmentosa, Visual Field, Visual Function

1. Introduction

Retinitis pigmentosa (RP) is a complex group of hereditary retinal disorders which causes degeneration of retinal photoreceptors. It has been reported that

the disease has a worldwide prevalence of 1/4000 and it can be inherited with different patterns. The primary pathogenesis of RP is degeneration of photoreceptors, which leads to a narrowing of visual field (VF), night blindness and deterioration of visual acuity (VA) ending with total blindness [1].

The natural history of the disease has long been studied using functional measures such as VA, VF and electrophysiological tests. Up to now, there is no definitive curative treatment for patients with RP. However, in recent years, new approaches including gene therapy and stem cell transplantation are being extensively investigated [2]. Significant advancements have been made in understanding the genetic pathogenesis of retinal diseases and the first retinal gene therapy was recently approved by Food and Drug Administration (FDA) for the treatment of RP. Numerous other gene therapy trials are underway for various forms of inherited retinal disease [3]. The other treatment option, stem cell transplantation provides trophic support for neuroprotection and regeneration of damaged retinal cells through the secretion of neurotrophic factors in retinal degenerative diseases and prevents progression [4].

To evaluate the therapeutic efficacy of these treatment options, it is important to measure the severity of the disease. Also for the clinical assessment and VA, the disease can be examined by a variety of tests like optical coherence tomography (OCT), VF and electroretinography (ERG) [5].

In a recent study [6], the researchers designed a classification based on the findings obtained from basic clinical examination and available diagnostic tests including VF and OCT. It is simple, easy to use and widely applicable to all patients. OCT is extensively used as a tool to monitor RP, since it can demonstrate outer retinal changes, particularly the changes in the ellipsoid zone (EZ), which are well correlated with functional measures [7] [8] [9]. VF most closely captures the patient's perception of visual impairment [10]; however, it is subjective and has high test-retest variability. Unfortunately, this classification does not include any electrophysiological tests which give more objective data in retinal diseases. Electrophysiological tests such as full field ERG (ffERG) and multifocal ERG (mfERG) provide an objective, functional measurement of the retinal function. They are useful in diagnosing RP and monitoring the long-term disease course for prognosis and treatment response. ffERG assesses nonselective global responses of the retina and it has not been able to reliably detect small progression, especially in the end stage of RP. Therefore, we believe that ffERG will not be a proper test for a classification system. Multifocal ERG measures the innermost 30° of the retina and greatly improves the reproducibility of functional measurements compared to VF testing. VA correlated well with the amplitude of the central segment of the mfERGs, ring 5 amplitudes of the mfERG strongly correlated with the scotopic Ganzfeld ERG mixed cone-rod response amplitude and VF area. Also in advanced cases, reliable mfERG responses could still be recorded, even if the ffERG was not reproducible. Therefore, mfERG would be a more appropriate test for an objective classification system [11] [12].

The purpose of this study was to develop a phenotypic classification for RP

which would provide a valuable and objective measure of disease severity for clinicians and researchers.

2. Methods

2.1. Study Design and Setting

This was a retrospective study conducted to establish a classification system to evaluate the severity of RP by using a phenotypic classification system. The study was performed in the ophthalmology department of a tertiary hospital between January 2019 and June 2020 in accordance with the Declaration of Helsinki, after obtaining the approval of the Ethics Committee of the University (2017/480, 13.10.2017). Written informed consent was obtained from all participants of the study.

2.2. Patients

The inclusion criteria were as follows: 1) a clinical diagnosis of RP confirmed by clinical history, fundus appearance, VF, OCT and ERG 2) subjects older than 18 years of age 3) subjects who are able to do a reliable VF evaluation

Patients with previous ocular surgery other than cataract extraction, ocular media opacities that would make the image quality insufficient for ocular imaging or effect the test results, coexisting ocular disease (e.g., retinal pathology other than RP, glaucoma, uveitis, strabismus, nystagmus), any other systemic disease (e.g., diabetes, neurological diseases, hypertension) that would have an impact on the results were excluded from the study.

After receiving a complete medical history including patient demographics, disease duration, inheritance pattern, the patients received a detailed ophthalmic examination including BCVA and intraocular pressure measurements, anterior segment evaluation with slit-lamp biomicroscopy, color fundus photography, OCT, VF and mfERG. BCVA was recorded with a Snellen chart at a distance of 3 meters. VF examination was performed by Humphrey VF analyzer device (Carl Zeiss Meditec AG Germany), program 30-2 was used for testing of each eye. Multifocal ERG was recorded on mfERG Vision monitor (Metrovision, France). The mfERG test was performed according to the International Society for Clinical Electrophysiology of Vision (ISCEV) guidelines [13]. During the mfERG evaluations, a matrix of 61 hexagons of the individual mfERG responses were generated, and these hexagons were grouped into five concentric rings (15°) centered on the fovea. We recorded the average amplitude and implicit time of the first positive wave (P1) in these five rings. In this classification system we used amplitudes of positive P1 waves of 5 rings which show a strong correlation with the other parameters according to the previous study by Nagy *et al.* [11]. Responses were analyzed according to ring averages of P1 waves and responses over 5.0 nV were recorded as detectable [14].

2.3. Severity Classification

Patients were evaluated regarding to the outcome measures of BCVA, OCT, VF

and mf ERG tests. BCVA, VF width, ellipsoid zone (EZ) width on OCT, amplitudes of P1 wave of 5 rings were recorded for each patient and a scoring criterion was established for each variable varying from 0 to 5 depending on its distribution. The cumulative score (from 0 to 20) was used to classify disease severity from grade 0 to 5 (Table 1 and Table 2). We also evaluated the mean deviation (MD) value of VF and central macular thickness (CMT) measurements on OCT for each patient.

Severity classification was done according to the system designed by Iftikhar *et al.* [9] and a modification was done for evaluating the results of mfERG. BCVA was given a score of 0 if vision was $\geq 20/20$; 1 if it was $<20/20$ to $\geq 20/25$; 2 if it was $<20/25$ to $\geq 20/32$; 3 if it was $<20/32$ to $\geq 20/40$; 4 if it was $<20/40$ to $\geq 20/100$; and 5 if it was $< 20/100$. VF diameter was given a score of 0 if it was $\geq 120^\circ$ or better; 1 if it was $<120^\circ$ to $\geq 80^\circ$; 2 if it was $<80^\circ$ to $\geq 40^\circ$; 3 if it was $<40^\circ$ to $\geq 20^\circ$; 4 if it was $<20^\circ$ to $\geq 15^\circ$; and 5 if it was $<15^\circ$. EZ was given a score of 0 if it was $\geq 30^\circ$ (occupying the whole width of the OCT scan); 1 if it was $<30^\circ$ to $\geq 15^\circ$; 2 if it was $<15^\circ$ to $\geq 10^\circ$; 3 if it was $<10^\circ$ to $\geq 7^\circ$; 4 if it was $<7^\circ$ to $\geq 5^\circ$; and 5 if it was $<5^\circ$. MfERG testing was evaluated according to the P1 wave amplitude of each ring and counted as detectable if it is bigger than 5.0 nV. The score was 0 if it was detectable in 5 rings, 1 if it was detectable in 4 rings, 2 if it was detectable in 3 rings, 3 if it was detectable in 2 rings, 4 if it was detectable in 1 ring and 5 if there is no detectable waves. Table 1 shows the scoring criteria for each variable

Table 1. Scoring criteria (6)

Score	Visual Acuity (ETDRS letter score/Snellen)	Visual Field Diameter ($^\circ$)	Elipsoid Zone Width ($^\circ$)	Mf ERG Detectable P1 wave ($>100 \mu\text{V}$)
0	≥ 85 (20/20)	≥ 120	≥ 30	5 rings
1	<85 (20/20) to ≥ 80 (20/25)	<120 to ≥ 80	<30 to ≥ 15	4 rings
2	<80 (20/25) to ≥ 75 (20/32)	<80 to ≥ 40	<15 to ≥ 10	3 rings
3	<75 (20/32) to ≥ 70 (20/40)	<40 to ≥ 20	<10 to ≥ 7	2 rings
4	<70 (20/40) to ≥ 55 (20/100)	<20 to ≥ 15	<7 to ≥ 5	1 ring
5	<55 (20/100)	< 15	< 5	0 ring

Table 2. Grading criteria (6).

Grade	Cumulative score
0	0
1	1 - 4
2	5 - 8
3	9 - 12
4	13 - 16
5	17 - 20

and **Table 2** includes the grading scale. Data of 152 eyes of 92 patients were retrospectively evaluated according to the classification system.

2.4. Statistical Analysis

Statistical analyses were conducted using SPSS version 20 statistical package program (IBM Corp. in Armonk, NY). Descriptive data are presented as median with interquartile range for non-normally distributed numerical variables, and as the frequencies and percentage for categorical variables. Shapiro-Wilk and Kolmogorov-Smirnov tests were used to evaluate the distribution of the numeric data. Pearson's Chi-Square test and One-Way ANOVA test was used for comparing the numeric data with a Scheffe test for post-hoc pairwise comparison. $p < 0.05$ was considered as statistically significant level.

3. Results

Data of 152 eyes of 92 patients who had the results of all tests were reviewed. The mean age was 41.2 (between 20 - 69) years and 54.4% of the study group were male. The mean age at onset of disease was 19.4 years and the mean disease duration was 22.3 (between 7 - 46) years. There was a family history in 56% of the patients. Among the patients with a family history autosomal dominant pattern was found in 28%, autosomal recessive pattern was found in 67% and X linked pattern was found in 5% of the patients. Demographic data of the patients were shown in **Table 3**. Genetic results for causative mutations were available for 36 (39%) patients.

The mean value of the VA of the study patients was 0.13 ± 0.16 Snellen lines. The mean CMT was $111.6 \pm 54.3 \mu\text{m}$ and the mean MD value was -27.53 ± 8.67 db. The other descriptives were shown in **Table 4**.

The majority of patients had a VA less than 20/40 (88.6%), a visual field smaller than 20° (78%), and an ellipsoid zone width smaller than 7° (84.4%).

Table 3. Demographics of the patients.

Characteristics (n = 92)	
Age (years), mean \pm SD	41.2 \pm 15.6
Sex (male), n (%)	82 (54.4)
Age of onset (years) mean \pm SD	22.3 \pm 13.1
Duration of the disease (years) mean \pm SD	18.8 \pm 11.6
Family History (+/-)	52/40
Mode of Inheritance	
Autosomal dominant (n/%)	14(28)
Autosomal recessive (n/%)	35 (67)
X-Linked (n/%)	3 (5)

SD: Standard Deviation.

Visual field diameter and ellipsoid zone width both had a strong relationship with visual acuity (**Table 5**).

The sum of all scores was used to determine the severity grade, as described in **Table 2**. **Figure 1** shows examples of different severity grades. Distribution of the grades were as follows: There were 2 eyes (1%) classified as grade 0, 4 eyes (2.6%) as grade 1, 5 eyes (3%) as grade 2, 12 eyes (8%) as grade 3, 23 eyes (15%) as grade 4 and 106 eyes (70.4%) as grade 5 (**Table 5**). The majority of the patients (85.4%) were in advanced stage of the disease (Grade 4 and 5).

OCT evaluations showed abnormalities in 7 (8%) patients. 5 had CME, 1 had ERM and 1 had VMT.

Table 4. The mean and the median value of BCVA, BCVA score, CMT, VF score, VF-MD value, mfERG score, score and grade of the disease.

	n	Mean \pm SD	Median (Min-Max)
Visual acuity (VA) (Snellen Lines)	152	0.13 \pm 0.16	0.05 (0.00 - 0.90)
VA Score	152	4.6 \pm 0.5	5.0 (1.0 - 5.0)
CMT (μ m)	152	111.6 \pm 54.3	114.5 (45.0 - 288.0)
EZ Score	152	4.3 \pm 0.6	5.0 (0.0 - 5.0)
VF Score	152	3.9 \pm 1.1	5.0 (1.0 - 5.0)
VF-MD Value (dB)	152	27.53 \pm 8.67	30.27 (6.43 - 34.60)
Mf ERG Score	152	3.6 \pm 1.0	4 (0.0 - 5.0)
Score of the disease	152	15.6 \pm 1.9	17.0 (3.0 - 20.0)
Grade of the disease	152	4.3 \pm 0.6	5.0 (1.0 - 5.0)

VA: Visual acuity; CMT: Central macular thickness; μ m: micrometer; EZ: Ellipsoid zone; VF: Visual field; VF-MD Value: Visual field mean deviation value; dB: decibel; mfERG: Multifocal electroretinography.

Table 5. Distribution of scoring of the variables and grading of the disease.

Variables	Grades					
	0	1	2	3	4	5
VA Score	0 (0%)	4 (2.4%)	5 (3%)	9 (6%)	32 (21%)	102 (67.6%)
EZ Score	2 (1%)	4 (2.6%)	6 (4%)	12 (8%)	54 (36%)	74 (48.4%)
VF Score	0 (0%)	3 (2%)	9 (6%)	22 (14%)	25 (16%)	93 (62%)
MfERG Score	6 (4%)	6 (4%)	15 (10%)	23 (15%)	41 (27%)	61 (40%)
Grade of the disease	2 (1%)	4 (2.6%)	5 (3%)	12 (8%)	23 (15%)	106 (70.4%)

VA: Visual acuity; EZ: Elipsoid zone; VF: Visual field.

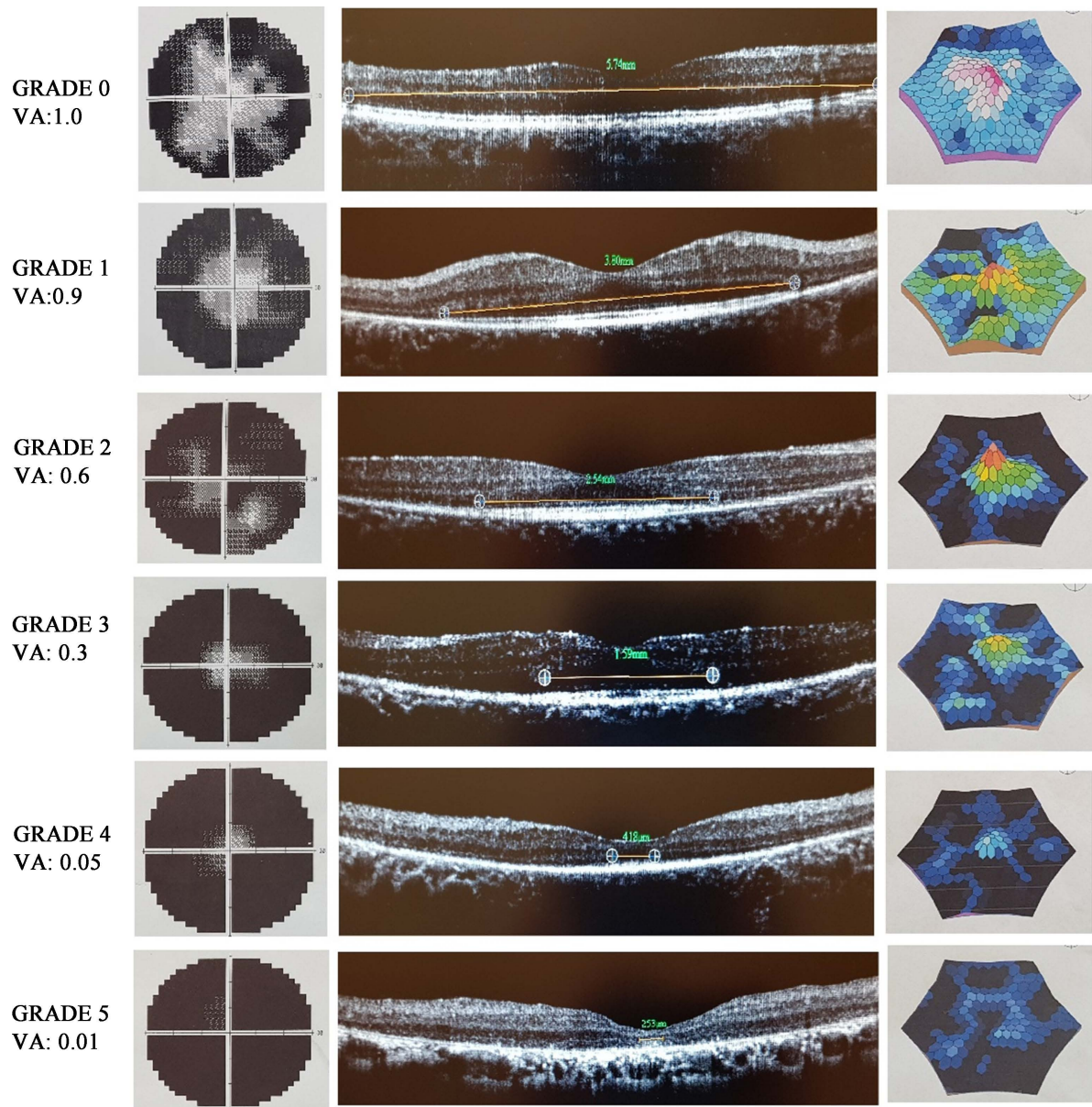


Figure 1. Classification of disease severity from grades 0 to 5 using BCVA, VF, EZ on OCT and mfERG.

The score and the severity grade of the disease correlated strongly with VA, EZ, VF and mfERG score ($p < 0.05$). The anatomical scores (EZ score and CMT) of the retina strongly correlated with the functional scores (VA, VF and mfERG score and MD) of the retina ($p < 0.05$).

4. Discussion

RP is one of the leading causes of severe visual impairment in young individuals [15]. Patients with RP often have difficulties with daily activities. Most of them have difficulties in navigation, orientation, and obstacle detection. Among different measures of visual function, VF area has been shown to be the best predictor of poor mobility in patients with RP. Humphrey VF has been shown to be

beneficial in assessing the residual central VF of patients with RP. In a large study including data of 928 RP patients [10], the researchers evaluated correlations of MDs with the visual acuity. They also evaluated potential influences of gender, age, family history and retinal pigmentation on the MD decreasing rate. They found that average VA was 0.79 ± 0.35 and average MD was -14.44 ± 8.61 dB in the study. The results showed that when MD was lower than -9.18 dB the visual acuity would be below 1.0 (20/20). The average decreasing value of MD in 10 years' period was reported as -8.01 ± 3.66 dB and the value was correlated to retinal pigmentation but not to gender, age or RP family history.

Most of the recent studies investigated the correlation of VF MD values with other clinical tests. It is known that, OCT examination has provided useful information about the pathology and the prognosis of the disease. The OCT studies showed a shortening of the EZ length and a thinning of the outer retinal layers in eyes with RP. In a study evaluating the progression of OCT findings observed progression in >75% of patients during the 2 year mean follow up and the mean annual progression rate of ellipsoid zone line was 4.9%. This study was also the first to demonstrate asymmetrical structural progression rate between right and left eye, which was found in 19% of patients [16]. A recent study analyzed data of 149 RP patients who reported VF constriction on a central 30-2 Humphrey VF chart. The authors reported that BCVA and VF showed a progressive worsening related to age and disease duration and the progression in VF significantly correlated with the decrease in CMT, EZ length, and macular volume at the central area [5]. Another study including 53 eyes of 27 patients assessed the annual progression rate of photoreceptor atrophy by measuring EZ line in OCT sections through the fovea. During the 4.84 years mean follow up time the EZ line width decreased with a yearly average rate of $76.4 \mu\text{m}$ (4.16%/year) which was in accordance with the reported rates between 4.9% - 10.9% in published literature [8] [9].

To evaluate the efficacy of new treatment options, it is important to measure the severity of the disease. To the best of our knowledge, there is only one study in the literature published by Iftikhar *et al.* including a severity classification system established with the parameters of BCVA, VF and OCT. This classification is applicable for almost all patients regardless of any variations in disease phenotype and may be useful to assess, monitor and compare disease severity in clinical health services and researches. The authors reported that almost all patients demonstrated a VF extending significantly beyond the edges of their remaining EZ [6]. This led us the opinion that the EZ probably represents organised or densely packed photoreceptors and that there may be scattered or fragmented photoreceptors beyond the edges of the EZ that are alive and functioning [6]. Although this classification is simple and easy to perform, we believe that subjective measures like visual acuity and VF may incompletely demonstrate the patient's experiences of the daily life and disease severity.

It is known that ERG is a gold standard test for evaluating RP because it is an objective and quantitative measure of global retinal function. Unfortunately, the

test is difficult and time-consuming and can be extinguished in the early stage of the disease, when the central visual acuity is still entirely preserved [11]. Because the traditional ERG does not seem to be sensitive enough to indicate the condition of the central retina, other methods have been sought. The mfERG technique, which allows a high resolution mapping of the macular area of the retina seems to be a more promising method for detection of the remaining foveal cone function which can be detectable even in advanced stage of the disease [12].

In a study by Granse *et al.* [14] researchers evaluated residual retinal function with three different electrophysiological methods (ffERG, mfERG and mfVEP) in a selected group of RP patients with a remaining small central visual fields. Although the ffERGs were severely reduced in all patients, mfERGs were detectable in most of the patients with reliable responses over 5.0 nV. The mfVEPs also showed measurable amplitudes centrally in most of the patients. These findings corresponded well with the remaining central visual fields. The authors suggested that these two electrophysiological methods, mfERG and mfVEP, might be of clinical importance for evaluating and monitoring the residual central retinal function and small remaining central visual fields in patients with RP.

In another clinical study, researchers assessed central retinal function in patients with advanced RP using the mfERG. They reported that mfERG responses were recordable in at least one area in all successfully tested patients with advanced RP and nonrecordable ffERGs [11].

To the best of our knowledge this is the first clinical study including mfERG in a classification system. We believe that including mfERG as a parameter would increase the value of the classification.

The study includes a large sample size and a wide range of patients in terms of age, sex, mode of inheritance and disease duration. We believe that this classification produces objective measure of disease severity and gives opportunity to compare the results of different treatment modalities.

5. Conclusion

In order to assess the severity of RP and compare the efficacy of new therapies, it is important to establish outcome measures that are both reliable and easy to evaluate. We believe that this classification is simple, produces objective data about disease severity and gives opportunity to compare the results of different treatment modalities.

Acknowledgements

We would like to thank Prof. Dr Osman Gunay for the statistical analysis. We also thank to the staff members of Acibadem Kayseri Hospital for their contribution to the study tests.

Funding

This research did not receive any specific grant from funding agencies in the

public, commercial or not-for-profit sectors.

Authors' Contributions

AO: Study design, data collection, manuscript preparation.

NSK: Data collection, manuscript preparation.

All authors read and approved the manuscript.

Ethics Approval and Consent to Participate

The study was performed in accordance with the Declaration of Helsinki, after obtaining the approval of the Ethics Committee of the University (2017/480, 13.10.2017).

Conflicts of Interest

The authors declare no conflicts of interest regarding the publication of this paper.

References

- [1] Hartong, D.T., Berson, E.L. and Dryja, T.P. (2006) Retinitis Pigmentosa. *The Lancet*, **368**, 1795-1809. [https://doi.org/10.1016/S0140-6736\(06\)69740-7](https://doi.org/10.1016/S0140-6736(06)69740-7)
- [2] Oner, A. (2018) Stem Cell Treatment in Retinal Diseases: Recent Developments. *Turkish Journal of Ophthalmology*, **48**, 33-38. <https://doi.org/10.4274/tjo.89972>
- [3] Russell, S., Bennett, J., Wellman, J.A., *et al.* (2017) Efficacy and Safety of Voretigene Neparvovec (AAV2-hRPE65v2) in Patients with RPE65-Mediated Inherited Retinal Dystrophy: A Randomised, Controlled, Open-Label, Phase 3 Trial. *The Lancet*, **390**, 849-860. [https://doi.org/10.1016/S0140-6736\(17\)31868-8](https://doi.org/10.1016/S0140-6736(17)31868-8)
- [4] Kahraman, N.S. and Oner, A. (2020) Umbilical Cord Derived Mesenchymal Stem Cell Implantation in Patients with Retinitis Pigmentosa: 6-Month Follow-Up Results of a Phase 3 Trial. *IJO*, **13**, 1423-1429. <https://doi.org/10.18240/ijo.2020.09.14>
- [5] Son, G., Lee, S., Kim, Y.J., *et al.* (2019) Correlation between Visual Function and Structural Characteristics of the Macula in Advanced Retinitis Pigmentosa. *Ophthalmologica*, **242**, 22-30. <https://doi.org/10.1159/000496941>
- [6] Iftikhar, M., Lemus, M., Usmani, B., *et al.* (2018) Classification of Disease Severity in Retinitis Pigmentosa. *British Journal of Ophthalmology*, **103**, 1595-1599. <https://doi.org/10.1136/bjophthalmol-2018-313669>
- [7] Sayo, A., Ueno, S., Kominami, T., *et al.* (2018) Significant Relationship of Visual Field Sensitivity in Central 10° to Thickness of Retinal Layers in Retinitis Pigmentosa. *Investigative Ophthalmology & Visual Science*, **59**, 3469-3475. <https://doi.org/10.1167/iovs.18-24635>
- [8] Colombo, L., Montesano, G., Sala, B., *et al.* (2018) Comparison of 5-Year Progression of Retinitis Pigmentosa Involving the Posterior Pole among Siblings by Means of SD-OCT: A Retrospective Study. *BMC Ophthalmology*, **18**, 153. <https://doi.org/10.1186/s12886-018-0817-z>
- [9] Miyata, M., Ogino, K., Gotoh, N., *et al.* (2016) Inner Segment Ellipsoid Band Length Is a Prognostic Factor in Retinitis Pigmentosa Associated with EYS Mutations: 5-Year Observation of Retinal Structure. *Eye*, **30**, 1588-1592. <https://doi.org/10.1038/eye.2016.196>

- [10] Ye, H. and Xia, X.P. (2018) Visual Field Mean Deviation and Relevant Factors in 928 Chinese Retinitis Pigmentosa Patients. *International Journal of Ophthalmology*, **11**, 1978-1983. <https://doi.org/10.18240/ijo.2019.12.22>
- [11] Gerth, C., Wright, T., Héon, E. and Westall, C.A. (2007) Assessment of Central Retinal Function in Patients with Advanced Retinitis Pigmentosa. *Investigative Ophthalmology and Visual Science*, **48**, 1312-1318. <https://doi.org/10.1167/iovs.06-0630>
- [12] Janáky, M., Pálffy, A., Deák, A., Szilágyi, M. and Benedek, G. (2007) Multifocal ERG Reveals Several Patterns of Cone Degeneration in Retinitis Pigmentosa with Concentric Narrowing of the Visual Field. *Investigative Ophthalmology & Visual Science*, **48**, 383-389. <https://doi.org/10.1167/iovs.06-0661>
- [13] Hood, D.C., Bach, M., Brigell, M., *et al.* (2012) International Society for Clinical Electrophysiology of Vision. ISCEV Standard for Clinical Multifocal Electroretinography (mfERG) (2011 Edition). *Documenta Ophthalmologica*, **124**, 1-13. <https://doi.org/10.1007/s10633-011-9296-8>
- [14] Gränse, L., Ponjavic, V. and Andréasson, S. (2004) Full-Field ERG, Multifocal ERG and Multifocal VEP in Patients with Retinitis Pigmentosa and Residual Central Visual Fields. *Acta Ophthalmologica Scandinavica*, **82**, 701-706. <https://doi.org/10.1111/j.1600-0420.2004.00362.x>
- [15] Kahraman, N.S., Sevim, D.G. and Öner, A. (2019) Cross-Validation of the Turkish Version of the 28-Item Impact of Vision Impairment Profile Test. *Open Journal of Ophthalmology*, **4**, 194. <https://doi.org/10.4236/ojoph.2019.94021>
- [16] Sujirakul, T., *et al.* (2015) Multimodal Imaging of Central Retinal Disease Progression in a 2 Year Mean Follow Up of Retinitis Pigmentosa. *American Journal of Ophthalmology*, **160**, 786-798.e4.