

Dynamic External Fixator Combined with Volar Locking Plate Fixation for the Treatment of AO Type C3 Distal Radius Fractures

Kinya Nishida, Yong Ho Che, Hideto Irifune, Kazuhiro Uesugi, Akane Maeda, Koji Miyata

Department of Orthopaedic Surgery, Teine Keijinkai Hospital, Sapporo, Japan

Email: nishikin@par.odn.ne.jp

How to cite this paper: Nishida, K., Che, Y.H., Irifune, H., Uesugi, K., Maeda, A. and Miyata, K. (2022) Dynamic External Fixator Combined with Volar Locking Plate Fixation for the Treatment of AO Type C3 Distal Radius Fractures. *Open Journal of Orthopedics*, 12, 131-141.

<https://doi.org/10.4236/ojo.2022.124014>

Received: March 7, 2022

Accepted: April 9, 2022

Published: April 12, 2022

Copyright © 2022 by author(s) and Scientific Research Publishing Inc. This work is licensed under the Creative Commons Attribution International License (CC BY 4.0).

<http://creativecommons.org/licenses/by/4.0/>



Open Access

Abstract

Background: AO type C3 distal radius fracture (DRF) is the most difficult-to-treat fracture type because of a tendency to shorten and collapse. The purpose of this study is to investigate the clinical and radiographic outcomes of comminuted intra-articular DRFs treated with a dynamic external fixator combined with a volar locking plate (VLP). **Methods:** Eleven patients (mean age, 61 years) with comminuted intra-articular DRFs were treated with a dynamic type of external fixator combined with a VLP. Following reduction and fixation with a VLP, the dynamic external fixator was applied and the distal ball joint of the fixator was aligned with the lunate-capitate line. The ball joint was unlocked approximately 2 weeks after surgery to allow wrist mobilization. The fixator was removed 3 - 6 weeks (mean, 5 weeks) after surgery. Consequently, clinical and radiographic assessments were carried out at the final follow-up. **Results:** At the final follow-up, the mean range values of wrist extension and flexion were 76° and 64°, respectively. Compared with the contralateral side, the mean grip strength was 84%. The mean Modified Mayo Wrist Score and the Disabilities of the Arm, Shoulder and Hand score were 88 and 9, respectively. No significant differences in the radiographic parameters exist between after surgery and final follow-up. **Conclusions:** This study indicated that the dynamic wrist fixator combined with a VLP is effective for the treatment of AO type C3 DRFs.

Keywords

Distal Radius Fracture, Intra-Articular Fracture, External Fixator, Dynamic External Fixator, Volar Locking Plate

1. Introduction

Distal radius fracture (DRF) is the most common fracture of the upper extremity

with high prevalence rates reported worldwide [1] [2] [3]. Traditionally, DRFs were treated conservatively with closed reduction and casting [4]. However, recent reports describe an increasing trend toward surgical treatment including external fixation (EF), percutaneous pinning, and open reduction and internal fixation [5] [6]. An increase in the use of internal fixation for DRF treatment has been noted since the introduction of the volar locking plate (VLP) system in 2000 [1].

AO type C3 DRF is the most difficult fracture type to maintain reduction and fixation because it tends to shorten and collapse [7] [8]. Some of the unstable AO type C3 DRFs cannot be treated with a single-plate system although fixation of the DRF with a VLP provides sufficient stability with minimal reduction loss [9] [10].

The transarticular external fixator, based on ligamentotaxis, is a versatile and useful option for complex DRF treatment [11]. In 1993, Pennig introduced the dynamic transarticular external fixator, which has a double-ball joint to permit a substantial degree of freedom and wrist mobilization after unlocking one ball joint [12] [13] [14].

Although there have been some reports that describe external fixator combined with percutaneous Kirschner wires or fragment-specific fixation for the treatment of DRFs [15] [16] [17], few reports are available on a combination of external fixator and VLP.

The purpose of this study is to evaluate the clinical and radiographic outcomes of AO type C3 DRFs treated with a transarticular dynamic external fixator combined with a VLP.

2. Methods

This study was approved by the medical research ethics committee at Teine Keijinkai Hospital.

2.1. Patient Demographics

The senior author treated 11 consecutive patients (four males and seven females) with comminuted intra-articular fractures of the distal radius (AO type C3 DRFs) with the use of a transarticular dynamic-type external fixator combined with a VLP at Teine Keijinkai Hospital between 2014 and 2017. Their mean age at the time of surgery was 61 years (range, 31 - 85 years). The mechanism of injury included falling from standing (seven patients), falling from height (two patients), and a motor vehicle accident (two patients; **Table 1**). Selection criteria included 1) osteoporotic AO type C3 DRFs that were judged inadequate to be treated with a single-plate system, or 2) unstable AO type C3 DRFs that were caused by high-energy injuries and estimated to be difficult to maintain the length of the radius.

2.2. Surgical Technique

All operations were performed with the patients being under general anesthesia.

Table 1. Patient and injury characteristics.

Male/female	4/7
Mean age (range)	61 years (range, 31 - 85 years)
Injury mechanism	
Falling from standing	7
Falling from height	2
Motor vehicle accident	2

After a pneumatic tourniquet was applied, a small incision was made distal to the base of the second metacarpal bone, and a bone screw was inserted into the bone from the radial side. Another small incision was made 15 mm distal to the first incision, and the second bone screw was inserted using a guide sleeve in the same manner. An approximately 3 cm longitudinal incision was made to insert bone screws to the shaft of the radius from the radial side. Moreover, the periosteum was elevated, and two bone screws were inserted using a guide sleeve with the extensor carpi radialis longus tendon retracted dorsally and the brachioradialis muscle to the palmar side. These screws should be at a minimum distance of 3 - 4 cm from the most proximal fracture line. An approximately 5 cm longitudinal incision along the flexor carpi radialis (FCR) tendon was then made at the palmar side of the distal forearm, and the FCR tendon and median nerve were retracted to the ulnar side. The pronator quadratus was exposed and detached from its radial side to provide good exposure of the palmar side of the fractured distal radius. Consequently, the fracture was fixed with the VLP after satisfactory reduction was obtained. The external fixator could be applied for the distal radius distraction during the reduction and fixation of the fracture. After wound closure, the external fixator was applied from the radial side, and the distal ball joint of the fixator was aligned with the lunate-capitate line (so-called center of rotation of the wrist) to allow extension-flexion exercise after the unlocking of the joint (**Figure 1**). The ball joints of the fixator were locked for approximately 2 weeks postoperatively.

Additional splinting was not provided, and physical therapy was started on the first postoperative day by hand therapists. The distal ball joint of the fixator was unlocked, and wrist joint exercise using the transarticular fixator was allowed. The fixator was removed 3 - 6 weeks (mean, 5 weeks) after surgery.

2.3. Outcome Assessment

The range of motion (ROM) of wrist extension and flexion was measured with a goniometer, and forearm pronation and supination were measured with 90° elbow flexion. Grip strength was measured with a Smedley Hand Dynamometer (MIS, Tokyo, Japan). ROM and grip strength were also calculated as percentages of the values on the contralateral uninjured side because these ratios were more sensitive for detecting clinical changes [18]. Clinical and functional outcomes

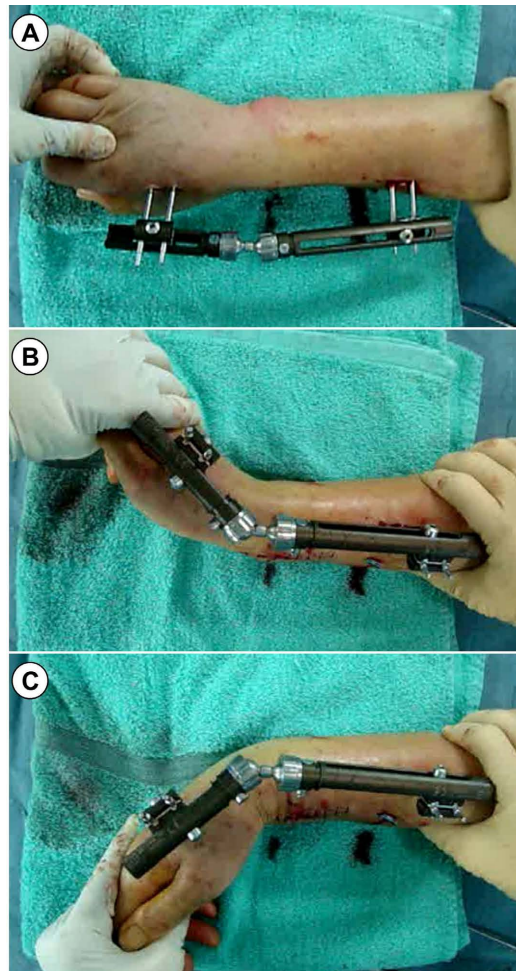


Figure 1. (A) The external fixator was applied from the radial side, and the distal ball joint of the fixator was aligned with the lunate-capitate line. (B), (C) After extension-flexion movements were confirmed, the ball joints of the fixator were locked for approximately 2 weeks postoperatively.

were quantitatively evaluated with the Modified Mayo Wrist Score (MMWS) [19] for each patient at follow-up. The Japanese Society for Surgery of the Hand version of the Disabilities of the Arm, Shoulder and Hand (DASH) questionnaire [20] served to assess each patient's subjective outcomes at follow-up. This is a 1 - 5 scoring system in which the results are transformed into a 0 - 100 scale, with a higher score indicating a greater disability.

Plain anteroposterior and lateral wrist radiographs were used for radiographic assessment, which includes the ulnar variance and radial inclination (anteroposterior view) and the palmar tilt (lateral view). All measurements were made by the senior author.

2.4. Statistical Analysis

All data are represented as mean \pm standard deviation. Statistical comparisons

were performed using a paired *t*-test. The level of significance was set at $p < 0.05$.

3. Results

The injury resulted from a lower-energy mechanism in seven female patients (mean age, 70 years) with osteoporotic bone. The injury resulted from a high-energy mechanism in four male patients (mean age, 45 years) and two patients had other fractures, including bilateral elbow fracture dislocation in one patient, lumbar fracture in the other patient, rib fractures in two patients. All fractures were completely healed without any major complications (**Figure 2**). After a mean

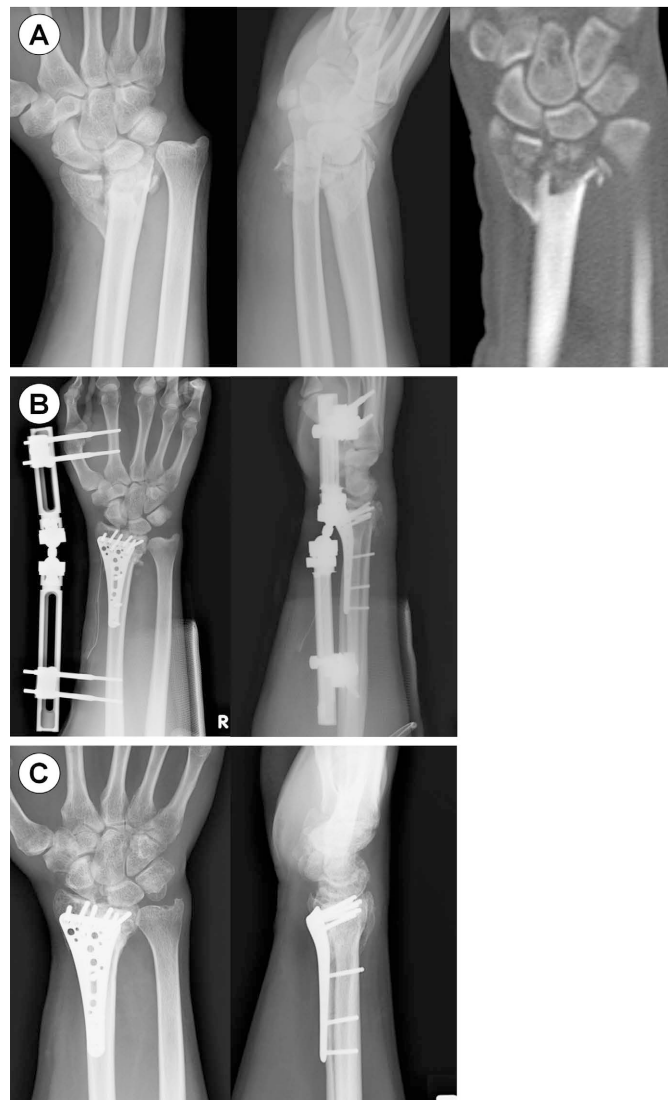

Figure 2. (A) A 31-year-old male fell from height and preoperative X-ray and CT showed AO type C3 distal radius fracture. (B) He was treated with the use of a transarticular dynamic-type external fixator combined with a volar locking plate. Note that the distal ball joint of the fixator is aligned with the lunate-capitate line. (C) At 6 months postoperatively, the collapse and redisplacement of the fracture were prevented.

follow-up of 19 months (range, 6 - 38 months), the mean ROM of wrist extension and flexion were 76° and 64°, which were 93% and 81% of the values on the contralateral side, respectively. Moreover, forearm pronation and supination were 78° and 84°, which were both 94% of the values on the contralateral side. The mean grip strength was 22 kg, which was 84% of the value on the contralateral side. The mean MMWS and DASH score were 88 and 9, respectively (**Table 2**).

The radiographic parameters are shown in **Table 3**. At the final follow-up, the mean positive ulnar variance, palmar tilt, and radial inclination were 0.8 mm, 6.1°, and 19.9°, respectively. No significant differences exist in these radiographic parameters between after surgery and the final follow-up, which indicated that the collapse and redisplacement of the fracture were prevented.

4. Discussion

The results of the current study show that the dynamic external fixator combined with a VLP is a good option for the treatment of AO type C3 DRF, which is one of the most difficult fracture types to maintain the length of the radius and distal articular surface congruity because of a tendency to shorten and collapse [7] [8]. The external fixator was used as a static fixator for approximately 2 weeks postoperatively. After unlocking the distal ball joint that is in line with the

Table 2. Clinical and functional outcomes.

	Mean	% of the contralateral side
Range of motion (°)		
Extension	76 ± 9	93 ± 10
Flexion	64 ± 15	81 ± 19
Pronation	78 ± 11	94 ± 9
Supination	84 ± 6	94 ± 7
Grip strength (kg)	22 ± 13	84 ± 14
MMWS	88 ± 9	
DASH score	9 ± 10	

MMWS: Modified Mayo Wrist Score, DASH: Disabilities of the Arm, Shoulder and Hand. Values are presented as mean ± standard deviation.

Table 3. Radiographic parameters.

	After surgery	Final follow-up	<i>p</i> -value
Ulnar variance (mm)	0.7 ± 2.3	0.8 ± 2.3	0.333
Palmar tilt (°)	7.3 ± 7.6	6.1 ± 7.0	0.401
Radial inclination (°)	19.2 ± 3.7	20.4 ± 3.8	0.084

Values are presented as mean ± standard deviation. No significant differences exist in these radiographic parameters between after surgery and the final follow-up.

center of rotation of the wrist (lunate-capitate joint line), wrist joint mobilization could be carried out without the axial force to the articular surface of the distal radius.

Some of the comminuted and unstable DRFs cannot be treated with a single-plate system although DRF fixation with a VLP has been popular in the past decades [9] [10]. However, early mobilization of the wrist could result in redisplacement of the fixed fragments and collapse of the joint if fragments are still unstable with a VLP. However, longer cast immobilization duration results in post-traumatic stiffness of the wrist joint, especially with significant intra-articular damage [21] [22].

Several reports exist describing the treatment of the comminuted DRFs with various treatment methods. In 2005, Ruch *et al.* introduced the distraction plate for DRFs with metaphyseal and diaphyseal comminution [23]. This study initiated wrist motion after plate removal at an average of 124 days following application. In addition, flexion and extension averaged 57° and 65° at 1 year, respectively. Richard *et al.* applied a similar technique for comminuted DRFs in the elderly and reported that the range of wrist extension and flexion was 50° and 46°, respectively, at the time of the final follow-up [24]. In addition, they also found digital stiffness in 10 of 33 patients and acknowledged the possibility of overdistraction during plate placement. Although identifying the cause of their stiffness is difficult, the longer duration of the immobilization by the plate fixation could be a potential risk for stiffness. Benson *et al.* treated 85 unstable intra-articular DRFs with fragment-specific fixation and reported that extension and flexion of the injured wrist averaged 69° and 60°, respectively, and DASH scores averaged 9 [25]. However, hardware removal was required in five cases at an average of 15 weeks after surgery because of irritation of the skin or first extensor tendon compartment at the radial styloid area. Additionally, 10 patients complained of radial sensory numbness or paresthesia around the hardware. Konrath and Bahler also reported good results in fragment-specific fixation for unstable DRFs. Moreover, 32% and 20% of the patients experienced sensory disturbances in the distribution of the superficial branch of the radial nerve and required repeat surgery, respectively [26].

EF has been extensively used for treating certain types of unstable DRFs [11] [15] [16]. However, Arora and Malik concluded that although EF is reliable in maintaining the reduction, it is inadequate in restoring articular congruity in 27 cases of comminuted, displaced intra-articular DRFs treated with an external fixator [27]. Percutaneous Kirschner wires and EF are other options for DRFs. In a study of 70 cases of DRFs treated with a spanning external fixator and percutaneous Kirschner wire pinning, Dicipinigaitis *et al.* found a reduction loss of volar tilt for a period of up to 6 months after fixation [17]. Thus, Slutsky recommended a joint-bridging external fixator in combination with fragment-specific fixation when central comminution is noted to help unload the articular fragments [16].

In 1993, Pennig introduced the dynamic transarticular external fixator, which has a double-ball joint to permit a substantial degree of freedom and wrist mobilization after unlocking one ball joint [12] [13] [14]. While unlocking the distal fixator ball joint, which is aligned with the so-called center of rotation of the wrist (lunate-capitate joint line), the wrist joint is allowed to move with minimal risk of collapse. This was based on the report that described the center of rotation of the wrist during extension-flexion as being close to the proximal cortex of the capitate [28]. Recently, it has been revealed that wrist motion is a combination of wrist flexion/extension and radial/ulnar deviation, colloquially referred to as the dart thrower's motion [29]. Although the ball joint does not exactly simulate the correct functional wrist motion, it could allow the wrist joint to move with minimal risk of collapse.

In this study, EF was used as a static fixator for approximately 2 weeks after surgery and as a dynamic fixator after unlocking the distal ball joint to permit appropriate wrist motion under the traction force. At the final follow-up, the radiographic parameters were not lost, and the ranges of motion of the wrist and forearm were good. Thus, the traction force prevented the collapse of the distal radial articular surface and joint stiffness despite the early active and passive movements.

The limitations of this study include the small number of patients, the retrospective design, and the lack of a control group. A randomized, prospective study of a group treated with the present technique and a control group treated with a VLP alone would be needed. Another limitation of this study is that evaluation bias is possible because the senior author was responsible for all clinical and radiographic measurements.

5. Conclusion

AO type C3 DRF is the most difficult-to-treat fracture type. Although DRF fixation with a VLP provides sufficient stability with minimal reduction loss, some of the unstable AO type C3 DRFs cannot be treated with a single-plate system. The current study indicated that the dynamic wrist fixator combined with a VLP is an effective and good option for the treatment of AO type C3 DRFs. Further prospective randomized studies are needed to provide more evidence of the effectiveness of the dynamic external fixator in combination with a VLP for DRF treatment.

Acknowledgements

The authors would like to thank MARUZEN-YUSHODO Co., Ltd. (<https://kw.maruzen.co.jp/kousei-honyaku/>) for the English language editing.

Conflicts of Interest

The authors declare no conflicts of interest regarding the publication of this paper.

References

- [1] Chung, K.C., Shauver, M.J. and Birkmeyer, J.D. (2009) Trends in the United States in the Treatment of Distal Radial Fractures in the Elderly. *The Journal of Bone & Joint Surgery*, **91**, 1868-1873. <https://doi.org/10.2106/JBJS.H.01297>
- [2] Sakuma, M., Endo, N., Oinuma, T., Miyasaka, D., Oguma, Y., Imao, K., et al. (2014) Incidence of Osteoporotic Fractures in Sado, Japan in 2010. *Journal of Bone and Mineral Metabolism*, **32**, 200-205. <https://doi.org/10.1007/s00774-013-0486-1>
- [3] Hagino, H., Yamamoto, K., Ohshiro, H., Nakamura, T., Kishimoto, H. and Nose, T. (1999) Changing Incidence of Hip, Distal Radius, and Proximal Humerus Fractures in Tottori Prefecture, Japan. *Bone*, **24**, 265-270. [https://doi.org/10.1016/s8756-3282\(98\)00175-6](https://doi.org/10.1016/s8756-3282(98)00175-6)
- [4] Shauver, M.J., Yin, H., Banerjee, M. and Chung, K.C. (2011) Current and Future National Costs to Medicare for the Treatment of Distal Radius Fracture in the Elderly. *The Journal of Hand Surgery*, **36**, 1282-1287. <https://doi.org/10.1016/j.jhsa.2011.05.017>
- [5] Wei, D.H., Raizman, N.M., Bottino, C.J., Jobin, C.M., Strauch, R.J. and Rosenwasser, M.P. (2009) Unstable Distal Radial Fractures Treated with External Fixation, a Radial Column Plate, or a Volar Plate: A Prospective Randomized Trial. *The Journal of Bone & Joint Surgery*, **91**, 1568-1577. <https://doi.org/10.2106/JBJS.H.00722>
- [6] Mattila, V.M., Huttunen, T.T., Sillanpaa, P., Niemi, S., Pihlajamaki, H. and Kannus, P. (2011) Significant Change in the Surgical Treatment of Distal Radius Fractures: A Nationwide Study between 1998 and 2008 in Finland. *The Journal of Trauma*, **71**, 939-943. <https://doi.org/10.1097/TA.0b013e3182231af9>
- [7] Del Pinal, F., Klausmeyer, M., Moraleda, E., de Piero, G.H. and Ruas, J.S. (2014) Arthroscopic Reduction of Comminuted Intra-Articular Distal Radius Fractures with Diaphyseal-Metaphyseal Comminution. *The Journal of Hand Surgery*, **39**, 835-843. <https://doi.org/10.1016/j.jhsa.2014.02.013>
- [8] Kamei, S., Osada, D., Tamai, K., Kato, N., Takai, M., Kameda, M., et al. (2010) Stability of Volar Locking Plate Systems for AO Type C3 Fractures of the Distal Radius: Biomechanical Study in a Cadaveric Model. *Journal of Orthopaedic Science*, **15**, 357-364. <https://doi.org/10.1007/s00776-010-1466-0>
- [9] Arora, R., Lutz, M., Hennerbichler, A., Krappinger, D., Espen, D. and Gabl, M. (2007) Complications Following Internal Fixation of Unstable Distal Radius Fracture with a Palmar Locking-Plate. *Journal of Orthopaedic Trauma*, **21**, 316-322. <https://doi.org/10.1097/BOT.0b013e318059b993>
- [10] Foo, T.L., Gan, A.W., Soh, T. and Chew, W.Y. (2013) Mechanical Failure of the Distal Radius Volar Locking Plate. *Journal of Orthopaedic Surgery*, **21**, 332-336. <https://doi.org/10.1177/230949901302100314>
- [11] Hove, L.M., Krukhaug, Y., Revheim, K., Helland, P. and Finsen, V. (2010) Dynamic Compared with Static External Fixation of Unstable Fractures of the Distal Part of the Radius: A Prospective, Randomized Multicenter Study. *The Journal of Bone & Joint Surgery*, **92**, 1687-1696. <https://doi.org/10.2106/JBJS.H.01236>
- [12] Pennig, D. and Gausepohl, T. (1996) External Fixation of the Wrist. *Injury*, **27**, 1-15. [https://doi.org/10.1016/0020-1383\(95\)00149-2](https://doi.org/10.1016/0020-1383(95)00149-2)
- [13] Pennig, D. and Gausepohl, T. (1999) External Fixation in the Distal Forearm: Its Use in Fractures and Malunions. *Journal of Orthopaedic Science*, **4**, 142-158. <https://doi.org/10.1007/s007760050086>
- [14] Pennig, D.W. (1993) Dynamic External Fixation of Distal Radius Fractures. *Hand*

- Clinics*, **9**, 587-602. [https://doi.org/10.1016/S0749-0712\(21\)01010-6](https://doi.org/10.1016/S0749-0712(21)01010-6)
- [15] Leung, F., Tu, Y.K., Chew, W.Y. and Chow, S.P. (2008) Comparison of External and Percutaneous Pin Fixation with Plate Fixation for Intra-Articular Distal Radial Fractures: A Randomized Study. *The Journal of Bone & Joint Surgery*, **90**, 16-22. <https://doi.org/10.2106/JBJS.F.01581>
- [16] Slutsky, D.J. (2007) External Fixation of Distal Radius Fractures. *The Journal of Hand Surgery*, **32**, 1624-1637. <https://doi.org/10.1016/j.jhsa.2007.09.009>
- [17] Dicipinigaitis, P., Wolinsky, P., Hiebert, R., Egol, K., Koval, K. and Tejwani, N. (2004) Can External Fixation Maintain Reduction after Distal Radius Fractures? *The Journal of Trauma*, **57**, 845-850. <https://doi.org/10.1097/01.ta.0000106290.49252.20>
- [18] MacDermid, J.C., Richards, R.S., Donner, A., Bellamy, N. and Roth, J.H. (2000) Responsiveness of the Short Form-36, Disability of the Arm, Shoulder, and Hand Questionnaire, Patient-Rated Wrist Evaluation, and Physical Impairment Measurements in Evaluating Recovery after a Distal Radius Fracture. *The Journal of Hand Surgery*, **25**, 330-340. <https://doi.org/10.1053/jhsu.2000.jhsu25a0330>
- [19] Carter, P.B. and Stuart, P.R. (2000) The Sauve-Kapandji Procedure for Post-Traumatic Disorders of the Distal Radio-Ulnar Joint. *The Journal of Bone & Joint Surgery*, **82**, 1013-1018. <https://doi.org/10.1302/0301-620x.82b7.10674>
- [20] Imaeda, T., Toh, S., Nakao, Y., Nishida, J., Hirata, H., Ijichi, M., et al. (2005) Validation of the Japanese Society for Surgery of the Hand version of the Disability of the Arm, Shoulder, and Hand Questionnaire. *Journal of Orthopaedic Science*, **10**, 353-359. <https://doi.org/10.1007/s00776-005-0917-5>
- [21] Dias, J.J., Wray, C.C., Jones, J.M. and Gregg, P.J. (1987) The Value of Early Mobilisation in the Treatment of Colles' Fractures. *The Journal of Bone & Joint Surgery*, **69**, 463-467. <https://doi.org/10.1302/0301-620X.69B3.3584203>
- [22] McAuliffe, T.B., Hilliar, K.M., Coates, C.J. and Grange, W.J. (1987) Early Mobilisation of Colles' Fractures. A Prospective Trial. *The Journal of Bone & Joint Surgery*, **69**, 727-729. <https://doi.org/10.1302/0301-620X.69B5.3316238>
- [23] Ruch, D.S., Ginn, T.A., Yang, C.C., Smith, B.P., Rushing, J. and Hanel, D.P. (2005) Use of a Distraction Plate for Distal Radial Fractures with Metaphyseal and Diaphyseal Comminution. *The Journal of Bone & Joint Surgery*, **87**, 945-954. <https://doi.org/10.2106/JBJS.D.02164>
- [24] Richard, M.J., Katolik, L.I., Hanel, D.P., Wartinbee, D.A. and Ruch, D.S. (2012) Distraction Plating for the Treatment of Highly Comminuted Distal Radius Fractures in Elderly Patients. *The Journal of Hand Surgery*, **37**, 948-956. <https://doi.org/10.1016/j.jhsa.2012.02.034>
- [25] Benson, L.S., Minihane, K.P., Stern, L.D., Eller, E. and Seshadri, R. (2006) The Outcome of Intra-Articular Distal Radius Fractures Treated with Fragment-Specific Fixation. *The Journal of Hand Surgery*, **31**, 1333-1339. <https://doi.org/10.1016/j.jhsa.2006.07.004>
- [26] Konrath, G.A. and Bahler, S. (2002) Open Reduction and Internal Fixation of Unstable Distal Radius Fractures: Results Using the Trimed Fixation System. *Journal of Orthopaedic Trauma*, **16**, 578-585. <https://doi.org/10.1097/00005131-200209000-00007>
- [27] Arora, J. and Malik, A.C. (2005) External Fixation in Comminuted, Displaced Intra-Articular Fractures of the Distal Radius: Is It Sufficient? *Archives of Orthopaedic and Trauma Surgery*, **125**, 536-540. <https://doi.org/10.1007/s00402-005-0033-1>
- [28] Youm, Y., McMurthy, R.Y., Flatt, A.E. and Gillespie, T.E. (1978) Kinematics of the Wrist. I. An Experimental Study of Radial-Ulnar Deviation and Flexion-Extension.

The Journal of Bone & Joint Surgery, **60**, 423-431.

<https://doi.org/10.2106/00004623-197860040-00001>

- [29] Palmer, A.K., Werner, F.W., Murphy, D. and Glisson, R. (1985) Functional Wrist Motion: A Biomechanical Study. *The Journal of Hand Surgery*, **10**, 39-46.

[https://doi.org/10.1016/s0363-5023\(85\)80246-x](https://doi.org/10.1016/s0363-5023(85)80246-x)