

Paraspinal Intramuscular Schwannoma: Case Presentation and Literature Review of a Rare Pathology

Daniele Valsecchi¹, Julien Galley², Simone Verzellotti¹, Alexandre Dontschev³, Pablo Mondragon⁴, Philippe Otten¹, Gianluca Maestretti¹

¹Neuro-Spinal Unit, Department of Orthopedic Surgery and Traumatology, Hôpital Fribourgeois—HFR, University of Fribourg, Fribourg, Switzerland

²Department of Radiology, Hôpital Fribourgeois—HFR, University of Fribourg, Fribourg, Switzerland

³Faculty of Science and Medicine, University of Fribourg, Fribourg, Switzerland

⁴Chronic Pain Unit, Department of Anesthesiology, Hôpital Fribourgeois—HFR, University of Fribourg, Fribourg, Switzerland
Email: daniele.valsecchi.85@gmail.com

How to cite this paper: Valsecchi, D., Galley, J., Verzellotti, S., Dontschev, A., Mondragon, P., Otten, P. and Maestretti, G. (2022) Paraspinal Intramuscular Schwannoma: Case Presentation and Literature Review of a Rare Pathology. *Open Journal of Modern Neurosurgery*, 12, 117-126.
<https://doi.org/10.4236/ojmn.2022.123012>

Received: April 8, 2022

Accepted: June 13, 2022

Published: June 16, 2022

Copyright © 2022 by author(s) and Scientific Research Publishing Inc. This work is licensed under the Creative Commons Attribution International License (CC BY 4.0).

<http://creativecommons.org/licenses/by/4.0/>



Open Access

Abstract

Background: A pure intramuscular paraspinal schwannoma is extremely rare, with only few case reports in the literature. Due to low frequency, lack of specific clinical signs and symptoms and difficult radiological assessment, the pre-surgical workup leads to a broad differential diagnosis. The aim of the work carried out was therefore to search for evidence of common clinical and radiological signs of the intramuscular paraspinal schwannoma, useful in the diagnostic work-up, and to highlight possible standards of treatment. **Methods:** Starting from the analysis of our case, we have extended a search to similar cases on the databases PubMed and Google Scholar. The outcome of the analysis gathered, up to August 2021, six relevant papers. **Result:** We treated a 69-year-old female with a thoracic intramuscular paraspinal mass. The pre-operative MRI had identified two typical signs of schwannoma (“split-fat” sign and the “entry-exit” sign). Intraoperative nerve isolation was performed and complete surgical excision was achieved. At the pathological analysis, we could confirm a rare OMS grade I “ancient schwannoma”. The analysis of the literature data showed a homogeneous picture of radiological presentation of the pathology. Moreover, surgical treatment was always the treatment of choice. **Conclusions:** The proposed assessment and treatment were consistent with the standard collected in the literature. Typical radiological signs were also found in the other cases collected. Radical surgery is the preferred treatment.

Keywords

Intramuscular Mass, Paraspinal Tumour, Ancient Schwannoma, Split Fat Sign

1. Introduction

Schwannomas are slow-growing tumours derived from Schwann cells of the nerve sheath, usually arising from a peripheral nerve. The lesion is mostly benign. Although it commonly occurs as solitary lesions (90%), it can be associated with several central neurological tumours (usually meningiomas, 5%), neurofibromatosis type 2 (3%), or appears as multiple lesions (schwannomatosis, 2%). When solitary, schwannoma develops in the second to fifth decade of life, without significant sex predilection, with a prevalence of 5% among all benign soft tissue neoplasm [1]. It occurs more frequently on the limbs, with a predilection to the upper limbs, followed by the head and neck area, including the oral cavity, orbit and salivary glands [2]. Rarely, a schwannoma occurs in the paraspinal intramuscular space, arising from branches of the dorsal rami [1]-[6]. Histopathologically, schwannomas are classically present as well-defined masses, encapsulated by the epineurium sheath and have been described as being whitish-yellow with a smooth surface [2]. Upon microscopic examination, schwannomas classically exhibit an alternating pattern of hypercellular, fascicular (Antoni-A) and hypocellular, reticulating areas (Antoni-B). The Antoni-A areas are characterized by rows of palisading nuclei, arranged in a dense fashion, whilst Antoni-B zones exhibit a more loose and less organized cell arrangement within a myxoid matrix [5] [6]. Despite being mostly benign, the possibility of malignant transformation of schwannomas is 1%, with degeneration into neurofibrosarcoma [5] and therefore the surgeon must aim at a radical resection.

The morphologic preoperative diagnosis may represent a challenge for the radiologist due to a lack of specific signs. We present a case in which the preoperative assessment of an intramuscular mass was performed according to the latest, despite limited, evidence of the literature, and cooperation between Radiologists, Anesthesiologists and Surgeons allowed for the best planning and a satisfactory result. Besides, we present and discuss a review of the literature about this specific pathology, with the purpose of identifying common findings in the diagnostic process, especially about the radiological pattern.

2. Case Presentation

A 69-year-old female patient came to our attention complaining about an unspecific right dorsal paravertebral numbness, lasting for several months, associated with a right-sided homogeneous subcutaneous mass, without skin reaction. Upon physical examination, the pain was not reproducible and there were no neurological signs. A contrast enhanced MRI of the thoracic column was

subsequently organized. At levels D3-D5, the MRI showed a right-sided intramuscular paravertebral isolated oval-shaped mass, with well-circumscribed margins and heterogeneous component, partly cystic. Contrast enhancement was homogeneous in the non-cystic component. No surrounding edema was found. At the upper pole of the lesion, it was possible to identify a paraspinal nerve coming down from D1, from which the mass raised. The lesion measured $5.6 \times 2.3 \times 1.5$ cm (**Figure 1**). According to clinical and radiological findings, our first hypothesis was a paraspinal schwannoma arising from a right dorsal ramous of D1. An elective surgery was proposed and performed. Using and intra-operative radioscopy, we centered on the levels D3-D5 a right paravertebral skin incision, with subsequent paravertebral muscles dissection, and we identified a well capsulated solid-elastic mass, without muscles infiltration. Under intraoperative microscope, at the upper extremity the lesion-originating nerve was identified, dissected, and isolated (**Figure 2**). Two haemostatic clips were placed proximally to the mass origin, as well as at the lower extremity of the nerve branch coming out from the mass; then we performed a neurotomy with “en bloc” mass resection. Pain management was performed with continuous instillation of Ropivacaine 2% (0.2 mg/10mL), at the rate of 4 cc/hour, throughout a percutaneous perineural catheter. The postoperative recovery was good, the percutaneous catheter was removed at day-4 and a progressive withdrawal from the opioid treatment successfully obtained. The patient was discharged at day-6, with good recovery and no complications. Three MRI, performed during follow up at 6 weeks, 6 months, and 12 months, did not show liquid collection, tumour residual nor tumour recurrence. The histopathology showed a lesion encapsulated inside a perineural sheath, with no residual tumour at the upper and lower extremity, confirming a complete resection (**Figure 3**). At the microscopic analysis, we could confirm a rare OMS grade I “ancient schwannoma”, which exhibits macroscopically cystic degenerations, multiple hemorrhagic lesions and yellowish myxoid foci (**Figure 3**) and, microscopically, degenerative changes such as hyalinized blood vessels, partial loss of Antoni-A areas with cellular shape irregularity and hyperchromatic nuclei as well as thrombi formation (**Figure 4**).

3. Review of the Literature

3.1. Methods

We performed a restricted search (PRISMA-P 2015 based) using the keywords “dorsal schwannoma”, “paraspinal schwannoma”, and “intramuscular schwannoma” on the databases PubMed and Google Scholar. Among the 540 references found and screened, we specifically evaluated 148 references to identify potentially relevant studies. Two reviewers independently screened titles and abstracts of all identified literature. After abstract screening, we included only the original articles, which discussed specifically the intramuscular localization of paraspinal schwannomas, and we excluded any other article with other anatomical localization. The articles are listed chronologically in **Table 1**.

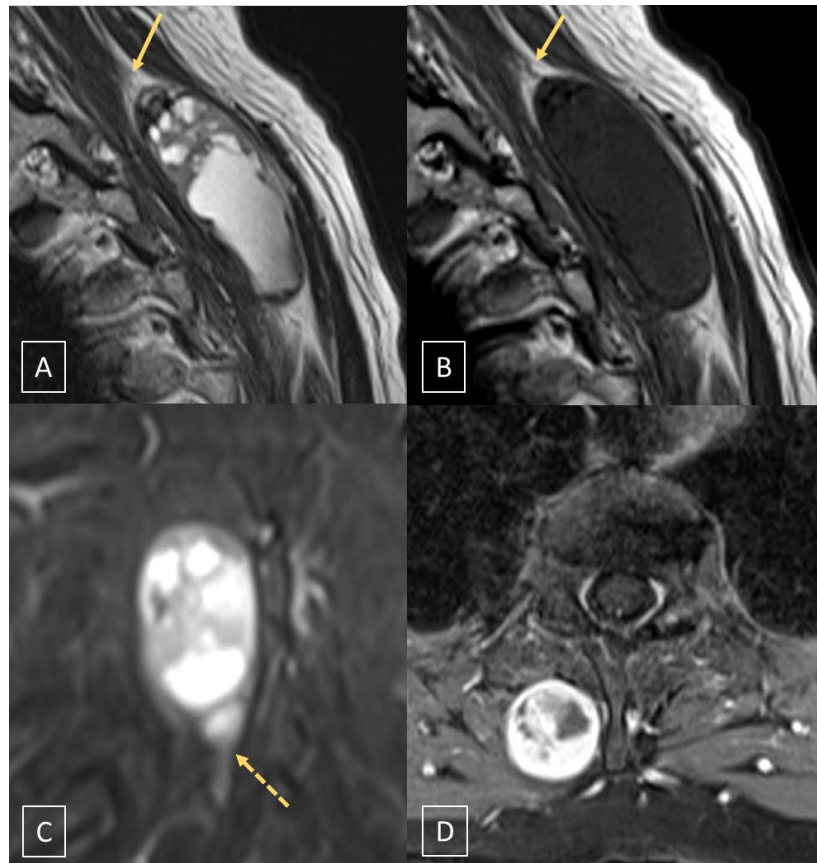


Figure 1. Pre-operative MRI. (A) Sagittal T2-weighted. (B) Sagittal T1-weighted. (C) Coronal STIR. (D) Axial contrast-enhanced T1-weighted with fat suppression. MR scan shows a right-sided intramuscular paravertebral well-circumscribed mass with heterogeneous component, partly cystic, with homogeneous peripheral contrast enhancement of the solid component. At both pole of the lesion, the “entry” (yellow arrows in A and B) and “exit” nerves (dotted arrow in C).

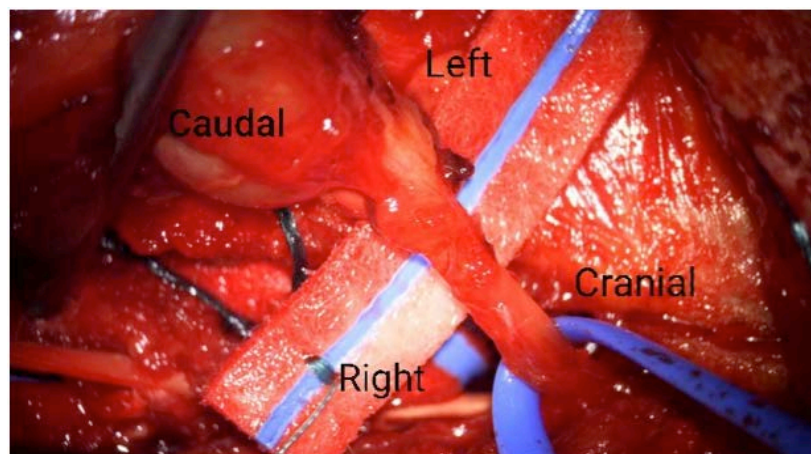


Figure 2. Intra-operative microscopic image (Zeiss Kinevo 900). We identify the lesion (caudal) and the originating nerve (cranial). The surgical approach, planned according to the diagnostic workup, was performed in the aim to extend the anatomical dissection more cranially than the lesion should require, so that an exposition of the originating nerve was feasible.

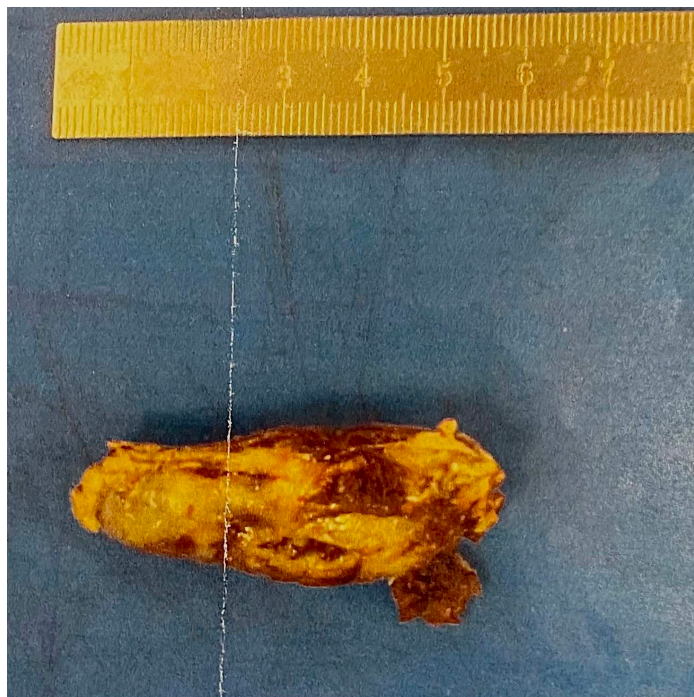

Figure 3. Specimen analysis. Macroscopic evidence of an ovoid tissue nodule measuring $5.5 \times 2.2 \times 1.4$ cm, with irregular combination of yellow mixoid and kysto-hemorrhagic tissues.

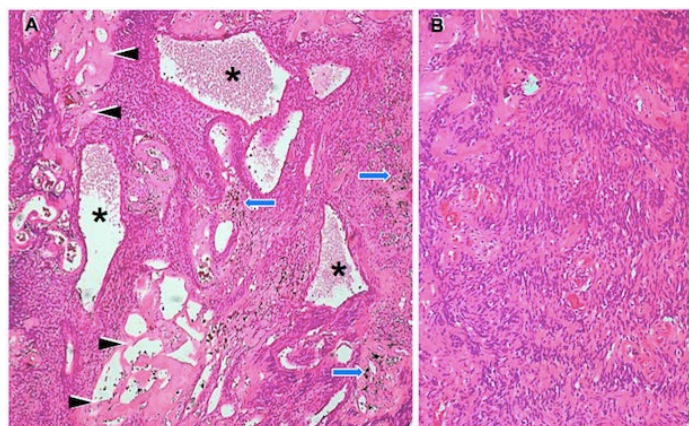


Figure 4. Histological features of pseudoglandular Schwannoma with “ancient” change. (A) At scanning magnification, the tumour displays arresting architectural complexity, where in relatively scant solid arrays of neoplastic cells haphazardly alternate with cystic spaces (asterisks), angiomatous-like blood vessels (arrowheads), and hemosiderin granules (arrows). While the former correspond to fluid filled cavities lined by neoplastic Schwann cells (rather than true epithelium: hence the name pseudoglandular); the latter two alterations represent regressive changes associated with tumour senescence (reflected by the term “ancient schwannoma”). (B) Medium-power view of conventional Schwannoma component to show moderately dense population of inconspicuous fusiform tumour cells. Focal emergence of nuclear palisades (Verocay bodies) is appreciated. Hematoxylin and eosin staining; original magnification: A—x40; B—x200.

Table 1. Studies in chronologic synthesis.

Authors	Title	Source	Study type	Tumour localization	Treatment
Ohla V (2014)	A purely paraspinally located Schwannoma from a dorsal root of a spinal nerve	Google Scholar	Case report	Lumbar segment, L4	Surgery
Kim JH (2015)	Erector Spinal Muscular Schwannoma of the Dorsal Ramus Nerve: A Case Report	Pubmed	Case report	Lumbar segment, L2-L4	Surgery
Shah KA (2018)	Paraspinal Schwannoma of dorsal ramus nerve: A case report	Pubmed	Case report	Thoracic segment, T9-T11	Surgery
Kim DG (2019)	Paraspinal Ancient Schwannoma of the Dorsal Ramus Nerve—A Case Report	Pubmed	Case report	Thoracic segment, T1-T4	Surgery
Emengen A (2019)	A cervical paravertebral schwannoma: A case report	Google Scholar	Case report	Cervical segment, C7	Biopsy and Surgery
Keskin H (2020)	An Uncommon Tumor: Paraspinal Schwannoma	Google Scholar	Case report	Thoracic segment, T7-T8	Surgery

3.2. Analysis

Only 6 publications about purely intramuscular paraspinal schwannoma have been found, until the 1.th August 2021 (**Table 1**). All papers were single centre case reports [1]-[6]. Three lesions were located in the thoracic segment [2] [3] [6], two in the lumbar segment [1] [4] and one case showed a cervical origin of the mass [5].

About the clinical manifestation of this disease, all the Authors remarked a lack of specific symptoms and signs and in each Report the patients come to the medical examination incidentally or because of a soft subcutaneous mass. This “sub-clinical” condition renders the suspicion of intramuscular schwannoma hard, with a plethora of other more frequent intramuscular lesions in differential diagnosis, as lymphomas or hemangiomas [1], and it is common in this pathology, as underlined by Shimose S [7], who provides evidence, that major nerve schwannomas in limbs or head and neck region show usually several symptoms and clinical signs, whilst the intramuscular schwannomas, regardless of the localization, are mainly asymptomatic (80%).

Therefore, we can consider that the imaging plays the main role in the diagnostic workup, and the MRI is the most helpful investigation to perform a differential diagnosis. Among the above-mentioned Reports, only three of them investigate the radiological semiotics of the paraspinal mass. Kim DG (1) and Kim JH [2] describe in their works as the MRI suggests an intramuscular schwannoma when it identifies hypointense foci within a hyperintense T2W area, in a well-defined thick-walled lesion. In the manuscript of Shah KA [3] these same

signs are reported and considered highly suggestive for a neural benign lesion, too. Many other Authors have analyzed the radiological findings of the intramuscular nerve sheath lesions [8] [9] [10], regardless of their anatomical localization, and suggest that there are four MR imaging findings, supporting the diagnosis of intramuscular schwannoma: the “split-fat sign”, the “fascicular sign”, the “target sign” and the “entry-exit nerve” sign. The “split-fat” sign is identified by the detection of prominent fat tissue surrounding a nerve tumour; it is usually better appreciated on T1-weighted images [1]. The “fascicular sign” is characterized by multiple ring-like structures within the lesion with higher signal intensity in the periphery. It is more easily observed on T2-weighted axial and gadolinium-enhanced MR images [3] [8]. The “target sign” is seen on T2-weighted images as a peripheral hyperintense rim with central low signal intensity; it refers to the pathological structure, with fibrous tissue surrounded by mixoid tissue [8]. The “entry-and-exit” sign of the nerve is a consistent and commonly seen MR imaging feature of schwannomas on T2-weighted MR images: a hyperintense signal, situated longitudinally to a fusiform mass. Besides, it is often possible to underline a low-signal rim surrounding the schwannoma on T2-weighted images; it corresponds to the epineurium covering the schwannoma, as mainly mentioned by Kim DG [1]. In the series proposed by Salunke AA [8], 62% of patients presented a “target sign” and in 50% of cases it was possible to assess an “entry-exit” nerve sign, whilst Lee SK underlines as all intramuscular ancient schwannomas of his series showed a clear “split-fat” sign [10].

In the case we presented, as mentioned above, a multidisciplinary team of radiologists analyzed the MRI and we could identify a clear “split-fat” sign and the “entry-exit” sign (**Figure 1**). Despite the several technical considerations given, none of the mentioned works showed a specific common pattern of radiological signs for the paraspinal intramuscular schwannomas. We could just assume that these lesions might be distinguished from other paraspinal intramuscular soft tissue tumours based on muscle changes due to the progressive denervation, according to the radiological behavior of all the intramuscular “non-paraspinal” schwannomas (“split fat” sign); this evidence could be enforced by the identification of the originating nerve (“entry-and-exit sign”), as happened with our patient.

About the surgical procedure, the Authors described the paraspinal schwannoma as a lesion that arises from dorsal roots and bulges eccentrically in a dorsolateral position. So that, a posterior approach centered on the lesion is a simple procedure that can lead to a complete exposure and excision [11]. Kim JH [2] and Shah KA [3] showed also interesting intra and post-operative images of the specimen, whilst other Papers underline only the anatomical approach and the complete excision. Only in the manuscript of Keskin H (6), the surgical excision was performed after a fine-needle biopsy, in order to obtain a clear diagnosis before the surgery. The role of the biopsy is indeed emphasized in the literature as an alternative diagnostic tool to considerate to determine the operative strat-

egy, avoiding overtreatment and major complications, in case of complete absence of radiological specific signs (Antonopoulos C, [12]).

To the best of our knowledge, no evidence of surgical complication in the treatment of paraspinal intramuscular schwannoma has been reported; only one case report refers to a neuropathic chronic pain, but this was associated with an intramuscular “non-paraspinal” schwannoma [13]. Nevertheless, there is evidence of new or worsening pain after excision of an intramuscular peripheral schwannoma, in a percentage between 7.7% and 9.5% of cases [14]. Furthermore, Martinez F has recently shown as 15% of patients, who underwent surgery for a major-nerve schwannoma resection, developed during the follow up major symptoms of neuropathic pain, with severe problems in pain management [15]. One hypothesis about the physiopathology could be that the surgical procedure may lead to a direct damaging of the sensory branches. Thus, we could consider that a prolonged nerve blockade by direct instillation of local anesthetic may prevent the late development of these symptoms, as it happens in post-traumatic nerve lesion (Shankarappa SA, [16]). Among the Papers discussing about the paraspinal schwannoma, we did not find specific pre-post operative treatments and the Authors report good outcome at the follow-up. According to this consideration, we involved our Chronic Pain Unit during the preoperative work-up and we discussed the usefulness of a postoperative analgesic continuous instillation by a percutaneous catheter, as described above, which resulted to be overall effective as pain management strategy.

The pathological data was available in each Report at our knowledge, but mainly used to confirm the diagnosis of a common schwannoma, without specific consideration. Only Kim DG [1] gives enough details to identify a case of “ancient” schwannoma, similar to the one we treated.

4. Discussion

Our analysis shows that the data collected in the literature about the paraspinal intramuscular schwannoma is too little to produce a common pattern of clinical and radiological presentation. Nevertheless, we can underline that the majority of the cases (58%) was detected at the thoracic segment, 28% of cases were at the lumbar segment and only one case was at the cervical column. The clinical manifestation was overall barely absent, but for a local mass effect on the soft tissue and eventually “numbness” at the skin surface, probably related to a sensory branch involvement. The main argument on which our research was focused—*i.e.* the radiological features of the lesion—showed that, among the many helpful signs to identify on MRI a schwannoma, only the “split-fat sign” was reported and commonly identified in the literature, with not even a systematic identification of the originating “entering-and-exiting” nerve. Therefore, it is not possible to propose standardization. Discussing the treatment options, 100% of cases underwent a complete surgical resection. In one case, a fine needle biopsy was preferred, before surgery, in order to assess a diagnosis; that might be con-

sidered an option in the diagnostic workup. A complete “en bloc” resection, better if under intraoperative microscope to allow nerve branches identification, should be recommended due to the rare but possible malignant degeneration to a fibrosarcoma. The rare variant of “ancient schwannoma” was reported just in the 28% of the cases and so we can assume, at the best of the actual evidence, that the paraspinal intramuscular schwannoma does not present special cluster of histological differentiation. About the postoperative management, the patients affected by a paraspinal intramuscular schwannoma show good and fast recovery after surgery. Special care could be paid to avoid new or worsening pain after excision, including a postoperative neuropathic pain. Our experience with a perineural continuous instillation of local anesthetic resulted in effective and satisfying management, but no data is available to consider it as a standard of care.

5. Conclusion

The management of the presented clinical case reflected the standards currently found in the literature. Careful analysis of the MRI images should be performed in order to identify one or more of the typical signs of a paraspinal intramuscular schwannoma. A complete resection should be preferred to a “stand alone” biopsy or debulking surgery. The patients affected by these lesions have shown good recovery after surgery and no further complications.

Acknowledgements

Thank to individuals who contributed to the study or manuscript preparation but do not fulfill all the criteria of authorship. Alfio Valsecchi provided language and proofreading support. Silvia Riccardi, MD, provided writing assistance.

Consent

Written informed consent was obtained from the patient for publication of this case report and accompanying images. A copy of the written consent is available for review by the journal Editor-in-Chief.

Conflicts of Interest

Authors declare no conflicts of interest regarding the publication of this paper.

References

- [1] Kim, D.G. and Jo, Y.M. (2019) Paraspinal Ancient Schwannoma of the Dorsal Ramus Nerve—A Case Report. *Journal of Korean Society of Spine Surgery*, **26**, 111-115. <https://doi.org/10.4184/jkss.2019.26.3.111>
- [2] Kim, J.H., Cho, T.G., Kim, C.H., Moon, J.G. and Lee, H.K. (2015) Erector Spinal Muscular Schwannoma of the Dorsal Ramus Nerve: A Case Report. *Korean Journal of Spine*, **12**, 204-206. <https://doi.org/10.14245/kjs.2015.12.3.204>
- [3] Shah, K.A. and Shah, A.C. (2018) Paraspinal Schwannoma of Dorsal Ramus Nerve: A Case Report. *Journal of Clinical Orthopaedics and Trauma*, **9**, S1-S4. <https://doi.org/10.1016/j.jcot.2018.04.012>

- [4] Ohla, V. and Scheiwe, C. (2014) A Purely Paraspinaly Located Schwannoma from a Dorsal Root of a Spinal Nerve. *Journal of Advances in Medicine and Medical Research*, **4**, 1366-1370. <https://doi.org/10.9734/BJMMR/2014/7068>
- [5] Emengen, A., Ergen, A., Genç, M.H., Kiraz, U. and Ll bay, M.K. (2019) A Cervical Paravertebral Schwannoma: A Case Report. *International Journal of Medical Science and Discovery*, **6**, 347-350. <https://doi.org/10.36472/msd.v6i12.335>
- [6] Keskin, H., Kalkan, E., Gündüz, E. and Ocağ, G.A. (2020) An Uncommon Tumor: Paraspinal Schwannoma. *Journal of Cukurova Anesthesia and Surgical Sciences*, **3**, 28-33. <https://doi.org/10.36516/jocass.2020.29>
- [7] Shimose, S., Sugita, T., Kubo, T., Matsuo, T., Nobuto, H., Tanaka, K., Arihiro, K. and Ochi, M. (2007) Major-Nerve Schwannomas versus Intramuscular Schwannomas. *Acta Radiologica*, **48**, 672-677. <https://doi.org/10.1080/02841850701326925>
- [8] Salunke, A.A., Chen, Y., Tan, J.H., Chen, X., Foo, T.L., Gartner, L.E. and Puhaindran, M.E. (2015) Intramuscular Schwannoma: Clinical and Magnetic Resonance Imaging Features. *Singapore Medical Journal*, **56**, 555-557. <https://doi.org/10.11622/smedj.2015151>
- [9] Jeong, Y.J., Ko, H.S. and Shim, H.S. (2017) Differential Diagnosis of Intramuscular Schwannoma of the Craniocervical Region. *Journal of Craniofacial Surgery*, **28**, e689-e690. <https://doi.org/10.1097/SCS.00000000000003844>
- [10] Lee, S.K., Kim, J.Y., Lee, Y.S. and Jeong, H.S. (2020) Intramuscular Peripheral Nerve Sheath Tumors: Schwannoma, Ancient Schwannoma, and Neurofibroma. *Skeletal Radiology*, **49**, 967-975. <https://doi.org/10.1007/s00256-020-03371-6>
- [11] Dhar, A., Pawar, S., Prasad, A. and Ramani, P.S. (2017) Approaches to Paraspinal Tumours—A Technical Note. *Neurological Research*, **39**, 315-322. <https://doi.org/10.1080/01616412.2017.1297556>
- [12] Antonopoulos, C., Lilimpakis, C., Karagianni, M., Daskalopoulou, D., Kyriakou, T. and Vagianos, C. (2009) Ancient Schwannoma of Lumbar Spine and Review of the Literature on Paraspinal Tumors, the Role of Preoperative Biopsy: A Case Report. *Cases Journal*, **2**, Article No. 9325. <https://doi.org/10.1186/1757-1626-2-9325>
- [13] Hsu, Y.C., Shih, Y.Y., Gao, H.W. and Huang, G.S. (2010) Intramuscular Schwannoma Arising from the Psoas Muscle Presenting with Femoral Nerve Neuropathy. *Southern Medical Journal*, **103**, 477-479. <https://doi.org/10.1097/SMJ.0b013e3181d7b497>
- [14] Kwon, B.C., Baek, G.H., Chung, M.S., Lee, S.H., Kim, H.-S. and Oh, J.H. (2003) Intramuscular Neurilemoma. *The Journal of Bone and Joint Surgery, British Volume*, **85**, 723-725. <https://doi.org/10.1302/0301-620X.85B5.13850>
- [15] Martinez, F., Paez, M., Cuadros-Romero, M., Moragues, M., Nogueras, M.S.-F., Casales, N., et al. (2020) Peripheral Nerve Tumours: A 66-Case Retrospective Study. Sociedad Espanola de Neurocirurgia. *Neurocirugía*, **31**, 105-111. <https://doi.org/10.1016/j.neucie.2019.12.001>
- [16] Shankarappa, A.S., Tsui, J.H., Kim, K.N., Reznor, G., Dohlman, J.C., Langer, R. and Kohane, D.S. (2012) Prolonged Nerve Blockade Delays the Onset of Neuropathic Pain. *Proceedings of the National Academy of Sciences of the United States of America*, **109**, 17555-17560. <https://doi.org/10.1073/pnas.1214634109>