

Parasites Pathogens and Prevalence of the Green Pigeon (*Treron calvus*, TEMMINCK, 1811) in the South-East of Côte d'Ivoire: Histopathological Assessment

Alassane Toure¹, Ida Akissi Konan^{2*}, Olivier Assoi Etchian², Arthur Gogbe²

¹Laboratoire Central Vétérinaire de Bingerville, Bingerville, Côte d'Ivoire

²Formation Unit and Research of Nature Sciences Laboratory of Biology and Animal Cytology, University Nangui Abrogoua, Abidjan, Côte d'Ivoire

Email: *idaakissikonan@gmail.com

How to cite this paper: Toure, A., Konan, I.A., Etchian, O.A. and Gogbe, A. (2023) Parasites Pathogens and Prevalence of the Green Pigeon (*Treron calvus*, TEMMINCK, 1811) in the South-East of Côte d'Ivoire: Histopathological Assessment. *Journal of Biosciences and Medicines*, 11, 45-54.
<https://doi.org/10.4236/jbm.2023.1111005>

Received: July 5, 2023

Accepted: November 4, 2023

Published: November 7, 2023

Copyright © 2023 by author(s) and Scientific Research Publishing Inc. This work is licensed under the Creative Commons Attribution International License (CC BY 4.0).

<http://creativecommons.org/licenses/by/4.0/>



Open Access

Abstract

Today, the green pigeon (*Treron calvus*, TEMMINCK, 1811) holds an increasingly important place in the dietary habits of the populations of south-east of Côte d'Ivoire, especially those of Grand-Bassam. To provide food security to these customers a study was carried out. **Objective:** The current study is to identify the different protozoa and fungus that could potentially infect the green pigeon's gut. **Materials and Methods:** The study was carried out on protozoa and digestive fungus in this species of pigeon in the south-east of Côte d'Ivoire. It has been carried out from November 2020 to February 2021. A total of sixty freshly dead pigeons, including 10 males and 50 females, have been bought in Grand-Bassam. After autopsy, the gut of each animal was preserved in formalin (10%) for a subsequent histopathological examination. **Results:** The analysis of the results revealed the following pathogen genus: *Cryptosporidium spp*, *Histomonas spp*, *Toxoplasma gondii* and *Trichomonas spp* for protozoa. *Cryptococcus neoformans* for fungus. The calculation of prevalence gave the following values: 63% [20; 40] for protozoa and 37% [10; 40] for fungus. **Conclusion:** The study showed that the intestine of the green pigeon of the Grand-Bassam region is infested by a range of pathogens. Namely: *Cryptosporidium spp*, *Histomonas spp*, *Toxoplasma gondii*, *Trichomonas spp* and *Cryptococcus neoformans*. *Cryptococcus neoformans* was the most common pathogen encountered in this study. Among these pathogens, some like *Cryptococcus neoformans* and *Toxoplasma gondii* are zoonosis. Thus, the present study deserves further investigation to know more about the nature of human infection in Côte d'Ivoire. Furthermore, given the diversity of digestive pathogens including zoonosis one, a reasonable recommendation to consumers would be stop eating the intestines.

Keywords

Grand-Bassam, Green Pigeon, Protozoa, Fungus, Prevalence

1. Introduction

The green pigeon (*Treron calvus*) is a bird that belongs to columbiform. Native to sub-Saharan countries [1], it is one of the five species of green pigeon. It lives in the canopy of trees in tropical forests. In Côte d'Ivoire, this wild bird is hunted for consumption and marketing because it constitutes a significant source of animal protein some people: such is the case for those of Grand-Bassam in the south-east of the country. Pigeons generally consume worms and insects that can carry parasites [2]. Thus, their intestines constitute a favorable environment for infection by parasites because it provides them with sufficient food and a safe shelter [3]. Previous studies have been conducted on ecto- and endoparasites in pigeons. These are studies generally carried out on gastrointestinal parasites in domestic pigeons (*Columba livia domestica*). This is the case of [4] in Nepal, [5] in Nigeria and [6] in Libya. Moreover, according to [7], the urban pigeon (a species more closely related to *Treron calvus*) is liable to various internal diseases involving bacteria, viruses, fungus and intestinal worms. However, the health status of this animal remains unknown in Côte d'Ivoire. Indeed, except a few counting works on the avifauna of some areas in which the name *Treron calvus* appears, there is still no work done on this pigeon species in Côte d'Ivoire [8] [9]. From the mentioned above, it therefore appears necessary to study protozoa and fungus and their prevalence in green pigeon in order to provide food safety to its consumers. The purpose of this study was to contribute to the establishment of the first assessment in Côte d'Ivoire, of infections due to digestive pathogens, specifically protozoa and fungi of the green pigeon (*Treron calvus*) in the South-East of Côte d'Ivoire (Grand-Bassam).

2. Material and Methods

2.1. Research Area

The sampling took place in the town of Grand-Bassam, situated between 3° and 3°94' west longitude and 5° to 5°13' north latitude, it covers an area of about 1000 km² for a population of 50,000 inhabitants [10]. Grand-Bassam is 40 km from Abidjan. There are about ten green pigeon hunters. The proximity of the town to the Ivorian metropolis Abidjan and the large number of green pigeon hunters favored the choice of this town for this study (Figure 1).

2.2. Ethical Issues

Hunting of green pigeons practice is done many decades ago independently of the current study. For the purpose of this study, these pigeons have been bought as well as inhabitants of Grand-Bassam did.

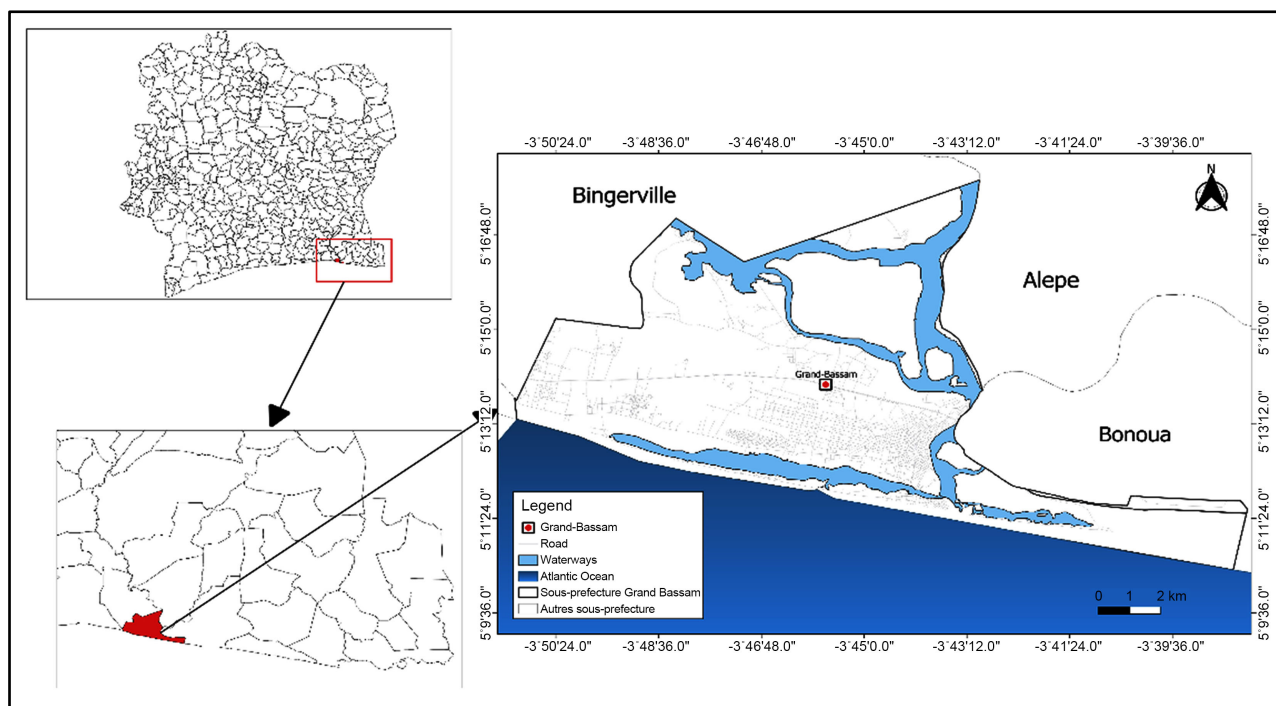


Figure 1. Presentation of the research area.

2.3. Sampling

The green pigeon measures 23 to 30 cm in length and weighs 160 to 285 g for the male and 130 to 225 g for the female. The plumage is predominantly green tinged with yellow on the head and underparts. The neck and upper coat are gray. The irises are pale blue with brown eyerings. The legs are yellow or pinkish.

At the start of this study it was a question of carrying out experiments on 300 pigeons in order to have a scientifically significant result. However, due to certain constraints in the field, we obtained sixty and sixty birds.

Sampling of green pigeons (*Treron calvus*, TEMMINCK, 1811) was done from 17 November to 18 December, 2020. The pigeons were captured by hunters with glue spread early in the morning (around 6 am) on the branches of the fig trees. Then, a few live green pigeons (usually 3 to 5 pigeons) were placed on these branches. These served as bait to attract other pigeons and made it easier to capture them.

2.4. Laboratory Procedures

During autopsy, the small intestine were opened and checked for eventual lesions. Then in case or lesion, this 3 cm³ of this part of tissue has been cut and fixed and conditioned in 10% of formalin buffered solution for further histopathological examinations. Even if there is no lesion, the same sample is done. Then, formalin fixed-tissue were embedded in paraffin and cut into 6 μm sections. Finally, slides have been prepared following classical Hematoxylin eosin staining [11]. When fungi are revealed, additional Grocott methenamine silver

stain has been done to strengthen the finding. Diagnostic is made by a Veterinary-Pathologist with emphasis on protozoan and fungi pathogens.

2.5. Statistical Methods

Two statistics software packages (R software version 3.1.3 and Excel software) were used in this analysis for the estimation, comparison and representation of prevalence. The chi-square test was used for comparison of the prevalence estimates. The chi-square test was set at the 5% threshold for significant difference.

2.6. Prevalence Estimate

The prevalence of a given event is the percentage of occurrence of that event in a susceptible population. The prevalence of a pathogen in a given gut has been estimated by the following equations:

$$\text{Global prevalence} = \frac{\text{Number of pigeons infected}}{\text{Number of pigeons examined}} \times 100$$

$$\text{Prevalence of a selected pathogen} = \frac{\text{Number of pigeons infected with the considered pathogen}}{\text{Number of pigeons examined}} \times 100$$

3. Results

3.1. Characteristics of the Green Pigeons Examined

A total of sixty pigeons were included in this study, of which fifty (50) were females and ten (10) were males. The birds were all adults and apparently healthy. However, analysis of the histological sections revealed three types of pathogens (parasites: protozoans and helminths), fungi and viral inclusions). Nineteen (19) pigeons out of sixty (60), *i.e.* (31%) were infested with at least one digestive pathogen.

3.2. Types of Protozoa and Fungi Found in Green Pigeons

The protozoans and fungus observed after reading the histological sections are: *Cryptosporium spp*, *Toxoplasma gondii*, protozoa of the class Coccidia. *Histomonas spp*, and *Trichomonas gallinae* (Figure 2) which are flagellate protozoans. The fungi highlighted are *Cryptococcus neoformans*. The pathogens identified are listed in Table 1.

3.3. Relative Importance between Types of Parasites

The intestinal pathogens of the green pigeon (*Treron calvus*) grouped according to the phylum of protozoa and fungi have the respective prevalence values: 63% [95% CI; 20; 40] and 37% [95% CI; 10; 40]. The χ^2 test ($p = 0.009322$) shows a significant difference between the calculated prevalence (Figure 3).

3.4. Prevalence by Pathogens

The prevalence calculation per pathogen resulted in prevalence values ranging

from 1.7% [95% CI; 0; 10] to 11.7% [95% CI; 0; 20] (**Figure 4**). Thus *Toxoplasma gondii* is the pathogen for which the prevalence of 1.7% [95% CI; 0; 10] was obtained. Prevalence's of 3.3% [95% CI; 0; 10] and 6.7% [95% CI; 0; 10] have been observed respectively for *Trichomoniasis gallinae* and *Histomonas meleagridis*. Finally, the highest prevalence is reached for *Cryptococcus neoformans* with 11.7% [95% CI; 0; 20]. There were no significant differences between these prevalences.

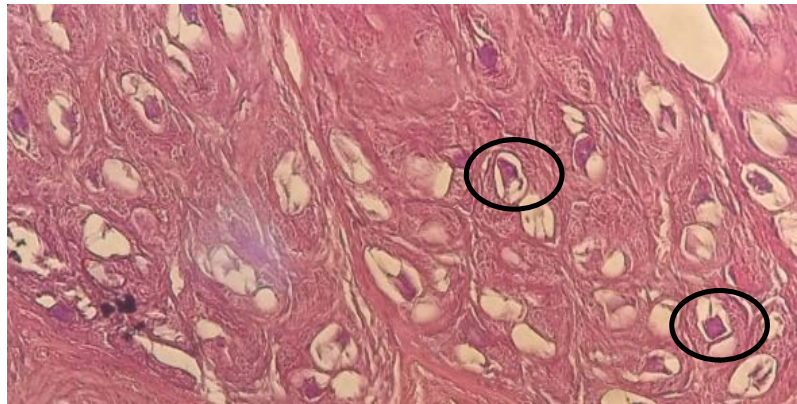


Figure 2. *Trichomoniasis gallinae* ($\times 100$) identified in the small intestine of green pigeons of Grand-Bassam.

Table 1. Main protozoa and fungi prevailing in green pigeon from Grand-Bassam (Côte d'Ivoire).

Phylum	Pathogen	Number of infection	Specific Prevalence of pathogen
Protozoal	<i>Cryptosporidium spp.</i>	5	8.3% [95% CI; 0; 20]
	<i>Histomonas meleagridis</i>	4	6.7% [95% CI; 0; 10]
	<i>Toxoplasma gondii</i>	1	1.7% [95% CI; 0; 10]
	<i>Trichomoniasis gallinae</i>	2	3.3% [95% CI; 0; 10]
Fungi	<i>Cryptococcus neoformans</i>	7	11.7% [95% CI; 0; 20]
Total	5 types of parasites pathogen	19	31%

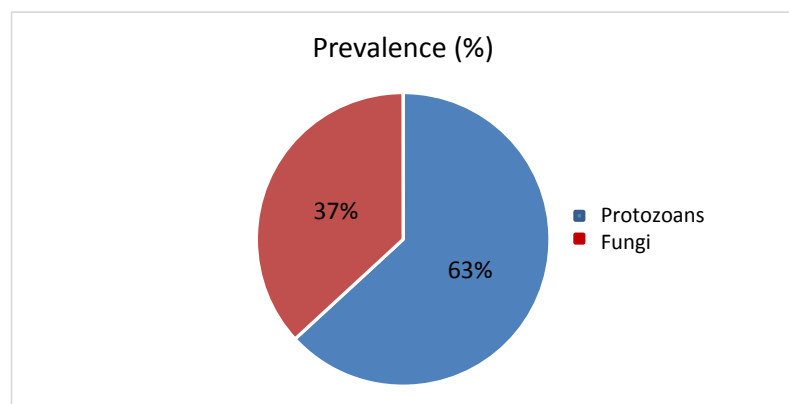


Figure 3. Relative importance of protozoans and fungus identified in the small intestine of the green pigeon in south-eastern Côte d'Ivoire.

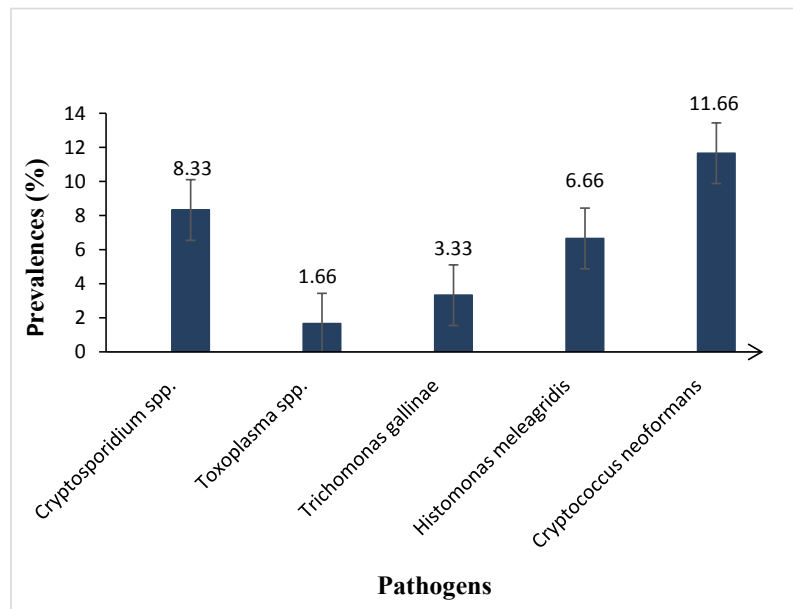


Figure 4. The prevalence of different pathogens in the gut of the green pigeon in south-eastern Côte d'Ivoire.

4. Discussion

To the authors' best knowledge, this is the first histopathological assessment of parasites pathogens infecting green pigeons in west of Africa. In this study, our results showed that a total of 36 pigeons were infected with at least one pathogen out of a total of 60 (60%). Four genera of protozoa (*Cryptosporidium* spp., *Histomonas* spp, *Toxoplasma gondii* and *Trichomonas gallinae*) and one genus of fungi *Cryptococcus neoformans* were identified. The high infestation rate and the diversity of pathogens found in this pigeon could be explained by its living space. Indeed, the green pigeon, being a wild animal, leads a free life where it is more exposed to germs in the environment and to parasite eggs emitted by other animals (intermediate or definitive hosts) in the same environment. These results are consistent with those of [12] [13], who in their work recorded a higher rate of infestation in free-range birds than in penned birds. According to these authors, animals in a pen receive medical care, have their living environment maintained and a diet controlled by the breeder. The results of this study are also in agreement with those of [14], who inventoried six different species of endoparasites (3 species of *Eimeria* sp., *Capillaria* sp. and *Heteraksi* sp.) in the Biset pigeon in Algeria. However, these results contrast with those of [15], in Algeria, who recorded 2 species of endoparasites (*Eimeria* sp. and *Taenia* sp.) in columbids. The difference between the results of these works can be attributed to the pathogen detection methods used in each work and the environment of these green pigeons.

In this study, the prevalence of protozoa was higher (63%) than that of fungi (37%). The high prevalence of protozoan infection recorded in the present study could be an indication of a high incidence of infective stages and intermediate

hosts of parasites in the green pigeon environment.

The existence of *Cryptosporidium spp.* in the intestines of the green pigeon could be explained by the fact that the ileum is the preferred site of this parasite in birds according to [16]. Another reason for this infestation could be the frequentation of unsanitary places by the green pigeon.

Histomonas meleagridis a flagellate protozoan mainly infects avian galliform species [17]. Green pigeon infection could reveal frequent visits in poultry environments.

Toxoplasma gondii is a widespread parasite in the animal kingdom. It infects all homeotherms, including pigeons. Its presence in the intestine of the green pigeon could be explained by the presence of cats in the feeding grounds of this bird. Indeed, the cat, being a member of the felid family and the only definitive host of *Toxoplasma gondii*, plays a major role in the dissemination of the parasite in the environment [18].

Analysis of the green pigeon intestines also revealed the presence of *Trichomonas gallinae*. This could be due to the fact that the green pigeon had consumed food or drink water contaminated with this parasite. Furthermore, this result is in line with that of [19], according to whom *Trichomoniasis gallinae* is a protozoan parasite that is usually found in the upper digestive tract of doves and avian predators that feed on doves. Infections imply more frequently rock pigeon (*Columba livia*). The prevalence varies between 0% to 100% [20]. The current result is in contrast to those of [21] [22] [23]. These authors obtained 50.3%, 57.84% and 55% respectively in their work. The difference between these results could be mainly due to the number of pigeons examined, the parasite detection techniques used and the length of the sampling period, which differed in each study. Indeed, these authors conducted their study on 102, 100 and 426 pigeons respectively compared to 60 pigeons in our study. [22] [23] used the direct parasitological staining technique in their study versus the histopathology technique in this study. In this study the sampling of pigeons was carried out from November to December 2020 while that of [22] took place between October 2008 and September 2009 and that of [21] from September 2002 to April 2004.

As expected in most of avian species, it is not surprising that *Cryptococcus neoformans* appears to be one of the zoonosis pathogens that commonly infect the green pigeon.

The considerable difference between the predicted number and the number of pigeons obtained for our experiment could be explained on the one hand by overexploitation of the species during the study period. Indeed, when there is an increasing demand for green pigeons by consumers on the market, this also leads to an increase in the number of pigeon hunters. On the other hand, the explanation could be climatic and unfavorable food conditions to green pigeons in the study area during sampling. In the absence of food in suitable climatic conditions, these birds tend to move to areas more conducive to their survival and well-being.

5. Conclusions

Ivorians in general have always had a preference for game, including green pigeons, as a source of animal protein. However, the infection status of these animals is sometimes unknown. Therefore, in order to ensure food safety for consumers of these birds, a study was carried out on protozoa and fungi in green pigeons in the south-eastern Côte d'Ivoire. This study showed that the intestine of the green pigeon of the Grand-Bassam region is infested by a range of pathogens. Namely: *Cryptosporidium spp*, *Histomonas spp*, *Toxoplasma gondii*, *Trichomonas spp* and *Cryptococcus neoformans*. *Cryptococcus neoformans* was the most common pathogen encountered in this study. Among these pathogens, some like *Cryptococcus neoformans* and *Toxoplasma gondii* are zoonosis. Thus, the present study deserves further investigation to know more about the nature of human infection in Côte d'Ivoire. Furthermore, given the diversity of digestive pathogens including zoonosis one, a reasonable recommendation to consumers would be stop eating the intestines.

In the future, it would be interesting to extend this study to other regions of the country and to other tissues (such as muscle tissue), to obtain more consistent information on parasitic infections in this animal species, which occupies a significant place in the diet of Ivorians. It is also important to carry out a study on the other seasons of the year, namely the long dry season, the long rainy season and the short dry season, to gain a better understanding of the health aspect of the green pigeon. In addition, studies on other diagnostic techniques, namely molecular techniques, should be considered in order to increase the sensitivity of the tests. This first original study in Côte d'Ivoire also shows the need to study the impact of abiotic factors in greater depth.

Acknowledgements

This work has been made possible through the support (technical and financial) of the authors.

Contribution of the Authors

GOGBE Arthur: Autopsy, data collection, statistical analysis and interpretation of results. TOURE Alassane: Autopsy, Technical supervisor, Histopathological diagnosis, Writing and reviewing of the manuscript and final approval of the work. ETCHIAN Assoi Olivier: supervision of the work. KONAN Akissi Ida: Statistical analysis and interpretation of results, critical revision of the script.

Conflicts of Interest

The authors declare no conflicts of interest regarding the publication of this paper.

References

- [1] Gibbs, D., Barnes, E. and Cox, J. (2011) Handbook of the Bird of the World—Volume

- 4, 420-503.
- [2] Soulsby, E.J. (1982) Helminthes, arthropodes et protozoaires des animaux domestiques. 7th édition, Baillière Tindall, Londres, 630-637.
- [3] Metthews, B.E. (2001) Une introduction à la parasitologie. Presse de l'Université de Cambridge, Cambridge, 81.
- [4] Amrit, G. and Janak, R.S. (2016) Prevalence of Gastrointestinal Parasites of Pigeons (*Columba* sp. Linnaeus, 1758) in Three Temples of Pokhara Valley, Nepal. *Journal of Natural History Museum*, **30**, 287-293.
<https://doi.org/10.3126/jnhm.v30i0.27604>
- [5] Buba, Z.M., Ambas P.F., Elihu A., Danladi T. (2018) Prevalence of Gastrointestinal Parasite of Domestic Pigeon (*Columba Livia*) In Mubi North LGA of Adamawa State, Nigeria. *International Journal of Innovative Research and Advanced Studies*, **5**, 315-319.
- [6] Ferial, A.A., Naas, A.S.E.L. and Maghrbi, A.A.E. (2018) Survey of Parasites in Domestic Pigeons (*Columba livia*) in Tripoli, Libya. *Open Veterinary Journal*, **8**, 360-366. <https://doi.org/10.4314/ovj.v8i4.2>
- [7] Zaidi, K. and Saheb, M. (2014) Identification des ectoparasites chez le pigeon biset *Columba livia* dans la ville d'Oum-El-Bouaghi. Ph.D. Thesis, Université d'Oum-El-Bouaghi, Algérie, 68 p.
- [8] Yaokokore-Beibro, K.H. (2010) Oiseaux du Parc National des Iles Ehouilé Sud-Est Côte d'Ivoire. *Malibus*, **32**, 89-102.
- [9] Ahon, D.B., Egnankou, W.M. and Kouame, O.M. (2012) Inventaire préliminaires des oiseaux de la forêt des marais, Tanoé-Ehyen Côte d'Ivoire. *International Journal of Biological and Chemical Science*, **6**, 4031-4045.
<https://doi.org/10.4314/ijbcs.v6i6.14>
- [10] Tape, J.B. (1999) Cartographie des aménagements touristiques du cordon littoral de Grand-Bassam. *Cahiers Nantais*, **51**, 39-46. <https://doi.org/10.3406/canan.1999.1236>
- [11] Prophet, E.B., Mills, B., Arrington, J.B. and Sobin, L.H. (1992) Laboratory Methods in Histotechnology. American Registry of Pathology, Washington DC.
- [12] Msoffe, P.L., Muhairwa, A.P., Chiwanga, G.H. and Kassuku, A.A. (2010) A Study of Ecto- and Endoparasites of Domestic Pigeons in Morogoro Municipality, Tanzania. *African Journal of Agricultural Resources*, **5**, 264-267.
- [13] Mshelia, B.Z., Ambas, P.F., Elihu, A. and Danladi, T. (2018) Prevalence of Gastrointestinal Parasite of Domestic Pigeon (*Columba livia*) in Mubi North LGA of Adamawa State, Nigeria. *International Journal of Innovative Research and Advanced Studies*, **5**, 315-319.
- [14] Djelmoudi, Y.A., Daoudi-Hacini, M.S. and Doumandji, S. (2014) Common Endoparasites of Wild Rock Pigeon (*Columba livia livia*) and Wood Pigeon (*Columba palumbus*) in the Algiers Sahel, Algeria. *International Journal of Zoology and Research (IJZR)*, **4**, 99-106.
- [15] Messaoudi, Z. (2017) Etude des ectoparasites, des endoparasites, et des hémoparasites chez les columbidés de la région de la Mitidja. Master's Thesis, Université de Blida 1, Algérie, 100 p.
- [16] Chermette, R., Tarnau, C., Boufassa-Ouzrout, S. and Couderc, O. (1989) Survey on Equine Cryptosporidiosis in Normandy. In: Inra, Y.P. Ed., *Coccidia and Intestinal Coccidiomorphs. Proceedings of the Vth International Coccidiosis Conference*, Service des Publications, Versailles, 493-498.
- [17] Davidson, W.R. (2008) Histomonas. In: Atkinson, C.T., Thomas, N.J. and Hunter,

- D.B., Eds., *Parasitic Diseases of Wild Birds*, John Wiley & Sons, Inc., Hoboken, 154-159. <https://doi.org/10.1002/9780813804620.ch7>
- [18] Essayagh, M. (2019) Séroprévalence de la toxoplasmose chez les animaux de boucherie Meknès-Setta. Ph.D. Thesis, Université Mohammed V, Maroc, 94 p.
- [19] Conti, J.A. (1993) Diseases, Parasites and Contaminants. In: Baskett, T.S., Sayre, M.W., Tomlinson, R.E. and Mirarchi, R.E., Eds., *Ecology and Management of the Morning Dove*, Stackpole Books, Harrisburg, Pennsylvania, 205-224.
- [20] Forrester, D.J. and Foster, D.W. (2008) Trichomonosis. In: Atkinson, C.T., Thomas, N.J. and Hunter, D.B., Eds., *Parasitic Diseases in Wild Birds*, Blackwell Publishing, Hoboken, 120-153. <https://doi.org/10.1002/9780813804620.ch6>
- [21] Bunbury, N., Jones, C.G., Greenwood, A.G. and Bell, D.J. (2008) Epidemiology and Conservation Implications of *Trichomoniasis gallinae* Infection in the Endangered Mauritian Pink Pigeon. *Biological Conservation*, **141**, 153-161. <https://doi.org/10.1016/j.biocon.2007.09.008>
- [22] Radfar, M.H., Khedri, J., Adinehbeigi, K., Nabavi, R., Rahmani, K. (2013) Prevalence of Parasites and Associated Risk Factors in Domestic Pigeons (*Columba livia domestica*) and Free Range Backyard Chickens of Sistan Region, East of Iran. *Journal of Parasites Diseases*, **36**, 220-225. <https://doi.org/10.1007/s12639-012-0112-5>
- [23] Alkharigy, F.A., EL Naas, A.S. and EL Maghrbi, A.A. (2018) Survey of Parasites in Domestic Pigeons (*Columba livia*) in Tripoli, Libya. *Open Veterinary Journal*, **8**, 360-366. <https://doi.org/10.4314/ovj.v8i4.2>