

An Extensively Drug Resistant *Acinetobacter baumannii* from Soft Tissue Isolated in a Hospital in Senegal

Cheikh Fall^{1*}, Ousmane Sow¹, Fatim P. Ly¹, Boly Diop², Bissoume Sambe-Ba¹, Yakhya Dieye¹

¹Pole de Microbiologie, Institut Pasteur de Dakar, Dakar, Senegal

²Direction de la Prévention, Ministère de la Santé et de L'action Sociale, Dakar, Senegal

Email: *cheikh.fall@pasteur.sn

How to cite this paper: Fall, C., Sow, O., Ly, F.P., Diop, B., Sambe-Ba, B. and Dieye, Y. (2022) An Extensively Drug Resistant *Acinetobacter baumannii* from Soft Tissue Isolated in a Hospital in Senegal. *Case Reports in Clinical Medicine*, 11, 72-78.
<https://doi.org/10.4236/crcm.2022.113011>

Received: January 14, 2022

Accepted: March 15, 2022

Published: March 18, 2022

Copyright © 2022 by author(s) and Scientific Research Publishing Inc.
This work is licensed under the Creative Commons Attribution International License (CC BY 4.0).

<http://creativecommons.org/licenses/by/4.0/>



Open Access

Abstract

Emerging and rapidly spreading multidrug resistant bacteria constitute a rising public health concern worldwide. *Acinetobacter baumannii* is one of these bacteria that cause different infections including pneumonia, bacteremia, meningitis, soft-tissue, and urinary tract infections, and are associated with high mortality and economic burden. We present a case of a 43-year-old woman, admitted at the department of orthopedics, regional hospital of Ourosogui, North-East of Senegal for soft-tissue injuries. Initially diagnosed with *Yersinia pestis* infection, the patient was well managed before being released. Supplementary sampling for confirmatory tests allowed the detection of an extensively drug-resistant *Acinetobacter baumannii* clone.

Keywords

Acinetobacter baumannii, Extensively Drug Resistance, Soft-Tissue, Senegal

1. Introduction

Acinetobacter baumannii has become a leading cause of nosocomial infections, especially in patients in intensive care units (ICUs). *A. baumannii* clones are often multidrug-resistant (MDR), leaving limited options for antibiotic treatment [1]. The World Health Organization (WHO) recently ranked carbapenem-resistant *A. baumannii* as the most critical bacterial pathogen for public health [2]. Invasive procedures and patients' exposure to certain antimicrobials are risk factors for colonization and infections by MDR *A. baumannii*. Moreover, cross-transmission among hospitalized patients is favored by poor adherence to hand hygiene practices and by repeated contact with contaminated environments [3]. Despite the

increase incidence of MDR *A. baumannii* in many parts of the world, data from sub-Saharan Africa are scarce. We present a case of an extensively drug-resistant *A. baumannii* isolated from the soft tissues of a 43-year-old woman.

2. Case Presentation

This case represented a 43-year-old woman living in Ourossogui, North-East of Senegal, who was admitted on May 18th, 2021 to the orthopedic department of the regional hospital as shown in **Figure 1**. The motif of consultation was an oozing wound on the back of the sole of her right foot and the patient attested not having any particular pathological history, except hypertension. During the medical examination, she said that signs began in September 2020 with a blackish point with an oozing clear fluid. About two months later, her situation deteriorated such that she could not stand on her feet and developed a fever. She visited a peripheral healthcare facility in November 2020, where she received aseptic cleaning and an antibiotic treatment that was presumed to be cotrimoxazole. With a slight improvement, she resumed her daily activities until six months later when her situation severely worsened, necessitating her admission to the regional hospital.

At the admission, the wound appeared slightly budding and suppurating, and the patient was taken to the orthopedic department for surgical excision. A pus sample was collected for microbiological analysis. The results returned the presence of Gram-negative bacilli suspected to be a *Yersinia pestis*, which was resistant to

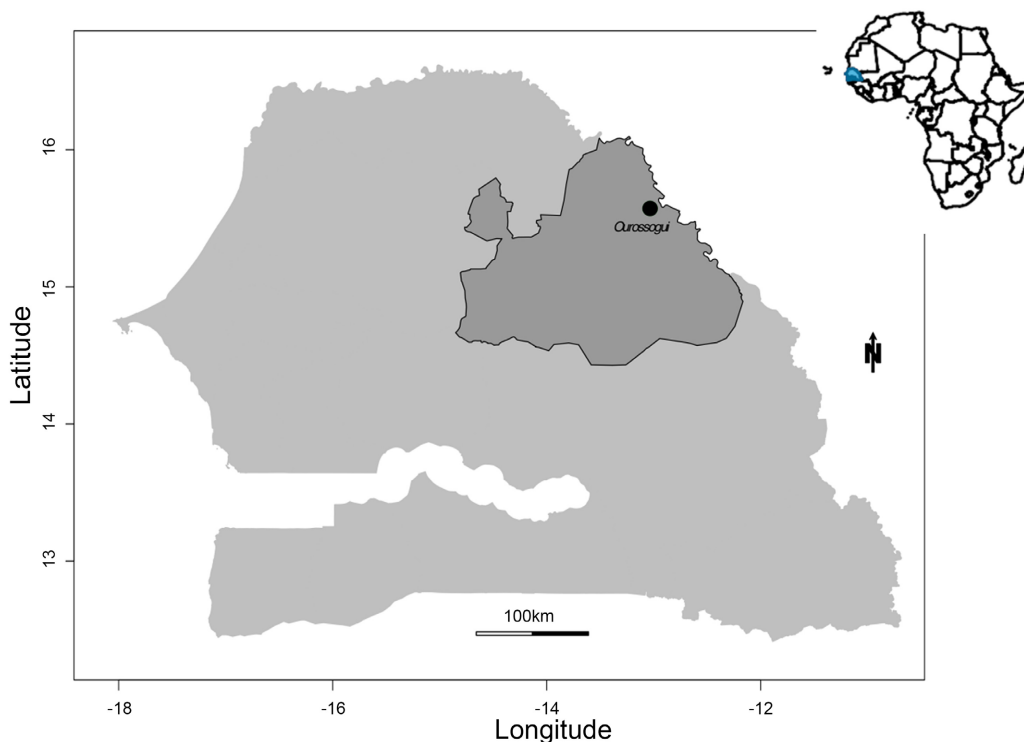


Figure 1. Map of Senegal, highlighting Ourossogui area, where the case was investigated. (Map representation was done by R software).

aztreonam, cephalothin, ceftriaxone, chloramphenicol, and colistin. Nonetheless, the strain was susceptible to carbapenems (imipenem), aminoglycosides (gentamicin, kanamycin, tobramycin), quinolones (ciprofloxacin), and penicillin's (ticarcillin, Amoxicillin-clavulanic acid) (see **Supplementary Table**). Thereafter, the patient was treated with a combination of intravenous antibiotics (clavulanic acid, Clavujet for 1 g × 3/day), antalgic (Perfalgan for 1 g × 3/day and Dynapar 1 amp × 2/day), and anticoagulant (Lovenox 0.4 mg/day). After two weeks, she showed a positive evolution and was released from the hospital on June 1st, 2021 for home or nursing office care. She was following up for at least 4 weeks with aseptic cleaning, and from the latest news, her health condition was stable, even though she was not completely healed. It must be stressed that results on *Yersinia pestis* detection should be taken with caution, due to the drastically decreasing incidence of plague in Senegal and overall in Africa since 1949 [4]. Since plague is a reportable disease in Senegal, an epidemiological investigation was initiated and a wound swab was collected on the day of the patient discharge and sent to Institut Pasteur de Dakar (IPD) for confirmation and further investigation. Microbiological analysis revealed Gram-negative cocobacilli. Culture on different media (chocolate, MacConkey and bromocresol purple agars) showed smooth and rounded colonies identified as *A. baumannii* with API biochemical tests. Antimicrobial susceptibility testing performed by disk diffusion and automated (Vitek 2 system, bioMérieux) methods revealed resistance to penicillin's (ticarcillin, piperacillin, ticarcillin-acid clavulanic, piperacillin-tazobactam), sulfonamides (trimethoprim-sulfamethoxazole), carbapenems (meropenem, eropenem, imipenem), cephalosporins (cefotaxime, ceftazidime, cefepime), gentamicin, tetracyclines (tetracycline, minocycline) and fluoroquinolones (ciprofloxacin), and susceptibility to colistin, amikacin, and tobramycin (**Table 1**). Based on these results, we classified this clone as an XDR *A. baumannii* that is resistant to at least one drug from all categories except two or fewer [5].

Table 1. Antimicrobial susceptibility testing in XDR *Acinetobacter baumannii*.

Antibiotic class	Antibiotics	value (mm)	value (mg/L)	Interpretation
Penicillin's	Piperacillin-tazobactam	6	≥128	R
	Piperacillin	6	≥128	R
	Ticarcillin	6	≥128	R
	Ticarcillin-clavulanic acid	6	≥128	R
Aminoglycosides	Tobramycin	21	≤1	S
	Amikacin	22	≤2	S
	Gentamicin	6	≥16	R
Cephalosporines	Cefotaxime	6	NT	R
	Ceftazidime	6	≥64	R
	Cefepime	10	NT	R

Continued

	meropenem	6	≥16	R
Carbapenems	Imipenem	NT	≥16	R
	Ertapenem	6	NT	R
Quinolones	Ciprofloxacin	6	≥4	R
Sulphonamides	Trimethoprim-sulfamethoxazole	6	≥40	R
Tetracycline	Minocycline	NT	≥16	R
	Tetracycline	6	NT	R
Miscellaneous	Colistin	NT	≤0.5	S

R: resistant; S: sensitive; NT: not tested; mm: millimetre; mg/L: milligram per litre.

3. Discussion

The emergence and dissemination of MDR *A. baumannii* are a global public health concern. *A. baumannii* belongs to the ESKAPE group of pathogens, which are characterized by their ability to rapidly develop resistance to numerous antibiotics. In Senegal, the epidemiology of MDR *A. baumannii*, including carbapenem-resistant clones, is poorly documented. Available literature shows its presence both at the community and hospital level, even though no epidemiological data on its burden is available yet [6] [7]. From our results, we cannot firmly conclude that the isolated XDR *A. baumannii* was the aetiological agent of the wound that the patient suffered from. It was unfortunate that the suspected *Y. pestis* clone initially isolated was not stored, preventing any confirmation. However, since the patient's condition improved following the initial treatment and given that *A. baumannii* was isolated 13 days after admission corresponding to her day of release, we believe of a case of hospital-acquired infection, likely during wound cleaning. In Africa, the prevalence of hospital-acquired infections (HAIs) ranges from 10% to 60%, and they are the third, second and first leading causes of maternal mortality, early neonatal mortality and postoperative morbidity, respectively. HAI prevalence is estimated at 10% in Benin, 10.9% in Senegal, 12% in the Ivory Coast, and 14% in Mali [8]. A review that examined the incidence and prevalence of HAIs by *A. baumannii* in Europe revealed that this bacterium is more frequent (>20%) than other common nosocomial pathogens like *Klebsiella pneumoniae*, *Escherichia coli*, and *Staphylococcus aureus* [9]. A similar pattern was described in Southeast Asia [10], China [11], and Latin America [12], but it was different in the United States, where HAIs with *Acinetobacter* spp in ICUs were estimated to be only 1.1% [13]. Data on the burden of MDR *A. baumannii* infections, including carbapenem-resistant clones are very scarce in Africa. Nonetheless, available data suggest a widespread distribution of carbapenemase-producing strains with prevalence ranging from 2.3% to 67.7% in North Africa and 9% to 60% in sub-Saharan Africa [14]. Studies to delineate the magnitude and spread of *A. baumannii* infections across Africa are therefore urgently needed. To our knowledge, this study is the first reporting a potential

HAI with XDR *A. baumannii* in Senegal. It stresses the importance to strengthening and enforcing guidelines for patient management, especially those in ICUs. Moreover, surveillance systems should be implemented to study the evolution, dynamic of transmission and biological role of important nosocomial pathogens like *A. baumannii*.

4. Conclusion

Emergence of MDR *A. baumannii* in clinical settings is of critical importance. This case illustrates a potential HAI XDR *A. baumannii* infection in Senegal, where data on this bacterium are scarce. This stresses the need of an active surveillance of *A. baumannii* in LMIC hospitals as well the development and enforcement of effective guidelines for patient management.

Acknowledgements

We thank the ministry of Health of Senegal and the medical staff from Ourosogui hospital for the coordination of the case investigation and intervention.

Authors and Contributors

Conceptualization: CF, BSB, YD; methodology: OS, FPL; validation: CF, OS, FPL, YD; investigation: BD; original draft preparation: CF; writing-review and editing: CF, OS, FPL, BSB, YD. All authors have read and agreed to the published version of the manuscript.

Ethical Approval

The authors declare that the privacy of the patient was respected according to the CIOMS rules, regarding the privacy of the data collected.

Conflicts of Interest

All the authors declare no conflict of interest.

References

- [1] Erbay, A., Idil, A., Gözel, M.G., Mumcuoğlu, I. and Balaban, N. (2009) Impact of Early Appropriate Antimicrobial Therapy on Survival in *Acinetobacter baumannii* Bloodstream Infections. *International Journal of Antimicrobial Agents*, **34**, 575-579. <https://doi.org/10.1016/j.ijantimicag.2009.07.006>
- [2] Tacconelli, E., *et al.* (2018) Discovery, Research, and Development of New Antibiotics: The WHO Priority List of Antibiotic-Resistant Bacteria and Tuberculosis. *The Lancet Infectious Diseases*, **18**, 318-327.
- [3] Greene, C., Vadlamudi, G., Newton, D., Foxman, B. and Xi, C. (2016) The Impact of Biofilm Formation and Multidrug Resistance on Environmental Survival of Clinical and Environmental Isolates of *Acinetobacter baumannii*. *American Journal of Infection Control*, **44**, e65-e71. <https://doi.org/10.1016/j.ajic.2015.12.012>
- [4] Davis, D.H.S. (1953) Plague in Africa from 1935 to 1949. *Bulletin of the World Health Organization*, **9**, 665-700.

- [5] Magiorakos, A.-P., et al. (2012) Multidrug-Resistant, Extensively Drug-Resistant and Pandrug-Resistant Bacteria: An International Expert Proposal for Interim Standard Definitions for Acquired Resistance. *Clinical Microbiology and Infection. European Society of Clinical Microbiology and Infectious Diseases*, **18**, 268-281. <https://doi.org/10.1111/j.1469-0691.2011.03570.x>
- [6] Kempf, M., et al. (2012) Carbapenem Resistance and *Acinetobacter baumannii* in Senegal: The Paradigm of a Common Phenomenon in Natural Reservoirs. *PLoS ONE*, **7**, e39495. <https://doi.org/10.1371/journal.pone.0039495>
- [7] Diene, S.M. et al. (2013) Emergence of the OXA-23 Carbapenemase-Encoding Gene in Multidrug-Resistant *Acinetobacter baumannii* Clinical Isolates from the Principal Hospital of Dakar, Senegal. *International Journal of Infectious Diseases*, **17**, e209-e210. <https://doi.org/10.1016/j.ijid.2012.09.007>
- [8] Recommendations on the Fight against Nosocomial Infections Compliance in Health Facilities of Yaounde (Cameroon). *International Journal of Scientific Research and Management*. <https://ijsrm.in/index.php/ijsrm/article/view/2301>
- [9] Ayobami, O., Willrich, N., Harder, T., Okeke, I.N., Eckmanns, T. and Markwart, R. (2019) The Incidence and Prevalence of Hospital-Acquired (Carbapenem-Resistant) *Acinetobacter baumannii* in Europe, Eastern Mediterranean and Africa: A Systematic Review and Meta-Analysis. *Emerging Microbes & Infections*, **8**, 1747-1759. <https://doi.org/10.1080/22221751.2019.1698273>
- [10] Ling, M.L., Apisarnthanarak, A. and Madriaga, G. (2015) The Burden of Health-care-Associated Infections in Southeast Asia: A Systematic Literature Review and Meta-Analysis. *Clinical Infectious Diseases*, **60**, 1690-1699. <https://doi.org/10.1093/cid/civ095>
- [11] Yue, D., et al. (2017) Hospital-Wide Comparison of Health Care-Associated Infection among 8 Intensive Care Units: A Retrospective Analysis for 2010-2015. *American Journal of Infection Control*, **45**, e7-e13. <https://doi.org/10.1016/j.ajic.2016.10.011>
- [12] Luna, C.M., Rodriguez-Noriega, E., Bavestrello, L. and Guzmán-Blanco, M. (2014) Gram-Negative Infections in Adult Intensive Care Units of Latin America and the Caribbean. *Critical Care Research and Practice*, **2014**, 480463. <https://doi.org/10.1155/2014/480463>
- [13] McCann, E., et al. (2018) Carbapenem-Nonsusceptible Gram-Negative Pathogens in ICU and Non-ICU Settings in US Hospitals in 2017: A Multicenter Study. *Open Forum Infectious Diseases*. <https://doi.org/10.1093/ofid/ofy241>
- [14] Manenzhe, R.I., Zar, H.J., Nicol, M.P. and Kaba, M. (2015) The Spread of Carbapenemase-Producing Bacteria in Africa: A Systematic Review. *Journal of Antimicrobial Chemotherapy*, **70**, 23-40. <https://doi.org/10.1093/jac/dku356>

Supplementary Table: Antimicrobial Susceptibility Testing in *Yersinia pestis*

Antibiotic class	Antibiotics	Interpretation
Penicillin's	Amoxicillin	Resistant
	Amoxicillin-clavulanic acid	Sensitive
	Ticarcillin	Sensitive
carbapenems	Meropenem	Sensitive
cephalosporines	Azitreonam	Resistant
	Cephalotine	Resistant
	Ceftriaxone	Resistant
Aminoglycosides	Gentamicin	Sensitive
	Tobramycin	Sensitive
	Kanamycin	Sensitive
Phenicol's	Chloramphenicol	Resistant
quinolones	Ciprofloxacin	Sensitive
miscellaneous	Colistin	Resistant