

Simultaneous Repair of Para-Umbilical Hernia during Cesarean Section (CS): A Novel Approach

Eman A. Eltokhy¹, Ibtisam Shehta Harera¹, Loay M. Gertallah¹, Walid A. Mawla¹, Ahmed Mahmoud Abdou², Entsar R. Mahdy², Ahmed Embaby³

¹Department of General Surgery, Faculty of Medicine, Zagazig University, Zagazig, Egypt

²Department of Gynecology and Obstetrics, Faculty of Medicine, Zagazig University, Zagazig, Egypt

³Department of Internal Medicine, Faculty of Medicine, Zagazig University, Zagazig, Egypt

Email: olaharb2015@gmail.com

How to cite this paper: Eltokhy, E.A., Harera, I.S., Gertallah, L.M., Mawla, W.A., Abdou, A.M., Mahdy, E.R. and Embaby, A. (2018) Simultaneous Repair of Para-Umbilical Hernia during Cesarean Section (CS): A Novel Approach. *Surgical Science*, 9, 233-242.

<https://doi.org/10.4236/ss.2018.97028>

Received: June 24, 2018

Accepted: July 20, 2018

Published: July 23, 2018

Copyright © 2018 by authors and Scientific Research Publishing Inc.

This work is licensed under the Creative Commons Attribution International License (CC BY 4.0).

<http://creativecommons.org/licenses/by/4.0/>



Open Access

Abstract

Background: Pregnant women that are complaining from paraumbilical hernia postpone its repair until they get birth. We hypothesized that it will be better to perform hernia repair of such type of hernia simultaneously during performing cesarean section (CS) which will help to decrease future morbidity re-operation, avoid complications and further skin incision. In this study we aimed to compare the value of performing para-umbilical hernia repair simultaneously during performing CS through the same skin incision with performing para-umbilical hernia repair simultaneously during performing CS through another infra- or supra-umbilical skin incision and performing para-umbilical hernia repair electively later on after healing of a CS skin incision in relation to clinical recovery and patient satisfaction. **Patients and Methods:** This is a prospective cohort study, where we included 45 pregnant female patients who will give birth by CS, and we have divided them into 3 groups: the first group of patients (A) included 15 patients that undergoing paraumbilical hernia repair by pre-peritoneal mesh insertion through CS incision, the second group of patients (B) included 15 patients that undergoing paraumbilical hernia repair by infra- or supra-umbilical incision during CS incision and the third group of patients (C) included 15 patients that undergoing paraumbilical hernia repair by infra- or supra-umbilical incision later on after healing of the CS wound. We have evaluated advantages of that novel approach e.g. operation time, severity of pain, peri-partum and post-operative complications, financial cost, duration of hospital stay, clinical recovery, mesh rejection, and patient satisfaction. **Results:** In group A there is shorter duration of hospital stay, no new skin incision ($p < 0.001$), low incidence of early

complications like umbilical ischemia, wound infection, wound dehiscence, seroma, skin flaps ischemia ($p = 0.027$), low incidence of late complications like painful ugly scar and mesh rejection ($p = 0.05$). Group A showed the highest incidence of clinical recovery and patients' satisfaction ($p > 0.002$).

Conclusions: Performing para-umbilical hernia repair by insertion of a pre-peritoneal mesh simultaneously during performing CS through the same skin incision is the best method of management of para-umbilical hernia in pregnant woman.

Keywords

Para-Umbilical Hernia, Pre-Peritoneal Mesh Insertion, Pregnancy, Cesarean Section, Outcome

1. Introduction

Para-umbilical hernias are most common in females than males. Pregnancy may lead to occurrence of umbilical hernia, or allow a preexisting one to be more apparent, due to increasing intra-abdominal pressure progressively. Para-umbilical hernia may be diagnosed during 1st, 2nd, or 3rd pregnancies and its presenting symptoms most probably present in the 2nd trimester in most patients [1]. And surgical management of para-umbilical hernias is considered the commonest surgical procedures. Para-umbilical hernias that usually presented in pregnancy have an incidence of approximately 1:2000, and are commonly treated after delivery as an elective operation [2]. But, para-umbilical hernia repair during cesarean section (CS) with insertion of a pre-peritoneal mesh is still not common surgical technique [3]. CSs have been practiced over most centuries and recently they have become a safe procedure that pregnant women are requesting it to deliver their baby even in the absence of indication for such procedure [4]. We hypothesized that it will be better to perform hernia repair of such type of hernia simultaneously during performing CS which will help to decrease future morbidity re-operation, avoid complications and further skin incision. Combination of para-umbilical hernia repair during CS is undocumented until case report from 1987 and another case series of eight patients having inguinal and umbilical hernia that have been repaired during cesarean delivery. But, that practice is still uncommon, because most obstetricians try to avoid any additional risk on the mother from combined surgery as paraumbilical hernia repair is rarely urgent [5].

In this study we aimed to compare the value of performing para-umbilical hernia repair simultaneously during performing CS through the same skin incision with performing para-umbilical hernia repair simultaneously during performing CS through another infra- or supra-umbilical skin incision and performing para-umbilical hernia repair electively later on after healing of a CS skin

incision in relation to clinical recovery and patient satisfaction.

2. Patients & Methods

2.1. Study Design

1) This is a prospective cohort study in that were performed in departments of; General Surgery, Gynecology & Obstetrics, Internal Medicine, Zagazig University Hospitals, after local ethics committee Approval.

2) Sample size: where we included 45 pregnant female patients we have divided them into 3 groups the first group of patients (A) included 15 patients that undergoing para-umbilical hernia repair by pre-peritoneal mesh insertion through CS incision, the second group of patients (B) included 15 patients that undergoing paraumbilical hernia repair by infra- or supra-umbilical incision during CS incision and the third group of patients (C) included 15 patients that undergoing paraumbilical hernia repair by infra- or supra-umbilical incision later on after healing of the CS wound.

3) Patient's data:

- All pregnant full term female patients with age from 25 - 35 years old.
- All participants were planned CS patients, and had no serious obstetric pathology.
- Reducible umbilical swelling was present in all cases, and the diagnosis of umbilical hernia was also confirmed by ultrasonography preoperatively.
- The surgical procedure was explained in detail to the patients, and then a written informed consent form was obtained from all patients.
- All patients are not diabetic, not hypertensive, no PROM, no neonatal problems.
- We have excluded all patients with any comorbidity e.g. diabetes or hypertension.
- We have excluded all patients with premature rupture of membranes (PROM) or fetal problems.
- Any serious complication during CS is a contraindication to mesh repair of umbilical hernia.

2.2. Preoperative Preparation

All patients were subjected to the following:

- 1) Full history taking.
- 2) Clinical examination with assurance of complete reducibility by palpating the while margin of the hernia defect after reduction of the hernia contents.
- 3) Preoperative investigations:
 - C.B.C.
 - Live & renal function tests.
 - Plain X-ray chest.
 - Ultrasonography.

Antibiotic prophylaxis with 1 g cephalosporin was given to all included pa-

tients in our study intravenously after extraction of the placental.

2.3. Operative Details

The type of anesthesia: General anesthesia with endotracheal intubation. After disinfection of the surgical area with povidone iodine, the operation begins with about 10 cm classic Pfannenstiel incision. Exposure of the uterus was provided with routine steps, and a standard CS was performed by the obstetrics team.

After the uterine wound has been closed carefully, the operative wound was washed with saline 0.9%. Then, the pre-peritoneal space was entered between rectus muscle and peritoneum with blunt dissection by the general surgery team.

Group: A

1) Position: the patient lies in supine position after end of procedures of CS operation in the form of closure of uterus and doing peritoneal toilet with adequate haemostasis then the patient position should be changed to Trendelenburg position to make viscera away.

2) The operative technique:

From inside abdominal cavity the content of hernia is reduced pathological contents were excised.

Peritoneal incision around defect in posterior sheath (neck of hernia) then upper and lower peritoneal flaps are dissected.

The hernial sac was pulled from inside and excised.

If the umbilicus was distorted it will be fixed with (vicryl suture 2/0) to sheath.

Closure of defect by using continuous sutures vicryl 1.

Fixation of proline mesh (6 × 11) to posterior aspect of sheath by continuous and interrupted sutures proline 2/0.

Closure of peritoneal flaps over mesh without drain.

Closure of CS wound.

Group: B & Group: C

The patient is lying supine. Infra- or supra-umbilical incision is done according to the site of hernia. Skin flaps were created. Dissection of sac and opening it from the neck then reduction of the content. Closure of defect. Fixation of the mesh by interrupted proline sutures. Closure in layers with subcutaneous suction drain.

Good peritoneal toilet and closure of the CS wound was done as usual.

2.4. Postoperative Follow up

- All patients were followed up in the early postoperative period for the following:
 - Length of hospital stays (1 - 2 days).
 - Early wound infection or Ischemia, dehiscence or seroma.
 - Post-operative pain.
 - Postoperative pain was evaluated by the average consumption of analgesic

ampules given on patient demand during the first week.

- All patients received a routine intramuscular dose of 75-mg dose of diclofenac sodium (Voltaren IM; Novartis, Basel, Switzerland) twice on the day of the operation.
- Total analgesic usage was registered during the first postoperative week.
- The patients were followed-up postoperatively daily until discharge from the hospital, then twice weekly as an outpatient for the first 2 weeks, then 1 month later, and finally every 6 month.

2.5. Statistical Analysis

Data of our patients were computerized and analyzed statistically using SPSS program (Statistical Package for Social Science). Chi square test (χ^2) and Fisher exact was used to calculate difference between qualitative variables. p -value ≤ 0.05 is considered significant, $p < 0.001$ is considered highly significant while, $p > 0.05$ is considered Non-significant difference.

3. Results

3.1. Pre-Operative Results: Table 1, Figure 1

Main features and clinical data of our patients are included in **Table 1**; Group A included 15 patients. Group B included 15 patients, group C included 15 patients no statistically detected difference between all groups as regard age distribution or the primary location of the hernia.

3.2. Operative Findings: Table 2, Figure 2

Group A patients are better than the other both groups regarding no new skin incision, no drain was used that was statistically significant ($p < 0.001$).

3.3. Postoperative Results: Table 2

We found that Group A patients are better than the other both groups regarding decreasing low incidence of early complications like umbilical ischemia, wound infection, wound dehiscence, seroma, skin flaps ischemia ($p = 0.027$).

Low incidence of late complications like painful ugly scar and mesh rejection ($p = 0.05$).

Group A showed the highest incidence of clinical recovery and patients' satisfaction ($p > 0.002$).

There were no statistically significant differences between all groups regarding presence of skin flaps ischemia.

4. Discussion

Repairing hernia during C-section is an approach of surgical management of such lesion. But, performing both surgeries simultaneously neither were nor recommended until the 2000s [1]. As paraumbilical hernias are liable to complications e.g. incarceration and enlargement if not treated, so it will be better to repair

Table 1. Main clinical data and operative details of all included patients in our study.

		Surgical procedure			All N = 45	p value
		Pre-peritoneal mesh through CS incision	Infra or supra umbilical incision during CS	Infra or supra umbilical incision later		
		N = 15	N = 15	N = 15		
Age, year	25y	3 (20.0%)	2 (13.3%)	1 (6.7%)	6 (13.3%)	0.938
	30y	7 (46.7%)	8 (53.3%)	9 (60.0%)	24 (53.3%)	
	33y	3 (20.0%)	2 (13.3%)	2 (13.3%)	7 (15.6%)	
	35y	2 (13.3%)	3 (20.0%)	3 (20.0%)	8 (17.8%)	
Location of the umbilical hernia	Infra-umbilical	6 (40.0%)	8 (53.3%)	8 (53.3%)	22 (48.9%)	0.701
	Supra-umbilical	9 (60.0%)	7 (46.7%)	7 (46.7%)	23 (51.1%)	
Skin incision	No new skin incision	15 (100.0%)	0 (0.0%)	0 (0.0%)	15 (33.3%)	<0.001
	Infra-umbilical	0 (0.0%)	8 (53.3%)	8 (53.3%)	16 (35.6%)	
	Supra-umbilical	0 (0.0%)	7 (46.7%)	7 (46.7%)	14 (31.1%)	
Umbilical ischemia		0 (0.0%)	4 (26.7%)	2 (13.3%)	6 (13.3%)	0.099
Surgical operative time (min)	30	10 (66.7%)	0 (0.0%)	0 (0.0%)	10 (22.2%)	<0.001
	45	5 (33.3%)	0 (0.0%)	0 (0.0%)	5 (11.1%)	
	60	0 (0.0%)	9 (60.0%)	9 (60.0%)	18 (40.0%)	
	90	0 (0.0%)	3 (20.0%)	3 (20.0%)	6 (13.3%)	
	120	0 (0.0%)	3 (20.0%)	3 (20.0%)	6 (13.3%)	
Location of the mesh	Sublay	15 (100.0%)	6 (40.0%)	4 (26.7%)	25 (55.6%)	<0.001
	Onlay	0 (0.0%)	9 (60.0%)	11 (73.3%)	20 (44.4%)	
Use of drains		0 (0.0%)	15 (100.0%)	15 (100.0%)	30 (66.7%)	<0.001
Financial over load		0 (0.0%)	15 (100.0%)	15 (100.0%)	30 (66.7%)	<0.001
Clinical satisfaction		15 (100.0%)	7 (46.7%)	7 (46.7%)	29 (64.4%)	0.002
Cosmetic satisfaction		15 (100.0%)	7 (46.7%)	7 (46.7%)	29 (64.4%)	0.002
Duration of hospital stay, Days	1	13 (86.7%)	0 (0.0%)	0 (0.0%)	13 (28.9%)	<0.001
	2	0 (0.0%)	1 (6.7%)	1 (6.7%)	2 (4.4%)	
	3	0 (0.0%)	6 (40.0%)	6 (40.0%)	12 (26.7%)	
	4	2 (13.3%)	4 (26.7%)	4 (26.7%)	10 (22.2%)	
	5	0 (0.0%)	4 (26.7%)	4 (26.7%)	8 (17.8%)	

Table 2. Comparison of Postoperative complications among procedures.

		Surgical procedure			All N = 45	p value
		Pre-peritoneal mesh through CS incision	Infra or supra umbilical incision during CS	Infra or supra umbilical incision later		
		N = 15	N = 15	N = 15		
Complications		0 (0.0%)	6 (40.0%)	4 (26.7%)	10 (22.2%)	0.027
Early complications		0 (0.0%)	6 (40.0%)	4 (26.7%)	10 (22.2%)	0.027
Wound infection		0 (0.0%)	6 (40.0%)	4 (26.7%)	10 (22.2%)	0.027
Wound dehiscence		0 (0.0%)	6 (40.0%)	4 (26.7%)	10 (22.2%)	0.027
Seroma		0 (0.0%)	6 (40.0%)	4 (26.7%)	10 (22.2%)	0.027
Skin flaps ischemia		0 (0.0%)	4 (26.7%)	2 (13.3%)	6 (13.3%)	0.099
Late complications		0 (0.0%)	5 (33.3%)	4 (26.7%)	9 (20.0%)	0.050
Painful ugly scar		0 (0.0%)	5 (33.3%)	4 (26.7%)	9 (20.0%)	0.050
Rejection		0 (0.0%)	4 (26.7%)	3 (20.0%)	7 (15.6%)	0.111

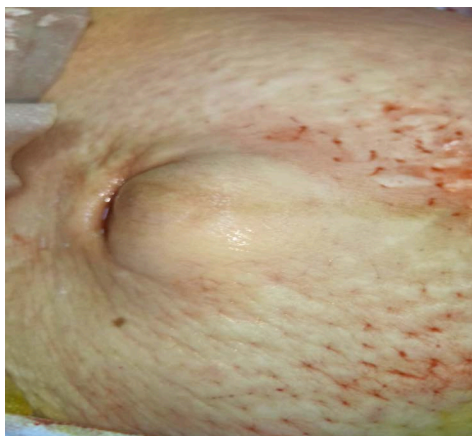

Figure 1. A preoperative appearance of umbilical hernia in a pregnant woman.

them at presentation [6]. In our study we assessed the value of performing paraumbilical hernia repair during CS using a single incision, comparing such approach with paraumbilical hernia repair during CS using 2 incision one for the CS and one for the hernia repair, and with of performing elective paraumbilical hernia repair later on after complete healing of the CS scar. We have found that performing paraumbilical hernia repair during CS using a single incision was the best approach of management that resulted in no increase in complications (notably infection) over other compared procedure. Additionally, our patients were cosmetically, clinically and financially highly satisfied with the combined procedure.

Our results were similar to results of Kulacoglu [1] and Ghnnam *et al.* [5].

The practical benefits of our novel approach were as follows; a 2-in-1 operation, a single incision, single anesthesia, and single hospital stay, more advantages for patient and hospital, lower cost, and better convenience, in addition to avoid the separation of the mother from her baby in case of re-operation.

The obstacle that may face the surgeon during the combine procedure is difficult intraoperative mesh fixation that can be solved by good assistance to allow good traction that was similar to Ghnnam *et al.* [5] opinion.

Obstetric surgeons and General surgeons prefer to postpone hernia repair to avoid increase length of the operative time, increased risk of post-partum complications and may prolong hospitalization.

Our results in addition to results of Ghnnam *et al.* [5], proved that the combined procedure had no risk on the mother, no increased risk of post-partum complications. We found no increase in the operative time but Ghnnam *et al.* [5], stated that hernia repair might prolong the duration of cesarean delivery, but the whole time remained within the normal range for hernia repair in the literature.

We found that no patients in the first group of patients group A have; post-operative infections, seroma or prolonged hospitalization, that was slightly different from results of Ghnnam *et al.* [5], who found that delayed wound

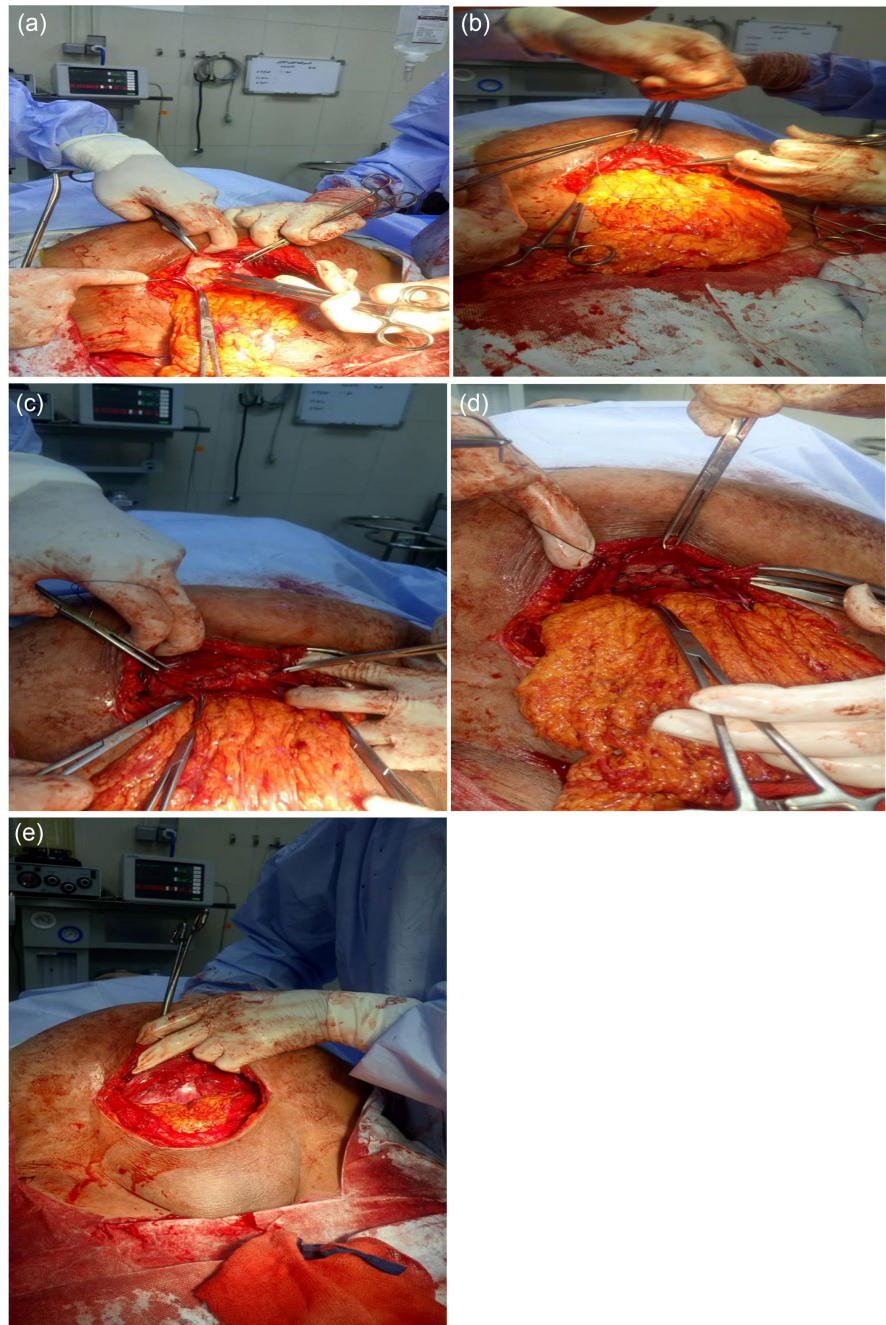


Figure 2. Operative steps of management of paraumbilical hernia during cesarean section: (a) Elevation of peritoneal flaps from posterior sheath; (b) Reduction of the hernia content; (c) Closure of posterior sheath by continuous sutures; (d) fixation of the mesh over the sheath; (e) Closure of peritoneum over the mesh.

healing due to infection in six patients, seroma occurred in three patients such discrepancy may be due to different patient numbers or different follow-up period.

Similar to Ghnnam *et al.* [5], we have found that no prolonged period of hospital stay in patients of group A who are undergoing the combined procedure.

It remains a matter of controversy whether to repair paraumbilical hernia in a

pregnant woman during pregnancy, at cesarean delivery or at the postpartum after involution of the uterus. Many surgeons prefer not to repair the hernia during pregnancy as anesthesia and surgery during pregnancy might precipitate uterine irritability, contraction and induce premature labor, up to 1 week post-operatively [7]. Moreover, the high vascularization of the uterus and collagen remodeling induction by relaxin during pregnancy leads to softening of the tissues predisposing to recurrence of hernia [8]. Gabriele *et al.* 2010 who have reported a study on 28 pregnant women with an umbilical or inguinal hernia who underwent CS and hernia repair simultaneously were compared with 100 patients who only underwent a CS alone and they have concluded that combined surgery is safe and avoids reoperation. Also, Jensen *et al.* concluded that combined hernia repair and CS is the best therapeutic option [9]. Both studies proved similar results to ours. Some pregnant women having para-umbilical hernia refused to have simultaneous hernia repair at the time of CS so in our study patient consent is a must.

Oma *et al.* [10] & Buch *et al.* [11] prefer to do elective hernia repair electively after healing of the CS incision in a period from 5 months to 3 years after delivery. Surgeons who refused such procedure described hazards of repair during CS e.g. changes in Muscles and Fascial Structures during Pregnancy, the rectus abdominis muscle is changed during pregnancy with a significant increase in muscle length, separation, and changes in angles of insertions as the pregnancy progressed and the ability to stabilize the pelvis is decreased [1].

Surgit *et al.* [3], proved results like us regarding simplicity, safety and efficacy, but also they did not recommend the combined surgical procedures because of the widespread belief regarding the association between combined operations, maternal and perinatal complications [3]. As patient satisfaction is one of the most important signs of success of all novel surgical methods. In our study, all patients were satisfied to the degree that they recommend this approach to all pregnant women with hernia. It is clear that one of the benefits of this combined procedure is avoiding the separation of mother from newborn caused by the second operation. It appears that this advantage led to an increase in the satisfaction of our patients.

5. Summary

In our study we have compared performing paraumbilical hernia repair as a combined procedure with CS through the same incision with performing paraumbilical hernia repair as a combined procedure with CS through 2 incisions one of the CS and the other for hernia repair and with paraumbilical hernia repair as elective procedure later on after healing of the scar of CS and we have found that performing paraumbilical hernia repair as a combined procedure with CS through the same incision is the best procedure. As, cesarean delivery combined with paraumbilical hernia repair is well accepted us regarding simplicity, safety and efficacy.

6. Conclusion

Performing para-umbilical hernia repair by insertion of a pre-peritoneal mesh simultaneously during performing CS through the same skin incision is the best method of management of para-umbilical hernia in pregnant woman.

Recommendations

Confirmation of these results needs a larger study so as to establish if combined CS and hernia repair as a novel recommended procedure.

References

- [1] Kulacoglu, H. (2018) Umbilical Hernia Repair and Pregnancy: Before, during, after... *Frontiers in Surgery*, **5**, 1. <https://doi.org/10.3389/fsurg.2018.00001>
- [2] Ochsenbein-Kolble, N., Demartines, N., Ochsenbein-Imhof, N., *et al.* (2004) Cesarean Section and Simultaneous Hernia Repair. *Archives of Surgery*, **139**, 893-895. <https://doi.org/10.1001/archsurg.139.8.893>
- [3] Surgit, O., Gumus, İ.İ., Kılıç, M.Ö., *et al.* (2017) Combined Procedure of Cesarean Delivery and Preperitoneal Mesh Repair for Inguinal Hernia: An Initial Experience. *Asian Journal of Surgery*, **40**, 357-361. <https://doi.org/10.1016/j.asjsur.2015.12.004>
- [4] Simm, A. and Ramoutar, P. (2005) Caesarean Section: Techniques and Complications. *Current Obstetrics & Gynaecology*, **15**, 80-86. <https://doi.org/10.1016/j.curobgyn.2004.12.003>
- [5] Ghnnam, W.M., Helal, A.S., Fawzy, M., *et al.* (2009) Paraumbilical Hernia Repair during Cesarean Delivery. *Annals of Saudi Medicine*, **29**, 115-118. <https://doi.org/10.4103/0256-4947.51798>
- [6] Rodriguez, A. and Hinder, R. (2004) Surgical Management of Umbilical Hernia. *Operative Techniques in General Surgery*, **6**, 156-164. <https://doi.org/10.1053/j.optechgensurg.2004.07.006>
- [7] Kort, B., Katz, V.L. and Watson, W.J. (1993) The Effect of Nonobstetric Operation during Pregnancy. *Surgery, Gynecology & Obstetrics*, **177**, 371-376.
- [8] Bani, D. (1997) Relaxin: A Pleiotropic Hormone. *General Pharmacology*, **28**, 13-22. [https://doi.org/10.1016/S0306-3623\(96\)00171-1](https://doi.org/10.1016/S0306-3623(96)00171-1)
- [9] Jensen, K.K., Henriksen, N.A. and Jorgensen, L.N. (2015) Abdominal Wall Hernia and Pregnancy: A Systematic Review. *Hernia*, **19**, 689-696. <https://doi.org/10.1007/s10029-015-1373-6>
- [10] Oma, E., Bay-Nielsen, M., Jensen, K.K., *et al.* (2017) Primary Ventral or Groin Hernia in Pregnancy: A Cohort Study of 20,714 Women. *Hernia*, **21**, 335-339. <https://doi.org/10.1007/s10029-017-1618-7>
- [11] Buch, K.E., Tabrizian, P. and Divino, C.M. (2008) Management of Hernias in Pregnancy. *Journal of the American College of Surgeons*, **207**, 539-542. <https://doi.org/10.1016/j.jamcollsurg.2008.04.030>