

# Mandibular Sequela Noma: Metal Plate Repair Associated with a Submental Flap, about One Case

Saliou Adam<sup>1,2\*</sup>, Hamza Dolès Sama<sup>3</sup>, Haréfétéguéna Bissa<sup>1,2</sup>, Palokina Agoda<sup>4</sup>, Winga Foma<sup>2</sup>, Essobozou Plaoudézina Pegbessou<sup>5</sup>, Bathokédéou Amana<sup>6</sup>, Esham Boko<sup>5</sup>, Eyawèlohn Kpemissi<sup>2</sup>

<sup>1</sup>Department of Stomatology and Maxillofacial Surgery at Sylvanus Olympio University Teaching Hospital of Lomé, Lomé, Togo

<sup>2</sup>Department of ENT at Sylvanus Olympio University Teaching Hospital of Lomé, Lomé, Togo

<sup>3</sup>Department of Anesthesia and Intensive Care at Sylvanus Olympio University Teaching Hospital of Lomé, Lomé, Togo

<sup>4</sup>Department of Stomatology at Campus University Teaching Hospital of Lomé, Lomé, Togo

<sup>5</sup>Department of ENT at Campus University Teaching Hospital of Lomé, Lomé, Togo

<sup>6</sup>Department of ENT at Regional Hospital of Lomé, Lomé, Togo

Email: \*saliou.adam1@yahoo.com

**How to cite this paper:** Adam, S., Sama, H.D., Bissa, H., Agoda, P., Foma, W., Pegbessou, E.P., Amana, B., Boko, E. and Kpemissi, E. (2019) Mandibular Sequela Noma: Metal Plate Repair Associated with a Submental Flap, about One Case. *Open Journal of Stomatology*, 9, 175-180.  
<https://doi.org/10.4236/ojst.2019.97018>

**Received:** June 11, 2019

**Accepted:** July 9, 2019

**Published:** July 12, 2019

Copyright © 2019 by author(s) and Scientific Research Publishing Inc. This work is licensed under the Creative Commons Attribution International License (CC BY 4.0).

<http://creativecommons.org/licenses/by/4.0/>



Open Access

## Abstract

**Introduction:** Noma is a severe and mutilating gangrenous stomatitis of the orofacial sphere, starting on periodontal side. It is rare and occurs mainly in children that land is weakened by malnutrition. We report a case of mandibular sequela noma requiring plastic surgery. **Clinical case:** This was a 7-year-old patient with moderate acute malnutrition. She was referred from a peripheral care facility for gangrene of the left cheek, communicating the oral cavity with the outside, through an orostoma. This lesion had been evolving for two months, with a tendency towards progressive destruction of the soft tissues of the cheek and the mandibular bone. The neck and facial CT-Scan demonstrated destruction of the mandibular bone exposed on the left side, without signs of tumor invasion. After correction of nutritional status and local infection, the patient was treated with a metal plate recovered by sub-mental flap. **Conclusion:** Noma is a severe gangrenous stomatitis that transforms patients' faces into ghosts by destroying soft tissues and underlying bone planes. The management of his sequelae is surgical, sometimes using complex techniques of plastic surgery.

## Keywords

Noma, Sequelae, Plastic Surgery, Metal Plate, Sub-Mental Flap

## 1. Introduction

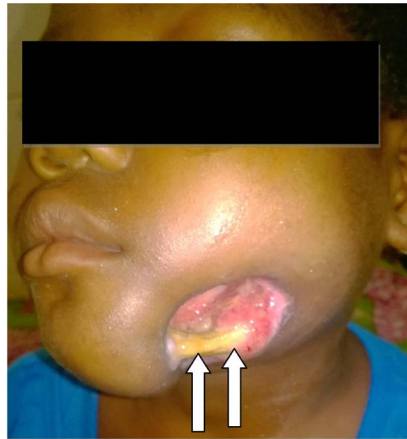Noma is a gangrenous stomatitis of the orofacial sphere, whose starting point is

endo-oral. It is an ulcerative process of the soft tissues and underlying bone planes. It is a mutilating condition that turns the patient's face into a "ghost". The annual incidence of noma is estimated at between 100,000 and 140,000 cases; the exact statistics remain difficult to be specified [1] [2]. Noma mainly affects children weakened by malnutrition and severe childhood diseases in Africa, and is therefore preventable [3] [4]. Patients with noma sequelae are stigmatized and socially marginalized. The contributing factors of noma are an indicator of poverty, hence the aphorism "Face of misery" given to noma because of aesthetic and functional sequelae left on the face [5]. Surgical means including some flaps have been used to deal with functional or aesthetic sequelae of the noma [6] [7]. We report the case of a mandibular sequelae noma that repairs required complex methods of plastic surgery.

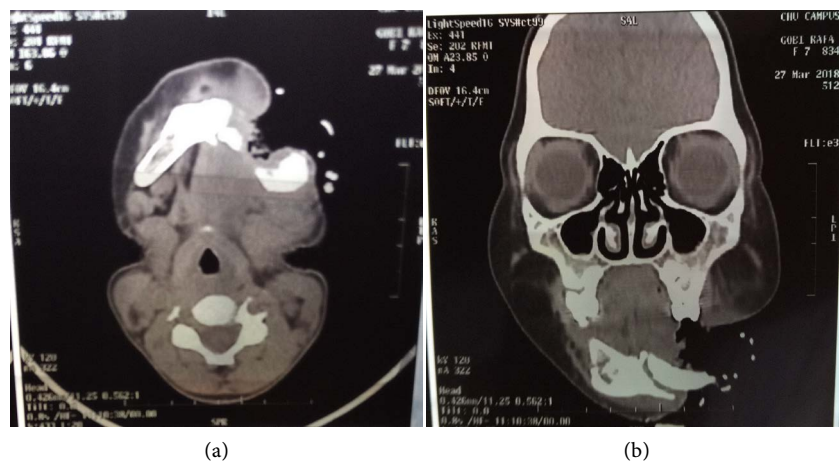
## 2. Case Report

It was a 7-year-old patient, referred from a peripheral care facility for gangrene of the left cheek. This lesion communicated the oral cavity with the outside, through an orostoma. The lesion had been evolving for two months, with a tendency to progressive destruction of the soft tissues of the cheek and the mandibular bone. The patient is the eighth child of a peasant family with precarious living conditions. The patient was reported to have visited several peripheral health care centers in her area where no specific diagnosis had been made. And the lesion progressed despite treatment. It was at the Regional level 2 Hospital that the diagnosis of noma was made. This case has been notified to the national program for non-communicable diseases. Then that entity made the necessary arrangements for the patient to be referred to the Department of Stomatology and Maxillofacial Surgery in Sylvanus Olympio University Teaching Hospital for better care. The interrogation found no personal or family pathological antecedent. The patient complained of difficulty eating properly due to the outcome of food through the orostoma. The general clinical examination noted signs of moderate acute malnutrition. Face examination revealed significant loss of substance from the left cheek as a large punch, exposing the necrotic mandibular bone (**Figure 1**). This necrotic lesion was oval, soiled, and did not bleed on contact. It measured about 9 cm × 5 cm. There were no neck lymphadenopathies or mandibular ones. Oral examination showed a limitation of mouth opening at 25 mm, defective oral hygiene with multiple caries; the rest of the mucosa and surrounding organs were healthy. The neck and facial CT-Scan demonstrated the destruction of the left side mandibular bone that was exposed and the absence of signs of tumor invasion (**Figure 2(a)**, **Figure 2(b)**).

At first, the local infection was dried by local treatment (Polyvidone iodine) and bi antibiotic therapy (amoxicillin-clavulanic acid and metronidazole) by the general route for 15 days. Then we corrected the malnutrition with a hyper-proteic and high calorie diet enteral for three weeks. In a second step, the surgical repair of the loss of substance was carried out under general anesthesia. The



**Figure 1.** Loss of substance from the left cheek as a large punch, exposing the necrotic mandibular bone.

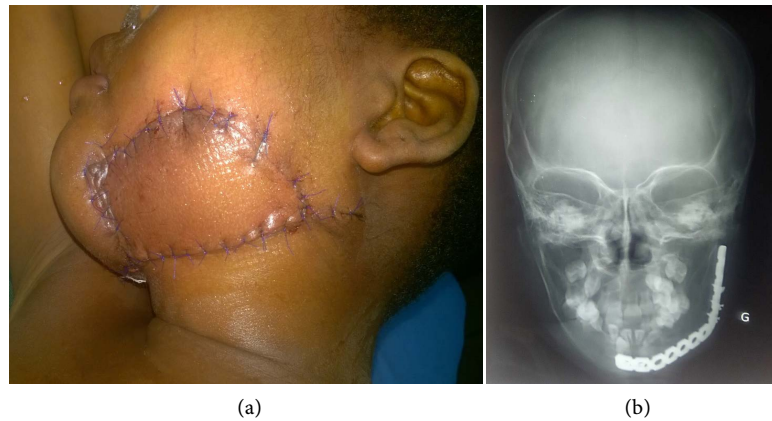


**Figure 2.** CT-SCAN showing the loss of mandibular bone.

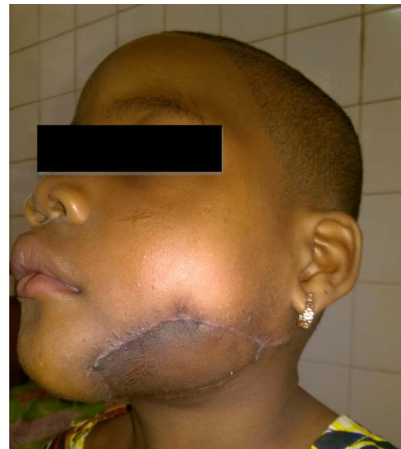first operative step was to resect the necrotic mandibular bone and to revive the soft tissue margins of the orostome. The resected mandibular segment was rehabilitated by a pre-shaped metal plate, and the soft tissue loss was reconstructed by a sub-mental forward-slipping flap (**Figure 3(a)**, **Figure 3(b)**). This flap was removed from the side of the lesion and allowed to rebuild the musculo-cutaneous plane of the cheek, and the endo-oral coverage of the plate. The patient underwent hyperproteic and enteric hypercaloric renutrition for three weeks. The postoperative outcome was simple, and the patient was discharged from the hospital at the end. It healed without functional sequelae, but with acceptable aesthetic damage as shown by this result at 3 months (**Figure 4**).

### 3. Discussion-Comments

Serious and mutilating affection of the oro-facial sphere, noma is frequent in economically disadvantaged areas. Noma affects mainly children weakened by malnutrition and severe childhood diseases in Africa [5]. The factors favoring this condition are an indicator of poverty according to WHO [8]. These conditions



**Figure 3.** (a) Pedicled sub-mental flap recovering the metal plate; (b) Pre-shaped metal plate reconstructing the left mandibular bone.



**Figure 4.** The result 3 months after the surgery.

are consistent with our observation where it is indeed a child from a very miserable family. There is also a notion of malnutrition and poor oral hygiene, including gingivitis and multiple dental caries. Restorative and aesthetic surgery, while sometimes questionable, remains a challenge in developing countries [6] [9]. Our patient, after a hyperprotein and hypercaloric supplementation, benefited of a repair surgery associating a bone rehabilitation by metal plate and the closure of the orostome by a sub-mental flap. The bone repair could ideally have been done with a free flap of fibula, but the technical platform of our service did not allow the realization of such a flap. Bone grafting by an iliac bone graft would be risky given the extent of the necrotic bone (50 mm) and especially the precarious vascular state of the recipient site. In addition, these two techniques include an aesthetic and functional ransom of the donor sites. We preferred the metal plate repair which is simple to perform and saves the inconvenience of bone removal. However, the metal plate has a significant cost, and has no potential for growth in this girl on growing. Several solutions have been proposed for the reconstruction of the losses of substances of the soft parts of the face. Skin grafting cannot be considered here because there is no longer a vascularized

basement to receive a skin graft. Loco-regional flaps were used [6] [7]. The pediculated musculocutaneous flap of the pectoralis major would provide a good volume of tissue, but its cutaneous texture is different from the skin of the face [10] [11]. It would also leave an unsightly scarring ransom at the donor site in this young girl and hinder her femininity in adulthood [12]. The muscular-mucosal flaps of the buccinator [13] and FAMM [14] cannot be removed from the ipsilateral side, as almost all of the soft tissue in the area has been destroyed. We opted for the sub-mental flap that remains the most accessible and the closest to the loss of substance [15]. Because of its proximity, it brings texture fabrics to close that loss of substance. It is a fascio-cutaneous flap pedicled on the sub-mental artery, a constant branch of the facial artery. Although not very thick, it allowed this patient a better handling. Thus we reconstructed the loss of substance by a sub-mental pedicled flap set up by transposition and advancement in V-Y. The fascio-muscular part allowed to cover the plate and to reconstitute the mucous plane of the loss of substance. The skin side was used to close the orostoma from the outside. Tightness was achieved, and mucocutaneous scarring at three months acceptable. Regular annual monitoring is recommended to detect any mandibular disharmony during its growth. This case seems to be original because we did not find the similar cases conducted with both plate rebuilding and sub-mental flap recovering.

#### 4. Conclusion

Noma is a severe gangrenous stomatitis that transforms patients' faces into ghosts by destroying soft tissues and underlying bone planes. The management of his sequelae is surgical, sometimes using complex techniques of plastic surgery.

#### Consent

We obtained the patient's parents consent for the Case report to be published. We often receive the patient and her parents for clinical-check, and they are glad to know their case will be an example for medical people.

#### Conflicts of Interest

The authors declare no conflicts of interest regarding the publication of this paper.

#### References

- [1] Enwonwu, C.O., Falkler, W.A. and Philips, R.S. (2006) Noma (Cancrumoris). *The Lancet*, **368**, 147-156. [https://doi.org/10.1016/S0140-6736\(06\)69004-1](https://doi.org/10.1016/S0140-6736(06)69004-1)
- [2] Tonna, J.E., Lewin, M.R. and Mensh, B.R. (2010) A Case and Review of Noma. *PLOS Neglected Tropical Diseases*, **4**, 869. <https://doi.org/10.1371/journal.pntd.0000869>
- [3] Weledji, E.P. and Njorg, S. (2016) Cancrumoris (Noma): The Role of Nutrition in Management. *Journal of the American College of Clinical Wound Specialists*, **7**,

- 50-52. <https://doi.org/10.1016/j.jccw.2016.08.003>
- [4] Ogbureke, K.U.E. and Ogbureke, E.I. (2010) Noma: A Preventable “Scourge” of the African Children. *The Open Dentistry Journal*, **4**, 201-206. <https://doi.org/10.2174/1874210601004010201>
- [5] Cocquempot, K., Javaudin, O., Lerasle, P. and Aigle, L. (2014) Noma chez une enfant: Une observation au Tchad. *Médecine et Santé Tropicales*, **24**, 99-104.
- [6] Hartman, E.H., Van Damme, P.A., Rayatts, S. and Kuokkanen, H.O. (2010) Return of the Waltzing Flap in Noma Reconstructive Surgery; Revisiting the Past in Difficult Circumstances. *Journal of Plastic, Reconstructive & Aesthetic Surgery*, **63**, 80-81. <https://doi.org/10.1016/j.bjps.2009.01.011>
- [7] Bello, S.A. (2012) Gillies Fan Flap for Reconstruction of Upper Lip Defect Caused by Noma: Case Presentation. *Clinical, Cosmetic and Investigational Dentistry*, **4**, 17-20. <https://doi.org/10.2147/CCIDE.S31190>
- [8] Bourgeois, D.M. and Leclercq, M.H. (1999) The World Health Organization: Initiative on Noma. *Oral Diseases*, **5**, 172-174. <https://doi.org/10.1111/j.1601-0825.1999.tb00085.x>
- [9] Adam, S., Sama, H.D., Chossegros, C., Bouassalo, M.K., Akpoto, M.Y. and Kpemis-si, E. (2017) Improvised Vacuum-Assisted Closure for Severe Neck Infection in Poorly Equipped Conditions. *Journal of Stomatology Oral Maxillofacial Surgery*, **118**, 178-180. <https://doi.org/10.1016/j.jormas.2017.03.008>
- [10] Wadwongtham, W., Isipradit, P. and Supanakorn, S. (2004) The Pectoralis Major Myocutaneous Flap: Applications and Complications in Head and Neck Reconstruction. *Journal of the Medical Association of Thailand*, **87**, 95-99.
- [11] Kim, B., Kaleem, A. and Zaid, W. (2016) Case Reports of Two Unusual Donor Site Complications of the Pectoralis Major Myocutaneous Flap and Literature Review. *Journal of Oral and Maxillofacial Surgery*, **74**, 1504-1512. <https://doi.org/10.1016/j.joms.2016.02.026>
- [12] Jena, A., Patnayak, R., Sharan, R., Reddy, S., Manilal, B. and Rao, L.M. (2014) Outcomes of Pectoralis Major Myocutaneous Flap in Female Patients for Oral Cavity Defect Reconstruction. *Journal of Oral and Maxillofacial Surgery*, **72**, 222-231. <https://doi.org/10.1016/j.joms.2013.06.205>
- [13] AbouChedel, N., Beziat, J.L. and Torossian, J.M. (1998) Reconstruction of the Mouth Floor Using a Musculo Mucosal Buccinator Island Flap Supplied by Facial Vessels. Report of Ten Cases. *Annales de Chirurgie Plastique Esthétique*, **43**, 252-258.
- [14] Jowett, N., Hadlock, T.A., Sela, E., Toth, M., Knecht, R. and Lörincz, B.B. (2017) Facial Mimetic, Cosmetic, and Functional Standardized Assessment of the Facial Artery Musculomucosal (FAMM) Flap. *Auris Nasus Larynx*, **44**, 220-226. <https://doi.org/10.1016/j.anl.2016.07.004>
- [15] Oti, J. and Zender, C.A. (2017) The Use of the Submental Island Flap in Reconstructing Palatal and Facial Defects in a Surgical Camp in East Africa. *American Journal of Otolaryngology*, **38**, 96-99. <https://doi.org/10.1016/j.amjoto.2016.09.012>