

# Treatment of Bone Defect with Modular Metal Augmentation Using a Downsized Block in Total Knee Arthroplasty: Technical Note and Report of 17 Cases

Su Chan Lee, Chang Hyun Nam\*, Seung Hyun Hwang, Ji-Hoon Baek, Soon Yong Yoo, Hye Sun Ahn

Joint & Arthritis Research, Department of Orthopaedic Surgery, Himchan Hospital, Seoul, Korea

Email: \*changcape@naver.com

**How to cite this paper:** Lee, S.C., Nam, C.H., Hwang, S.H., Baek, J.-H., Yoo, S.Y. and Ahn, H.S. (2016) Treatment of Bone Defect with Modular Metal Augmentation Using a Downsized Block in Total Knee Arthroplasty: Technical Note and Report of 17 Cases. *Open Journal of Orthopedics*, 6, 268-275.

<http://dx.doi.org/10.4236/ojo.2016.69035>

**Received:** July 14, 2016

**Accepted:** August 29, 2016

**Published:** September 1, 2016

Copyright © 2016 by authors and Scientific Research Publishing Inc. This work is licensed under the Creative Commons Attribution International License (CC BY 4.0).

<http://creativecommons.org/licenses/by/4.0/>



Open Access

## Abstract

In total knee arthroplasty (TKA), a treatment of bone defect varies depending on the location and extent of defect and requires proper surgical procedure. Metal augmentation is readily available for both femoral and tibial bone defects. We report the operative technique of modular metal augmentation using a downsized block for ambiguous proximal tibial and distal femoral bone defects in primary and revision TKA. Regarding bone defects, bone loss can be minimized by using a different size of metal augmentation, and suitable reinforcement for bone defects can be achieved. Once our technique is properly used, it will be very helpful in treating bone defects.

## Keywords

Total Knee Arthroplasty, Bone Defect, Metal Augmentation

## 1. Introduction

Bone defects during either primary or revision total knee arthroplasty (TKA) represent a substantial challenge to correct alignment of implants and establishment of a stable bone-implant interface. In TKA, bone defects may occur due to several factors, including iatrogenic implant and cement removal, stress shielding, mechanical loosening, osteolysis, and infection [1]-[7]. Treatments of severe bone defects include structural allograft, modular metal augmentation with a wedge or a block, metaphyseal tantalum cones or sleeves, or custom implant [8]-[10]. Modular metal augmentation has high availability and familiarity but limitations in size and shape at massive asymmetric un-

contained tibial bone defects. Choi introduced double rectangular metal blocks augmentation for managing severe uncontained bone defects [11]. However, there has been no evidence demonstrating treatment of bone defects with modular metal augmentation using various sized blocks.

We report the operative technique of modular metal augmentation using a downsized block for ambiguous proximal tibial and distal femoral bone defects in revision TKA.

## 2. Materials and Methods

This study was approved by the institutional review board of our hospital, and all participants provided informed consent. We carried out metal augmentation of bone defects in 17 cases (15 patients) using the operative technique described above, between November 2012 and December 2015. The inclusion criterion was patients who underwent primary and revision TKA with metal block augmentation. There were 15 female patients with the mean age of 70.2 years (53 - 79 years). Of the 17 cases, 4 cases underwent primary TKA and their primary diagnoses were composed of primary osteoarthritis (3 cases) and rheumatoid arthritis (1 case). The causes of 13 cases revision TKA were aseptic loosening (11 cases) and failure in unicompartmental knee arthroplasty (2 cases). The mean follow-up period was 25.0 months (14 - 38 months). The visual analogue scale (VAS), the Knee Society clinical scores (KSS), the Western Ontario and McMaster Universities Osteoarthritis Index (WOMAC), and the 36-Item Short Form Health Survey (SF-36) scores were collected preoperatively and during the latest follow-up period postoperatively. And we examined the demographics of patients and the characteristics of metal blocks (Table 1).

## 3. Case Reports and Surgical Techniques

All procedures were performed through a midline skin incision using a standard medial parapatellar approach. Proper axial alignment of the tibia was confirmed by an extramedullary tibial alignment guide. Initial proximal tibial osteotomy was carried out at a depth of 8 mm from the unaffected lateral tibial condyle. In the case of revision TKA, the proper level of proximal tibial osteotomy was set in consideration of the relationship between the patella and the fibular head in order to restore the initial joint line [12].

The tibial surface was prepared to accept the tibial base tray and the tibial bone defect was assessed. A cutting guide for metal augmentation was assembled and a matching bone resection was carried out. If the tibial bone deficiency was >5 mm and the uncontained type has no bony support base after tibial bone resection, metal augmentation, 5 mm or 10 mm thick, was used to compensate for the bony defect (Figure 1).

However, if the tibial metal augmentation overhung a part of the tibial cortical rim, accordingly, the contact area of the bone bed and augmentation was properly reinforced by using a downsized metal augmentation. The downsized metal augmentation was affixed to the tibial tray using two screws and the intramedullary stem on the tibial

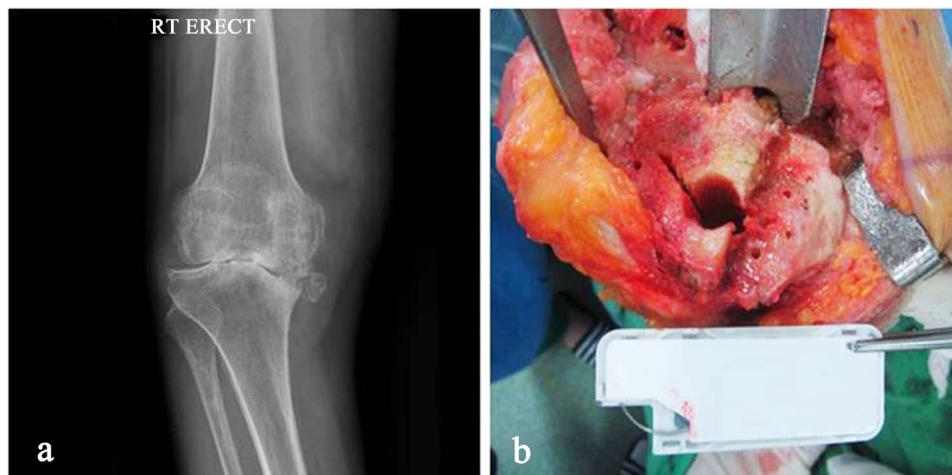
**Table 1.** Demographics of patients and characteristics of metal blocks.

Case No.	Metal block	Age/ Sex <sup>a</sup>	Primary or revision TKA <sup>b</sup> (laterality <sup>c</sup> )	Diagnosis	Clinical follow-up (month)	Femoral (F)/ Tibial (T) component size	Block size	Stem size
1	Tibia	53/F	Primary (Rt)	Rheumatoid arthritis	28	#5 (T)	#3 - 10 mm	12 × 80 mm
2	Tibia	64/F	Primary (Rt)	Primary osteoarthritis	21	#5 (T)	#3 - 10 mm	14 × 80 mm
3	Tibia	73/F	Primary (Rt)	Primary osteoarthritis	19	#5 (T)	#3 - 5 mm	10 × 80 mm
4	Tibia	79/F	Primary (Rt)	Primary osteoarthritis	15	#5 (T)	#3 - 10 mm	14 × 80 mm
5	Tibia	69/F	Revision (Rt)	Aseptic loosening	31	#5 (T)	#3 - 5 mm	14 × 80 mm
6	Tibia	(Both)	Revision (Lt)	Aseptic loosening	27	#5 (T)	#3 - 10 mm	10 × 155 mm
7	Tibia	72/F	Revision (Rt)	Aseptic loosening	30	#5 (T)	#3 - 10 mm	10 × 155 mm
8	Tibia	71/F	Revision (Rt)	Aseptic loosening	29	#5 (T)	#3 - 10 mm	10 × 155 mm
9	Tibia	59/F	Revision (Lt)	Failed UKA	26	#5 (T)	#3 - 5 mm	12 × 80 mm
10	Tibia	69/F	Revision (Rt)	Aseptic loosening	30	#5 (T)	#3 - 10 mm	10 × 155 mm
11	Tibia	70/F	Revision (Rt)	Aseptic loosening	25	#5 (T)	#3 - 10 mm	12 × 155 mm
12	Tibia	64/F	Revision (Rt)	Aseptic loosening	23	#5 (T)	#3 - 10 mm	12 × 155 mm
13	Tibia	72/F	Revision (Rt)	Aseptic loosening	19	#5 (T)	#3 - 5 mm #3 - 10 mm	12 × 155 mm
14	Tibia	(Both)	Revision (Lt)	Aseptic loosening	19	#5 (T)	#3 - 5 mm #3 - 10 mm	12 × 155 mm
15	Tibia	76/F	Revision (Lt)	Failed UKA	14	#5 (T)	#3 - 10 mm	12 × 80 mm
16	Tibia	76/F	Revision (Rt)	Aseptic loosening	14	#5 (T)	#3 - 5 mm	12 × 155 mm
17	Femur	67/F	Revision (Rt)	Aseptic loosening	43	#5 (F)	#3 - 10 mm	12 × 80 mm

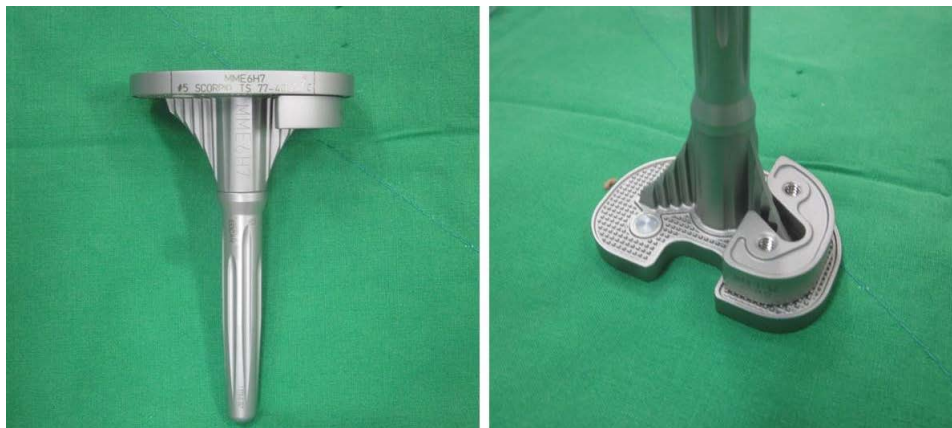
<sup>a</sup>Sex: M—male, F—female, <sup>b</sup>TKA: total knee arthroplasty, <sup>c</sup>Laterality: Rt—right, Lt—left.

component was commonly used to protect the peripheral bone from stress (**Figure 2**).

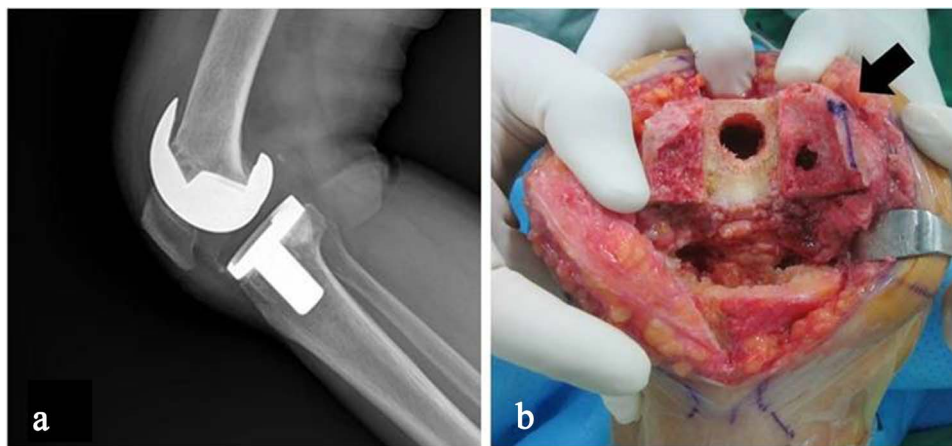
Also, in the femoral medial bone defect, femoral downsized metal augmentation was used on the distal side. The reason why a different size of metal augmentation was used on the distal side was that the remaining medial cortical wall bone of the distal femur was sufficient to maintain stability of the component, allowing for minimization of bone loss by using a different size of metal augmentation (**Figure 3**). The downsized metal augmentation was affixed to the femoral tray using one screw and the intramedullary stem was assembled to the femoral component. The size of the stem was determined by considering the length, depth, and width of the tibia, and whether the stem was fitted to or contacted the medullary canal (**Figure 4**).



**Figure 1.** (a) Preoperative radiographs showing a severe medial tibial bone defect. (b) Intraoperative photograph after tibial bone cutting for block insertion; the same size block as the tibial component might have protruded over the cortical rim.



**Figure 2.** Photograph showing a downsized block attached to the tibial component.



**Figure 3.** (a) Preoperative radiographs showing loosening of the femoral component. (b) Intraoperative photograph after femoral bone cutting for insertion of a block, showing preserved medial cortical wall bone (arrow).



**Figure 4.** Photograph showing a downsized block attached to the femoral component.

Stryker Scorpio<sup>®</sup> TS Knee Replacement (Stryker<sup>®</sup>, Allendale, NJ, USA) was used in all patients.

During the follow-up period, for all the patients of tibial metal augmentation, no prosthesis loosening or subsidence of the component was observed (**Figure 5**). The mean ROM was 0° - 125° at the latest follow-up. And the preoperative mean VAS pain score of 9 was significantly improved up to 2 postoperatively. The mean scores of KSS, WOMAC, and the SF-36 improved from 69, 40.2, and 57.9 preoperatively to 90, 12.5, and 70 postoperatively, respectively.

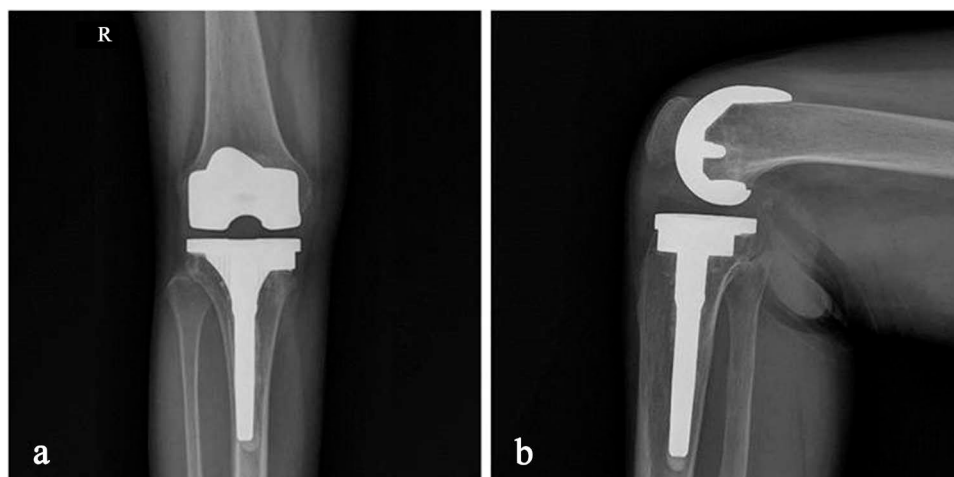
In case of treating the femoral bone defect, for 43 months after the operation, no component loosening findings were noted on radiography (**Figure 6**). The ROM was 0° - 130°, and the VAS pain score of 9 was significantly improved up to 1 postoperatively. Scores of KSS, WOMAC, and the SF-36 improved from 60, 38.6, and 37 preoperatively to 94, 11.7, and 56 postoperatively, respectively.

#### 4. Discussion

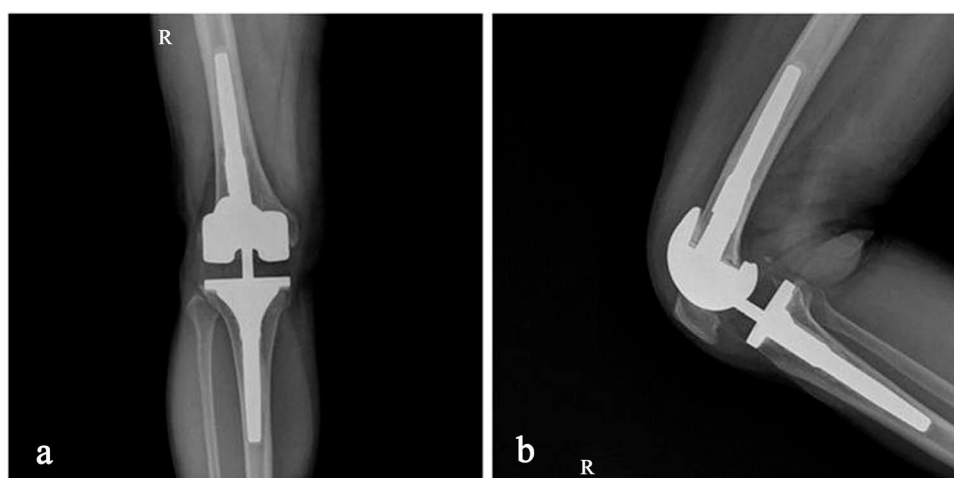
Femoral and tibial bony defects are occasionally encountered during TKA. Treatment options include cement filling, cement with screw augmentation, metal augmentation, morselized or structural bone grafts, and tantalum, depending on the location and extent of bone loss, bone quality, the surgeon's experience and preference, and the availability of grafts and implant [13]-[16].

Metal augments are used for defects of 5 - 10 mm [17] or when 40% or more of the contact surface between the bone and the implant is unsupported by host bone [18]. Metal augments provide good load transmission to underlying bone as well as immediate support and stability [19]. They can be applied easily and quickly, allowing for intraoperative custom fabrication and minimal bone resection [11]. Unlike allograft, there are no concerns about disease transmission, non-union, malunion, or augment collapse [8].

Downsized metal augmentation is a unique method that has an advantage of modular metal augmentation, overcoming the limitations of size and shape. This technique



**Figure 5.** Postoperative radiographs of case No. 1 at 28 months follow-up.



**Figure 6.** Postoperative radiographs of case No. 17 at 43 months follow-up.

can prevent unnecessary host bone cutting and protrusion of the metal block, which may lead to pain and irritation to soft tissue.

To manage severe uncontained bone defects  $>15$  mm, Baek and Choi described double rectangular metal blocks augmentation using PMMA cement, which was previously introduced in a technical note [20]. It is a unique method that has an advantage of modular metal augmentation, overcoming the limitations of size and shape. By applying a smaller-sized metal augmentation, this technique can prevent the prosthetic support from protrusion, which may result in irritation to soft tissue and pain.

In our case, a Scorpio metal augmentation screw system was used for treatment of bone defect ( $\leq 10$  mm). The femoral component was a one-screw type, and it was possible to attach femoral metal augmentations of different sizes. Different sized metal augmentation is needed on the distal side when the medial cortical bone of the distal femur is stable and relatively its large part remains. However, when using a metal augmentation of the same size as the femoral component, the remaining normal cortical wall

should be removed. Regarding bone defects in such cases, bone loss can be minimized by using a different size of metal augmentation.

For a tibial component, two screw types are adopted. If a block being the same size as the tibial component overhangs the cut tibial bone bed, suitable reinforcement can be performed by using a small-sized metal augmentation.

The Stryker Scorpio TKA system has a limitation in that it cannot be used for all sizes of component. Tibial component of two screws of type #9 is available only for block #7, and #5 for block #3. Such materials should also be used for the femoral component, but the one screw type and block are available for all component sizes.

If the TKA component is sized as mentioned in the above and this technique is properly used, it will be very helpful.

## 5. Conclusion

Bone loss can be minimized by using a different size of metal augmentation, and suitable reinforcement for the bone defect can be achieved. The modular metal augmentation using a downsized block in TKA will be very helpful in treating bone defects.

## Conflict of interests

The authors declare that they have no conflict of interests.

## References

- [1] Fehring, T.K., Christie, M.J., Lavernia, C., Mason, J.B., McAuley, J.P. and Springer, B.D. (2008) Revision Total Knee Arthroplasty: Planning, Management, and Controversies. *Instructional Course Lectures*, **57**, 341-363.
- [2] Munjal, S., Phillips, M.J. and Krackow, K.A. (2001) Revision Total Knee Arthroplasty: Planning, Controversies, and Management—Infection. *Instructional Course Lectures*, **50**, 367-377.
- [3] Clarke, H.D. and Scuderi, G.R. (2001) Revision Total Knee Arthroplasty: Planning, Management, Controversies, and Surgical Approaches. *Instructional Course Lectures*, **50**, 359-365.
- [4] Completo, A., Simoes, J.A. and Fonseca, F. (2009) Revision Total Knee Arthroplasty: The Influence of Femoral Stems in Load Sharing and Stability. *Knee*, **16**, 275-279. <http://dx.doi.org/10.1016/j.knee.2008.12.008>
- [5] Tan, G.M., Lynne, G. and Sarbjit, S. (2008) Osteolysis and Wear Debris after Total Knee Arthroplasty Presenting with Extra-Articular Metallosis in the Calf. *The Journal of Arthroplasty*, **23**, 775-780. <http://dx.doi.org/10.1016/j.arth.2007.05.031>
- [6] Sydney, S.E., Pickering, S.A., Bell, C.G. and Crawford, R. (2007) Reducing Metal Debris Generation during Total Knee Arthroplasty. *Orthopedics*, **30**, 999-1000.
- [7] Gotterson, P.R., Nusem, I., Percy, M.J. and Crawford, R.W. (2005) Metal Debris from Bony Resection in Knee Arthroplasty—Is It an Issue? *Acta Orthopaedica*, **76**, 475-480. <http://dx.doi.org/10.1080/17453670510041448>
- [8] Daines, B.K. and Dennis, D.A. (2012) Management of Bone Defects in Revision Total Knee Arthroplasty. *The Journal of Bone & Joint Surgery (American)*, **94**, 1131-1139. <http://dx.doi.org/10.2106/JBJS.L00143>

- [9] Panegrossi, G., Ceretti, M., Papalia, M., Casella, F., Favetti, F. and Falez, F. (2014) Bone Loss Management in Total Knee Revision Surgery. *International Orthopaedics*, **38**, 419-427. <http://dx.doi.org/10.1007/s00264-013-2262-1>
- [10] Vasso, M., Beaufile, P., Cerciello, S. and Schiavone Panni, A. (2014) Bone Loss Following Knee Arthroplasty: Potential Treatment Options. *Archives of Orthopaedic and Trauma Surgery*, **134**, 543-553. <http://dx.doi.org/10.1007/s00402-014-1941-8>
- [11] Radnay, C.S. and Scuderi, G.R. (2006) Management of Bone Loss: Augments, Cones, Offset Stems. *Clinical Orthopaedics and Related Research*, **446**, 83-92. <http://dx.doi.org/10.1097/01.blo.0000214437.57151.41>
- [12] Chung, K.S., Lee, J.K., Lee, H.J. and Choi, C.H. (2016) Double Metal Tibial Blocks Augmentation in Total Knee Arthroplasty. *Knee Surgery Sports Traumatology Arthroscopy*, **24**, 214-220. <http://dx.doi.org/10.1007/s00167-014-3368-8>
- [13] Patel, J.V., Masonis, J.L., Guerin, J., Bourne, R.B. and Rorabeck, C.H. (2004) The Fate of Augments to Treat Type-2 Bone Defects in Revision Knee Arthroplasty. *The Journal of Bone & Joint Surgery (British)*, **86**, 195-199. <http://dx.doi.org/10.1302/0301-620X.86B2.13564>
- [14] Lotke, P.A., Carolan, G.F. and Puri, N. (2006) Impaction Grafting for Bone Defects in Revision Total Knee Arthroplasty. *Clinical Orthopaedics and Related Research*, **446**, 99-103.
- [15] Engh, G.A. and Ammeen, D.J. (2007) Use of Structural Allograft in Revision Total Knee Arthroplasty in Knees with Severe Tibial Bone Loss. *The Journal of Bone & Joint Surgery (American)*, **89**, 2640-2647. <http://dx.doi.org/10.2106/JBJS.F.00865>
- [16] Meneghini, R.M., Lewallen, D.G. and Hanssen, A.D. (2009) Use of Porous Tantalum Metaphyseal Cones for Severe Tibial Bone Loss during Revision Total Knee Replacement. Surgical Technique. *The Journal of Bone & Joint Surgery (American)*, **91**, 131-138. <http://dx.doi.org/10.2106/JBJS.H.01061>
- [17] Brand, M.G., Daley, R.J., Ewald, F.C. and Scott, R.D. (1989) Tibial Tray Augmentation with Modular Metal Wedges for Tibial Bone Stock Deficiency. *Clinical Orthopaedics and Related Research*, **248**, 71-79. <http://dx.doi.org/10.1097/00003086-198911000-00013>
- [18] Cuckler, J.M. (2004) Bone Loss in Total Knee Arthroplasty: Graft Augment and Options. *The Journal of Arthroplasty*, **19**, 56-58. <http://dx.doi.org/10.1016/j.arth.2004.03.002>
- [19] Brooks, P.J., Walker, P.S. and Scott, R.D. (1984) Tibial Component Fixation in Deficient Tibial Bone Stock. *Clinical Orthopaedics and Related Research*, **184**, 302-308. <http://dx.doi.org/10.1097/00003086-198404000-00049>
- [20] Baek, S.W. and Choi, C.H. (2011) Management of Severe Tibial Bony Defects with Double Metal Blocks in Knee Arthroplasty—A Technical Note Involving 9 Cases. *Acta Orthopaedica*, **82**, 116-118. <http://dx.doi.org/10.3109/17453674.2010.548031>



**Submit or recommend next manuscript to SCIRP and we will provide best service for you:**

Accepting pre-submission inquiries through Email, Facebook, LinkedIn, Twitter, etc.

A wide selection of journals (inclusive of 9 subjects, more than 200 journals)

Providing 24-hour high-quality service

User-friendly online submission system

Fair and swift peer-review system

Efficient typesetting and proofreading procedure

Display of the result of downloads and visits, as well as the number of cited articles

Maximum dissemination of your research work

Submit your manuscript at: <http://papersubmission.scirp.org/>