

Management of Ovarian Hernia in Children, in Teaching Hospital of Bouaké, Côte d'Ivoire

Prise en Charge des Hernies de l'ovaire de l'enfant au CHU de Bouaké, Côte d'Ivoire

Nandiolo K. Rose^{1,2*}, Menin Messou^{1,3}, Kpangni Jean Bertrand⁴, Yenan John Patrick^{1,5}, Lohourou Grah Franck^{1,4}

¹University Alassane Ouattara, Bouake, Côte d'Ivoire

²Catholic Hospital St Joseph Moscati, Yamoussoukro, Côte D'Ivoire

³Department of Gynecology and Obstetrics, Teaching Hospital of Bouake, Bouake, Côte d'Ivoire

⁴Department of Paediatric Surgery, Teaching Hospital of Bouake, Bouake, Côte d'Ivoire

⁵Department of Pediatrics, Teaching Hospital of Bouake, Bouake, Côte d'Ivoire

Email: *fleur1us@yahoo.com, meninmichelle@hotmail.com, jbest034@gmail.com, johnnyenan@yahoo.fr, grahnevo@yahoo.fr

How to cite this paper: Rose, N.K., Messou, M., Bertrand, K.J., Patrick, Y.J. and Franck, L.G. (2018) Management of Ovarian Hernia in Children, in Teaching Hospital of Bouaké, Côte d'Ivoire *Prise en Charge des Hernies de l'ovaire de l'enfant au CHU de Bouaké, Côte d'Ivoire*. *Open Journal of Obstetrics and Gynecology*, 8, 1438-1444.

<https://doi.org/10.4236/ojog.2018.813145>

Received: October 11, 2018

Accepted: November 23, 2018

Published: November 26, 2018

Copyright © 2018 by authors and Scientific Research Publishing Inc.

This work is licensed under the Creative Commons Attribution International License (CC BY 4.0).

<http://creativecommons.org/licenses/by/4.0/>



Open Access

Abstract

Objective: To analyze our experience in the management of ovarian hernia in children. **Methods:** It was a retrospective study about 11 cases treated in pediatric surgery unit of the Teaching Hospital of Bouaké, in 2 years period. **Results:** Ovarian hernia represented 7.69% of the hernias and 73.33% of the hernia cases in girls. The mean age was 4 years and the median 36 months. The main reason for consultation was inguinal swelling (45.45%) following by swelling of the labia majora (36.36%), and a round mass of labia majora palpated by parents while bathing the child (18.18%). Nine (9) patients had been operated on; we realize the closure of peritoneo-vaginal canal, associated in 66.66% cases with a routine surgical exploration of the contralateral side. Average age of these children with contralateral hernia was 20 months. The mean follow up was 6 months (15 days - 15 months). We noticed an appearance of contralateral ovarian hernia in a girl operated on at 3 years old without routine surgical exploration. **Conclusion:** We recommend early management with a systematic surgical exploration of the contralateral side in young female child. A preoperative ultrasonography could be a routine in case of strangulated hernia, if available.

Keywords

Ovarian Hernia, Children, Processus Vaginalis

1. Introduction

Hernia containing ovary is a rare congenital disease with a risk of severe complications: strangulated hernia, ovarian torsion, infertility [1] [2] [3]. The aim of this study was to report our experience of the management of inguinal hernia containing ovary in children.

2. Methods

It was a retrospective study about eleven (11) records of female patients managed in pediatric surgery unit of the Teaching hospital of Bouake during a 2 years period (02 May 2014 au 30th April 2016). Where included in this study, all female child age from 0 day to 15 years presented with ovarian hernia. Exclusion criteria where: all female child age from 0 day to 15 years with other cause of labia majora or inguinal swelling, incomplete records, operated ovarian hernia. We analyzed the age, the gestational age, symptoms, clinical presentation, the hernia site, associated lesions, management, and the outcome. Data where recorded with software word and excel, from charts and operative reports. The median was calculated with Epi info 7.5.

All parents gave their informed consent prior to their inclusion in the study. Additional informed consent was obtained from all individual parent of participant for whom images are included in this article.

The consent of local ethics committee was obtained.

3. Results

3.1. Demographic Aspects

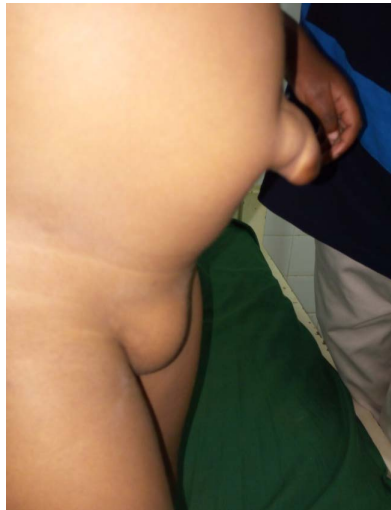The frequency of hernia containing ovary was 5.5 per year. The prevalence was represented 7, 69% of hernia in children and 73.33% of female child hernia. The average age was 4 years (6 months - 13 years). The median was 36 months with the interquartile range from 20 months to 48 months. There was none preterm patient.

3.2. Diagnosis

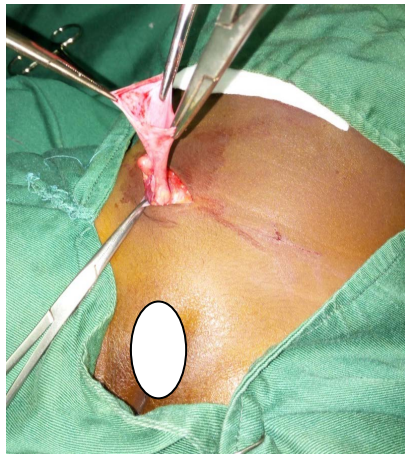
The clinical presentation was a swelling of groin (45.45%) or a swelling of labia majora (36.36%). At Physical examination, we noticed a swelling of labia majora (**Figure 1(a)**), a round palpable, painless and movable mass (100%). The left side was involved in 54.54% and the right side in 45.45%. Associated lesions were: 7cases of umbilical hernia (**Figure 1(a)**), 1 case of inguinal hernia (**Figure 2**). No preoperative radiological investigation had been done.

3.3. Treatment

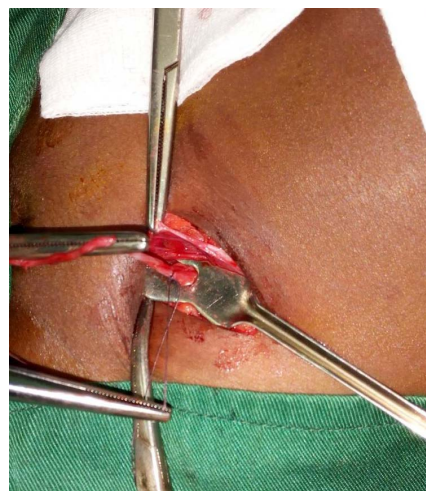
We performed surgery in 9 patients. The 2 others did not come for surgery. The herniotomy was done under general anesthesia, through an incision in abdominal inferior wall. At routine contralateral surgical exploration realized in 6 cases (66.66%), we noticed a contralateral hernia containing ovary (**Figure 1(c)**)



(a)



(b)



(c)

Figure 1. (a) Two years old patient with right hernia containing ovary associated with umbilical hernia; (b) Right hernia containing ovary with a big hernia sac, opened for exploration; (c) The same patient with patent left processus vaginalis (PV) with a hernia containing ovary discovered at routine contralateral surgical exploration.

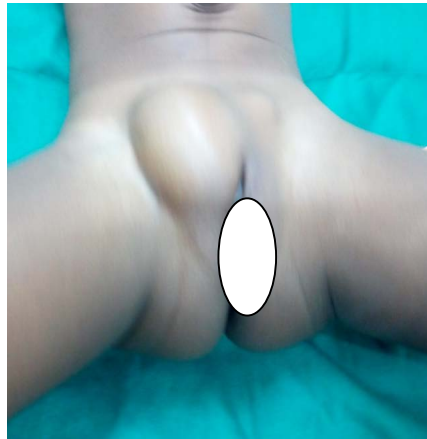

Figure 2. Left hernia containing ovary associated with a big right hernia containing bowel.

in all these patients whom average age was 1 year 8 months (6 months to 2 years). The follow up of the patients with routine contralateral exploration was uneventful in all 6 cases; there was no recurrence. In the 3 patients without routine contralateral exploration, we observed no contralateral hernia in 2 cases (11 years/13 years old) after 12 months and 15 months follow up. The third one operated at 3 years old, had a contralateral hernia, after a 7 months follow up (**Table 1**).

4. Comments

Embryology: Hernia containing ovary is a congenital disease. It results from an incomplete obliteration of processus vaginalis (PV) developed at around the 6th month of fetal development and passes through the inguinal canal up to the labium majora. It is usually obliterated by 8 months of gestations [4] [5]; these conditions explain the high risk of hernia in preterm [4]. Ovarian herniation through the patent Processus vaginalis named the canal of Nuck, results in an inguinal hernia containing ovary. However, Bowel, omental fat, fluid, fallopian tube, rarely uterus and urinary bladder can also herniate though this [5] [6] and lead to a problem of differential diagnosis.

Socio-demographic aspects: Hernia containing ovary is rare. The prevalence was 7.69% of children's hernia in our series. Huang reported 4.48% (26 ovarian hernia out of 580 female inguinal hernia cases admitted in Chang Gung Children's Hospital, Taiwan from 1997 to 2002) [7]. Ovarian hernia is the most frequent inguinal hernia in a female child in our series where it represented 73.33% of female child hernia. Osifo also reported a predominance ovarian hernia with or without fallopian tube (71%) [8] This disease is congenital and can be diagnosed at any age in the childhood [5] [9] [10].

Diagnosis: The clinical aspect is usually, as observed in our experience, an asymptomatic palpable movable mass in the groin or over the labium majora, painless in absence of incarceration. We did not do pre-operative sonography unlike in literature [1]; it could help to identify the content of hernia and explore

Table 1. Cases report.

	Age	Functional signs	Diagnosis	Associated lesions	Treatment	Results
1	3 years	Groin swelling	Left	umbilical hernia	No surgery	-
2	6 months	Groin swelling	Left	umbilical hernia	surgery	uneventful
3	10 months	Swelling of labia majora	Right	umbilical hernia	surgery	uneventful
4	2 years	Groin swelling	Left		surgery	uneventful
5	20 months	Groin swelling	Right		surgery	uneventful
6	2 years	Masse palpated in the groin	right	umbilical hernia	surgery	uneventful
7	03 years	Groin swelling	Left	umbilical hernia + right bowel containing hernia	surgery	uneventful
8	4 years	Swelling of labia majora	Right	umbilical hernia	No surgery	-
9	11 years	masse palpated in the groin	Left	None	surgery without contralateral exploration	No contralateral hernia 12 months later
10	13 years	Swelling of labia majora	right	none	surgery without contralateral exploration	no contralateral hernia 15 months later
11	03 years	Swelling of labia majora	left	umbilical hernia	surgery without contralateral exploration	contralateral hernia after 6 months later

the contra lateral side. It is an easy accurate pre-operative diagnosis procedure [7], has ability to evaluate ovary and differentiate hernia containing ovary among hydrocele in the canal of Nuck, a bowel containing hernia, an enlarged lymph node [5] [11]. Oudesluys-Murphy suggests routine ultrasonography mostly in pre-term infant girls with an inguinal hernia [12].

Treatment: The treatment of hernia containing ovary is surgery. Hernia containing ovary should be repair promptly but not in emergency [4]. There is no possibility of spontaneous regression unlike hernia containing bowel [12]. For hernia repair, all the hernia sacs had been opened in our series (**Figure 1(b)**). Osifo *et al.* in Nigeria also advised to open hernia sac in female with inguinal hernia to prevent the injury of ovary [8]. In case of strangulated hernia containing ovary, Authors advised a pre operative ultrasonography followed by reduction of hernia and delayed surgery if ovary is normal [2]. If there is a poor vitality of ovary (ultrasonography) or if ultrasonography is not available in emergency, hernia should be emergently repair. Surgeons performed routine open contralateral inguinal exploration to identify a patent processus vaginalis in all children or in selected population like former preterm infants, or children younger than 2 years [13]. However, Open surgery contralateral exploration is decreasing with the use of Laparoscopy which is [13] an alternative increasingly use for treatment of the hernia containing ovary and contra lateral exploration [14] [15].

In this case, laparoscopy through umbilicus is recommended [4], but laparoscopy through hernia sac can also be use for contralateral exploration even in infants [4] [16] with less scars and it is cost effective [16], however Juang *et al.* reported 2.5% risk of false negative exam other 1291 laparoscopic inguinal hernia

evaluation [17]. In low income countries routine pre operative ultrasonography is still a great alternative for patients whose parents cannot afford to pay for laparoscopy.

5. Conclusion

Health care givers should be aware of the necessity of early surgery and routine contra lateral exploration in young female child with inguinal hernia. Preoperative ultrasonography could be a routine assessment in our practice where pediatric laparoscopy is currently unavailable.

Communicated

This study has been communicated (oral presentation) at 57th Conference of West African College of Surgeons (WACS), 26 - 4 March 2017, Ouagadougou, Burkina Faso.

Conflicts of Interest

The authors declare that they have no conflict of interest. There are no conflicts of interests between authors/among them.

References

- [1] Ibrahim, H., Khaled, M., Gates, T.H. and Trice, S.G. (2016) Irreducible Indirect Inguinal Hernia in Premature Infant with Ectopic Uterus and Bilateral Adnexa. *Journal of the Louisiana State Medical Society*, **168**, 194-195.
- [2] Lee, J. and Scampoli, N. (2015) Incarcerated Ovarian Inguinal Hernia in a 10-Month-Old Girl. *CMAJ*, **87**, 596-598. <https://doi.org/10.1503/cmaj.140823>
- [3] Choi, K.H. and Baek, H.J. (2016) Incarcerated Ovarian Herniation of the Canal of Nuck in a Female Infant: Ultrasonographic Findings and Review of Literature. *Annals of Medicine and Surgery*, **9**, 30-40. <https://doi.org/10.1016/j.amsu.2016.06.003>
- [4] Snyder, C.L. (2010) Inguinal Hernias and Hydroceles. In: Holcomb III, G.W. and Murphy, J.P., Eds., *Ashcraft's Pediatric Surgery*, 5th Edition, Saunders Elsevier, Philadelphia, 669-675. <https://doi.org/10.1016/B978-1-4160-6127-4.00051-3>
- [5] Jederzejewski, G., Stankiwicz, A. and wieczorek, A.P. (2008) Uterus and Ovary Hernia of the Canal of Nuck. *Pediatric Radiology*, **38**, 1257-1258. <https://doi.org/10.1007/s00247-008-0959-x>
- [6] Sarkar, S., Panja, S. and Kumar, S. (2016) Hydrocele of the Canal of Nuck (Female Hydrocele): A Rare Differential Diagnosis for Inguino-Labial Swelling. *Journal of Clinical and Diagnostic Research*, **10**, 21-22. <https://doi.org/10.7860/JCDR/2016/16710.7284>
- [7] Huang, C.S., Luo, C.C., Chao, H.C., Chu, S.M., Yu, Y.J. and Yen, J.B. (2003) The Presentation of Asymptomatic Palpable Movable Mass in Female Inguinal Hernia. *European Journal of Pediatrics*, **162**, 493-495.
- [8] Osifo, O.D., Ovueni, M.E., *et al.* (2009) Inguinal Hernia in Nigerian Female Children: Beware of Ovary and Fallopian Tube as Contents. *Hernia*, **13**, 149-153. <https://doi.org/10.1007/s10029-008-0446-1>
- [9] Kaya, O., Esen, K., Gulek, B., Yilmaz, C., Soker, G. and Onem, O. (2014) The In-

guinal Herniation of the Ovary in the Newborn: Ultrasound and Color Doppler Ultrasound Findings. *Case Reports in Radiology*, **2014**, Article ID: 281280.

<https://doi.org/10.1155/2014/281280>

- [10] Dumont, T., Caccia, N. and Allen, L. (2011) Pediatric Synchronous Bilateral Ovarian Torsion: A Case Report and Review of the Literature. *Journal of Pediatric Surgery*, **46**, e19-e23. <https://doi.org/10.1016/j.jpedsurg.2011.08.024>
- [11] Faye, C.L., Brent, A.T. and Rodriguez, R. (2007) Ovary Containing Hernia in a Premature Infant Sonographic Diagnosis. *JUM*, **6**, 985-987.
- [12] Oudesluys-Murphy, A.M., Teng, H.T. and Boxma, H. (2000) Spontaneous Regression of Clinical Inguinal Hernias in Preterm Female Infants. *Journal of Pediatric Surgery*, **35**, 1220-1221. <https://doi.org/10.1053/jpsu.2000.8757>
- [13] Wang, K.S. (2012) Committee on Fetus and Newborn, Section on Surgery. Assessment and Management of Inguinal Hernia in Infants. Clinical Report, from the American Academy of Pediatrics. *Pediatrics*, **130**, 768-773. <https://doi.org/10.1542/peds.2012-2008>
- [14] Hata, S., Takahashi, Y., Nakamura, T., *et al.* (2004) Preoperative Sonographic Evaluation Is a Useful Method of Detecting Contralateral Patent Processus Vaginalis in Pediatric Patients with Unilateral Inguinal Hernia. *Journal of Pediatric Surgery*, **39**, 1396-1399. <https://doi.org/10.1016/j.jpedsurg.2004.05.006>
- [15] Antonoff, M.B., Kreykes, N.S., Saltzman, D.A. and Acton, R.D. (2005) American Academy of Pediatrics Section on Surgery Hernia Survey Revisited. *Journal of Pediatric Surgery*, **40**, 1009-1014. <https://doi.org/10.1016/j.jpedsurg.2005.03.018>
- [16] Shehata Sherif, M., Ebeid AbdelMotalieb, E., Khalifa Osama, M., Noord Fayza, M. and Noomaan Abdel Moneim, A. (2013) Prospective Comparative Assessment of Ultrasonography and Laparoscopy for Contralateral Patent Processus Vaginalis in Inguinal Hernia Presented in the First Year of Life. *Annals of Pediatric Surgery*, **9**, 6-10. <https://doi.org/10.1097/01.XPS.0000422614.15188.b5>
- [17] Juang, D., Garey, L.C., Ostille, D.J., Snyder, L.C., Holcomb III, G.W. and St Peter, S.D. (2011) Contralateral Hernia after Negative Laparoscopic Evaluation: A Rare but Real Phenomenon. *Journal of Laparoendoscopic & Advanced Surgical Techniques*, **22**, 200-202. <https://doi.org/10.1089/lap.2011.0092>