

Carbonic anhydrase VII—a potential prognostic marker in gliomas

Fatemeh Bootorabi^{1,2}, Joonas Haapasalo³, Elona Smith¹, Hannu Haapasalo³,
Seppo Parkkila^{1,2}

¹Institute of Medical Technology and School of Medicine, University of Tampere, Tampere, Finland

²Department of Clinical Chemistry, Centre for Laboratory Medicine, Tampere University Hospital, Tampere, Finland

³Department of Pathology, Centre for Laboratory Medicine, Tampere University Hospital, Tampere, Finland;

*Corresponding Author: seppo.parkkila@uta.fi

Received 7 December 2010; revised 20 December 2010; accepted 26 December 2010

ABSTRACT

Carbonic anhydrase VII (CA VII) is a cytosolic enzyme expressed in several organs, including the human brain, but it has not been investigated earlier in any tumors. We designed the present study to evaluate CA VII expression in a cohort of human diffuse astrocytomas, mixed oligoastrocytomas and oligodendrogliomas. CA VII immunostaining was correlated to clinicopathologic findings, survival data, and expression of other molecular factors, including Ki-67, p53 protein and epidermal growth factor receptor. CA VII-positive staining was observed in 94% of astrocytomas and 85% of oligodendrogliomas. In the tumor specimens, strong positive areas were often located in close proximity to necrosis. The CA VII immunoreactivity showed positive correlation with tumor malignancy grades of astrocytomas ($p = 0.02$, chi-square test). In all tumor categories, CA VII-positive staining was often seen in the endothelial cells of neovessels in addition to the tumor cells. CA VII intensity showed no significant association with p53 nor did it correlate with the amplification of epidermal growth factor receptor (analyzed only in astrocytomas) or cell proliferation. Our present results show that CA VII may act as a useful biomarker in histopathologic diagnostics of gliomas. The high expression of CA VII in the tumor cells and endothelium suggests important roles for the enzyme in tumor metabolism. The results also led us to conclude that CA VII might serve as a marker of poor prognosis in diffuse astrocytomas.

Keywords: Astrocytoma; Brain; Cancer; Carbonic Anhydrase; Glioblastoma; Glioma;

Oligodendroglioma; pH

1. INTRODUCTION

Carbonic Anhydrase (CAs) form a family of ubiquitous zinc containing metalloenzymes that are able to catalyze the reversible hydration of carbon dioxide according to the following reaction: $\text{CO}_2 + \text{H}_2\text{O} \rightleftharpoons \text{HCO}_3^- + \text{H}^+$. The CAs show different distribution in a variety of tissues where they participate in several important biological processes such as pH regulation, CO_2 and HCO_3^- transport, respiration, ureagenesis, body fluid generation, lipogenesis, and gluconeogenesis [1,2]. The CA isozymes differ in several important characteristics, such as kinetic properties, susceptibility to inhibitors, and subcellular localization. The α -CA gene family has been reported to include at least 13 active isoforms with different structural and catalytic properties [1-5]. CA isozymes II, IX and XII have been extensively studied for their important role as promising biomarkers in different tumors, for example astrocytic tumors [5-7]. Other important research targets focused on CAs have included hypoxia-regulation of certain CA isozymes and their potential use as targets of cancer therapy [7-13].

Although cytosolic CA VII was identified as a new CA isozyme almost twenty years ago [14], and its CA catalytic activity was already demonstrated in 1996 [15], the characteristics of this isozyme have largely remained unresolved. In fact, the most developed research area on CA VII has been linked to drug development, which has led to the discoveries of several potent activators and inhibitors for this isozyme [16,17]. The expression of CA VII protein was first studied in the brain tissue [18]. In previous publications, CA VII has never been investigated in astrocytomas nor has it been determined in any other tumor categories. Data from GeneSapiens database (<http://ist.genesapiens.org/>) suggested that some gliomas express high levels of CA VII mRNA. This result

prompted us to design the present study to evaluate the expression of CA VII protein in diffusely infiltrating astrocytic gliomas, oligodendrogliomas and mixed oligoastrocytomas. These tumors represent highly malignant neoplasias derived from glial cells. They commonly show infiltrating and diffuse growth pattern, which makes the surgical treatment inadequate in most cases. It is very important to diagnose these tumors as early as possible and to use prognostic tools in the assessment of the most suitable treatment for each patient. In the present study, we evaluate the correlation of CA VII expression between astrocytomas, oligodendrogliomas and oligoastrocytomas using immunohistochemistry and compare the immunostaining results with various clinicopathological and molecular factors including cell proliferation, p53, and epidermal growth factor receptor (EGFR).

2. METHODS

2.1. Study Material

The study material consisted of diffusely infiltrating astrocytoma and oligodendroglioma samples, which were obtained from surgically operated patients in Tampere University Hospital, Tampere, Finland, during 1983-2001. First, the tumor specimens were fixed in 4% phosphate-buffered formaldehyde and processed into paraffin blocks. On the basis of hematoxylin and eosin (H&E)-stained slides a neuropathologist (HH) performed an evaluation of the tumors according to the WHO 2007 criteria [19,20]. According to the Finnish legislation informed consent by the patients is not required in this kind of retrospective study. Most patients had died before starting the analyses. According to the national guidelines, the experiments were approved by the Ethical Committee of the Tampere University Hospital and the National Authority for Medicolegal Affairs and conducted according to the guidelines of the Helsinki Declaration.

2.2. Astrocytic Tumors

The WHO criteria divide diffusely infiltrating astrocytomas into three grades (II-IV) according to the presence of atypia, mitotic activity, necrosis and endothelial proliferation. The neuropathologist selected one histologically representative section in each sample specimen for the CA VII immunohistochemistry. The study included 107 astrocytic tumors (grade II: 14; grade III: 11; grade IV: 82) and consisted of 90 primary tumors and 17 recurrences. Age of patients with primary tumors varied from 20 to 80 years (median $55 \pm \text{SD } 13$ years) and recurrent tumors from 25 to 73 years (median $49 \pm \text{SD } 14$ years). Overall survival was known for all of the patients

with primary tumors (90 patients; 12 grade II, 8 grade III and 70 grade IV). The mean follow-up time for 14 survivors was 67 months (range 31-165) and 76 patients died during the five-year follow-up. The tumors were radically resected if possible and most patients with high grade gliomas also received radiotherapy.

2.3. Oligodendroglial Tumors

The WHO criteria group oligodendroglial tumors into two main categories: pure oligodendrogliomas and mixed oligoastrocytomas, which are divided into two grades (2 and 3) according to the atypia, presence of increased cellularity, and mitotic activity. From 47 cases of oligodendroglial tumor samples which were included in our analyses, there were both pure oligodendrogliomas (18 of grade 2 and 12 of grade 3) and oligoastrocytomas (11 of grade 2 and 6 of grade 3). These tumors included 35 primary tumors and 12 recurrences. The ages of the patients with primary tumors varied from 8 to 76 years (mean \pm SD: 43 ± 14 years), and those of the patients with recurrent tumors varied from 17 to 72 years (mean \pm SD: 41 ± 14 years). Survival analysis was not performed, because overall survival was only known for 26 patients.

2.4. Immunohistochemistry

Five μm sections were processed for immunoperoxidase staining, which was performed using an automated Lab Vision Autostainer 480 (LabVision Corporation, Fremont, CA, USA). Automated immunostaining was performed using the Power Vision+ Poly-HRP Immunohistochemistry kit (ImmunoVision Technologies Co) reagents. The primary rabbit anti-human CA VII serum was raised against recombinant CA VII enzyme and has shown high specificity for the CA VII enzyme [21]. The immunostaining procedure included the following steps: (1) rinsing in wash buffer; (2) treatment in 3% H_2O_2 in ddH₂O for five minutes and rinsing with wash buffer; (3) blocking with cow colostrum diluted 1:2 in Tris-buffered saline (TBS) containing 0.05% Tween-20 for 30 minutes and rinsing in wash buffer; (4) incubation with primary antibody (rabbit anti-human CA VII for 30 minutes; (5) rinsing in wash buffer three times for five minutes; (6) incubation in poly-HRP-conjugated anti-rabbit IgG for 30 minutes and rinsing in wash buffer three times for five minutes; (7) incubation in DAB (3,3-diaminobenzidine tetrahydrochloride) solution (one drop of DAB solution A and one drop of DAB solution B in 1 ml of ddH₂O) for six minutes; (8) CuSO_4 treatment for five minutes to enhance the signal; and (9) rinsing with ddH₂O. All procedures were performed at room temperature. The mounting of the sections was performed using Entellan Neu (Merck; Darmstadt, Germany). The intensity (INT) of the staining was scored on a scale of 0 to 3 by three of

the investigators (H. Haapasalo, F. Bootorabi and S. Parkkila) as follows: 0, no reaction; 1, weak reaction; 2, moderate reaction; and 3, strong reaction. The extent (EXT) of staining was also scored on a scale of 0 to 3, 1 when 1-10% of the cells stained, 2 when 11-50% of the cells stained and 3 when 51-100% of the cells stained. A negative score (0) was given to tissue sections that had no evidence of specific immunostaining. The relative staining indices (SI) were calculated for each tumor sample using the formula $\text{SQRT}(\text{EXT} \times \text{INT})$ as described earlier [22]. The tumors were then divided into three groups based on the staining index: -, $\text{SI} \leq 1$ (immunonegative); +, $\text{SI} > 1$ and ≤ 2 (immunopositive); ++, $\text{SI} > 2$ (strongly immunopositive).

In the present study, we correlated the expression of CA VII to the extent of several other molecular markers, such as Ki-67 (MIB-1, marker of cell proliferation) and p53 as described previously [23]. EGFR amplification was detected in astrocytic tumors using chromogenic *in situ* hybridization (CISH) [24]. The immunostaining results for CA IX and CA XII have been described earlier [7,25].

2.5. Statistical Analysis

All statistical analyses were performed using SPSS for Windows (SPSS Inc. Chicago, IL). The significance of associations was defined using chi-square test, Mann-Whitney test, variance analysis and Kruskal-Wallis test. The log rank test, Kaplan-Meier curves, and Cox multivariate regression analysis were used in the survival analysis. p -values < 0.05 were considered statistically significant.

3. RESULTS

3.1. CA VII and Clinicopathologic Features of Astrocytic Tumors

Cellular CA VII immunopositivity was observed in 101 cases of 107 (94%) diffusely infiltrating astrocytomas. Strong immunostaining reactions (staining index ++) were observed in 47 specimens and weaker reactions (staining index +) were present in 54 tumors. The strongly positive areas were often located in close proximity to necrotic regions (**Figure 1**). The positive staining was usually unevenly distributed within the tumor. It also appeared that the cell cytoplasm was more intensively stained in the tumors with anaplastic features. In addition to the positive staining of tumor cells, CA VII was often located to the endothelial cells of the neovessels.

Within the group of WHO grade II astrocytomas 86% of the tumors were CA VII-positive (50% + and 36%

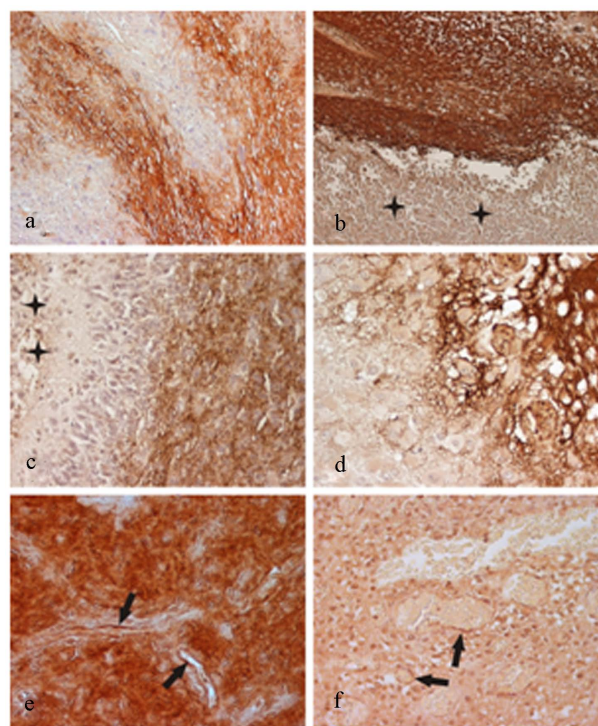


Figure 1. Immunohistochemical staining of CA VII in representative samples of glioblastomas (a-e) and oligodendroglioma (f). Panels a-d show typical uneven distribution pattern of immunostaining. Stars in panels b and c show necrotic regions. Strong immunoreactivity is often associated with hypoxic areas locating in close proximity to necrosis. Panel e shows that positive signal did not follow the hypoxia-pattern in some cases. Arrows indicate capillaries where endothelium is positive. In the oligodendroglioma specimen, both the tumor cells and endothelium (arrows) show positive immunostaining. Original magnifications: $\times 200$ (a,b), $\times 400$ (c,e,f), $\times 630$ (d).

++), and 82% of the grade III astrocytomas were CA VII-positive (73% + and 9% ++) (**Table 1**). Interestingly, almost all (98%) the grade IV tumors showed positive immunostaining (48% + and 50% ++). The statistical comparison of cytoplasmic CA VII staining index and tumor grade revealed significantly higher CA VII staining in tumors with higher malignancy grade ($p = 0.02$, chi-square test, **Table 1**). There was also a statistically significant difference in staining indices between the primary (44% + and 49% ++) and recurrent tumors (82% + and 18% ++), all of the recurrent tumors being immunopositive ($p = 0.015$, chi-square test, **Table 1**). The variance analysis showed that there was no significant correlation between the CA VII staining index and patient age ($p > 0.05$).

3.2. CA VII and Molecular Pathologic Features

When molecular pathologic features typical of astro

Table 1. CA VII staining index (SI), WHO grade and recurrence status of the astrocytic and oligodendroglial tumors (p = p-value, chi-square test).

CA VII immunostaining						
Tumor categories	Grade	p	-	+	++	Total
Astrocytoma	2		2	7	5	14
	3		2	8	1	11
	4	0.02	2	39	41	82
Oligodendroglioma	2		3	9	6	18
	3	>0.05	2	2	8	12
Oligoastrocytoma	2		2	3	6	11
	3	>0.05	0	4	2	6
Primary tumor / Recurrence						
Astrocytoma						
Primary			6	40	44	90
Recurrence		0.005	0	14	3	17
Oligodendroglioma						
Primary			7	16	12	35
Recurrence		0.011	0	2	10	12

cytomas were compared with CA VII immunohistochemistry, no association was observed between the cell proliferation (assessed by Ki-67/MIB-1 immunostaining) and CA VII expression ($p > 0.05$, Kruskal-Wallis test). CA VII intensity showed no significant association with p53 nor did it correlate with EGFR-amplification ($p > 0.05$, chi-square test). There was a significant correlation between CA VII and CA IX staining index ($p = 0.034$, chi-square test), whereas there was no significant relationship between CA VII and CA XII staining ($p > 0.05$, chi-square test).

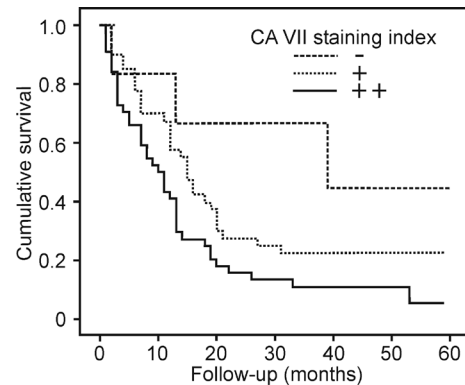
3.3. Correlation of CA VII with Prognosis in Astrocytic Tumors

Overall survival data was known for all the patients with primary tumors. Patient survival was tested by log-rank test in relation to CA VII staining index. Interestingly, CA VII staining results divided the tumors into three significantly different prognostic subsets ($p = 0.017$, log-rank test; **Figure 2**).

When different factors, including CA VII, CA IX and CA XII (all divided into three categories by staining indices -, + and ++) as well as histological grade (2, 3 and 4) and patient age (<50, 50-65 and >65 years) were tested in the Cox multivariate analysis, CA VII, CA IX, histological grade and patient age were found to be of independent prognostic value (**Table 2**).

3.4. Oligodendroglial Tumors

The study materials included 47 oligodendrogliomas of which 30 cases represented pure and 17 were mixed oli

**Figure 2.** Survival of astrocytoma patients grouped according to the CA VII immunostaining of tumor cells. The patients with CA VII-negative tumors had significantly better prognosis than those with CA VII-positive tumors ($p = 0.017$, log-rank test).**Table 2.** The independent prognostic indicators of astrocytomas as evaluated by Cox's stepwise regression model. Histological grade (2,3,4), patient age (cut points 50 and 65 years), CA VII, and CA IX (staining index -, +, ++) were included in the analysis.

	Significance	Exp(B) (Hazard ratio)	95% CI of Exp(B)	
			Lower	Upper
Grade	0.000	3.104	1.673	5.761
CA VII	0.002	2.074	1.306	3.293
Age	0.002	1.817	1.250	2.641
CA IX	0.046	1.431	1.006	2.034

goastrocytomas. 85% of all oligodendrogliomas showed positive immunostaining for CA VII. There was no significant difference in CA VII expression levels between astrocytomas and oligodendrogliomas ($p > 0.05$, chi-square test). Recurrent oligodendrogliomas were more immunopositive for CA VII than the primary tumors, and the difference was found to be statistically significant ($p = 0.011$, chi-square test). There was no statistically significant correlation between the patient age and CA VII status nor did CA VII correlate with tumor grade, cell proliferation (assessed by MIB-1), or p53 immunostaining ($p > 0.05$, chi-square test). A near significant correlation ($p = 0.117$, chi-square test) was observed between CA VII and CA IX staining.

4. DISCUSSION

Previous studies have indicated that carbonic anhydrase isozymes, CA II, CA IX and CA XII, are promising biomarkers for certain tumors [6,7,22,26]. There are numerous reports showing that CA IX acts not only as a marker for particular tumors, but its presence also correlates to prognosis in several tumor categories, such as

brain tumors, sarcomas, and renal, lung, rectal, bladder, oral, breast, and cervical carcinomas [7,27-34]. Although studies on CA II and CA XII have been mainly focused on normal tissues, there are a few previous reports, showing their presence in cancer cells and especially in brain tumors where they have shown significant association with prognosis [6,7,25]. CA VII is a cytosolic isozyme which was first demonstrated in the brain tissue [35], where it has been linked to the regulation of GABAergic neuronal transmission in hippocampal neurons [36]. We recently characterized this enzyme *in vitro* and identified two forms of CA VII mRNA in the human brain [21]. The studies further indicated that only the full-length form of CA VII is expressed in human tissues. The novel antibodies, raised against CA VII, demonstrated that it is expressed in several other mouse tissues -particularly in the liver. The present study was designed when we found using the GeneSapiens database (<http://www.genesapiens.org>), that CA7 gene is highly expressed in some glioblastomas. The finding suggested that CA VII could represent another CA isozyme with a potential role as a biomarker for gliomas.

In this study, we investigated the expression of CA VII in three different categories of brain tumors: astrocytomas, oligodendrogliomas and mixed oligoastrocytomas. Our findings showed that CA VII expression is higher among high grade infiltrating tumors. Interestingly, CA VII immunostaining was often very strong in hypoxic areas adjacent to tumor necrosis. Although CA VII has not been considered a HIF-regulated isozyme contrary to CA IX [37,38] and CA XII [38], its staining pattern indicates that cell hypoxia contributes to the regulation of CA VII expression by yet undefined mechanisms. According to our results CA VII immunoreactivity did not correlate significantly with cell proliferation determined by MIB-1 immunostaining, nor did it show association to p53 protein expression or EGFR- amplification. Importantly, our results indicated that high CA VII expression is associated with poor prognosis in astrocytoma patients. This result makes CA VII another CA isozyme with a significant correlation to the patient survival. Indeed, the previous studies have demonstrated that CA II, CA IX and CA XII all show similar trends as prognostic markers in diffuse astrocytomas [6,7,25,39]. The presence of several CA isozymes in astrocytomas may reflect the rapid turnover of acid metabolic products in highly malignant tumor tissues. The cytosolic isozymes, such as CA II and CA VII, can contribute to more efficient neutralization of cell interior, whereas the membrane-associated enzymes, CA IX and CA XII, participate in extrusion of protons in metabolon systems together with ion transport proteins [5,40,41]. These mechanisms can provide novel opportunities for cancer therapy in which tumor cell microenvironment can be

targeted by CA inhibition. Recent drug developments have already pointed out a number of different compounds as CA inhibitors with high efficiency [5,40]. Some of the drugs may inhibit and disturb the neoangiogenesis while reducing the tumor growth [42], and some compounds can also decrease the invasion capacity of tumor cells [43,44].

In conclusion, our findings demonstrate that CA VII isozyme is highly expressed in several cases of malignant brain tumors including oligodendrogliomas, oligoastrocytomas and diffusively infiltrating astrocytomas. The positive immunostaining correlates with poor prognosis of patients with astrocytomas. The presence of several CA isozymes in malignant brain tumors may provide novel opportunities for developing cancer treatment strategies targeted to the microenvironment of cancer cells.

5. ACKNOWLEDGEMENTS

The authors thank Aulikki Lehmus and Reija Randen for skilful technical assistance. This study was funded by European Union DeZ-nIT project, Academy of Finland, Sigrid Juselius Foundation, and Competitive Research Funding of the Tampere University Hospital (9L071).

REFERENCES

- [1] Sly, W.S. and Hu, P.Y. (1995) Human carbonic anhydrases and carbonic anhydrase deficiencies. *Annual Reviews of Biochemistry*, **64**, 375-401. doi:10.1146/annurev.bi.64.070195.002111
- [2] Parkkila, S. and Parkkila, A.K. (1996) Carbonic anhydrase in the alimentary tract. Roles of the different isozymes and salivary factors in the maintenance of optimal conditions in the gastrointestinal canal. *Scandinavian Journal of Gastroenterology*, **31**, 305-317. doi:10.3109/00365529609006403
- [3] Hewett-Emmett, D. and Tashian, R.E. (1996) Functional diversity, conservation, and convergence in the evolution of the alpha-, beta-, and gamma-carbonic anhydrase gene families. *Molecular Phylogenetics and Evolution*, **5**, 50-77. doi:10.1006/mpev.1996.0006
- [4] Lehtonen, J., Shen, B., Vihinen, M., Casini, A., Scozzafava, A., Supuran, C.T., Parkkila, A.K., Saarnio, J., Kivela, A.J., Waheed, A., Sly, W.S. and Parkkila, S. (2004) Characterization of CA XIII, a novel member of the carbonic anhydrase isozyme family. *Journal of Biological Chemistry*, **279**, 2719-2727. doi:10.1074/jbc.M308984200
- [5] Pastorekova, S., Parkkila, S., Pastorek, J. and Supuran, C.T. (2004) Carbonic anhydrases: current state of the art, therapeutic applications and future prospects. *Journal of Enzyme Inhibition and Medicinal Chemistry*, **19**, 199-229. doi:10.1080/14756360410001689540
- [6] Haapasalo, J., Nordfors, K., Jarvela, S., Bragge, H., Rantala, I., Parkkila, A.K., Haapasalo, H. and Parkkila, S.

- (2007) Carbonic anhydrase II in the endothelium of glial tumors: a potential target for therapy. *Neuro-Oncology*, **9**, 308-313. [doi:10.1215/15228517-2007-001](https://doi.org/10.1215/15228517-2007-001)
- [7] Haapasalo, J.A., Nordfors, K.M., Hilvo, M., Rantala, I.J., Soini, Y., Parkkila, A.K., Pastorekova, S., Pastorek, J., Parkkila, S.M. and Haapasalo, H.K. (2006) Expression of carbonic anhydrase IX in astrocytic tumors predicts poor prognosis. *Clinical Cancer Research*, **12**, 473-477. [doi:10.1158/1078-0432.CCR-05-0848](https://doi.org/10.1158/1078-0432.CCR-05-0848)
- [8] Said, H.M., Hagemann, C., Staab, A., Stojic, J., Kuhnel, S., Vince, G.H., Flentje, M., Roosen, K. and Vordermark, D. (2007) Expression patterns of the hypoxia-related genes osteopontin, CA9, erythropoietin, VEGF and HIF-1 α in human glioma *in vitro* and *in vivo*. *Radiotherapy and Oncology*, **83**, 398-405. [doi:10.1016/j.radonc.2007.05.003](https://doi.org/10.1016/j.radonc.2007.05.003)
- [9] Said, H.M., Polat, B., Staab, A., Hagemann, C., Stein, S., Flentje, M., Theobald, M., Katzer, A. and Vordermark, D. (2008) Rapid detection of the hypoxia-regulated CA-IX and NDRG1 gene expression in different glioblastoma cells *in vitro*. *Oncology Reports*, **20**, 413-419.
- [10] Ihnatko, R., Kubes, M., Takacova, M., Sedlakova, O., Sedlak, J., Pastorek, J., Kopacek, J. and Pastorekova, S. (2006) Extracellular acidosis elevates carbonic anhydrase IX in human glioblastoma cells via transcriptional modulation that does not depend on hypoxia. *International Journal of Oncology*, **29**, 1025-1033.
- [11] Ivanov, S., Liao, S.Y., Ivanova, A., Danilkovitch-Miagkova, A., Tarasova, N., Weirich, G., Merrill, M.J., Proescholdt, M.A., Oldfield, E.H., Lee, J., Zavada, J., Waheed, A., Sly, W., Lerman, M.I. and Stanbridge, E.J. (2001) Expression of hypoxia-inducible cell-surface transmembrane carbonic anhydrases in human cancer. *American Journal of Pathology*, **158**, 905-919.
- [12] Alterio, V., Hilvo, M., Di Fiore, A., Supuran, C.T., Pan, P., Parkkila, S., Scaloni, A., Pastorek, J., Pastorekova, S., Pedone, C., Scozzafava, A., Monti, S.M. and De Simone, G. (2009) Crystal structure of the catalytic domain of the tumor-associated human carbonic anhydrase IX. *Proceedings of the National Academy of Sciences USA*, **106**, 16233-16238. [doi:10.1073/pnas.0908301106](https://doi.org/10.1073/pnas.0908301106)
- [13] Baranauskienė, L., Hilvo, M., Matuliene, J., Golovenko, D., Manakova, E., Dudutiene, V., Michailoviene, V., Torresan, J., Jachno, J., Parkkila, S., Maresca, A., Supuran, C.T., Grazulis, S. and Matulis, D. (2010) Inhibition and binding studies of carbonic anhydrase isozymes I, II and IX with benzimidazo[1,2-c][1,2,3] thiadiazole-7-sulphonamides. *Journal of Enzyme Inhibition and Medicinal Chemistry*, **25**, 863-870. [doi:10.3109/14756360903571685](https://doi.org/10.3109/14756360903571685)
- [14] Montgomery, J.C., Venta, P.J., Eddy, R.L., Fukushima, Y.S., Shows, T.B. and Tashian, R.E. (1991) Characterization of the human gene for a newly discovered carbonic anhydrase, CA VII, and its localization to chromosome 16. *Genomics*, **11**, 835-848. [doi:10.1016/0888-7543\(91\)90006-Z](https://doi.org/10.1016/0888-7543(91)90006-Z)
- [15] Lakkis, M.M., Bergenhem, N.C. and Tashian, R.E. (1996) Expression of mouse carbonic anhydrase VII in *E. coli* and demonstration of its CO₂ hydrase activity. *Biochemical and Biophysical Research Communications*, **226**, 268-272. [doi:10.1006/bbrc.1996.1344](https://doi.org/10.1006/bbrc.1996.1344)
- [16] Vullo, D., Innocenti, A., Nishimori, I., Scozzafava, A., Kaila, K. and Supuran, C.T. (2007) Carbonic anhydrase activators: activation of the human isoforms VII (cytosolic) and XIV (transmembrane) with amino acids and amines. *Bioorganic and Medicinal Chemistry Letters*, **17**, 4107-4112. [doi:10.1016/j.bmcl.2007.05.052](https://doi.org/10.1016/j.bmcl.2007.05.052)
- [17] Gitto, R., Agnello, S., Ferro, S., Vullo, D., Supuran, C.T. and Chimirri, A. (2010) Identification of potent and selective human carbonic anhydrase VII (hCA VII) inhibitors. *ChemMedChem*, **5**, 823-826.
- [18] Halmi, P., Parkkila, S. and Honkaniemi, J. (2006) Expression of carbonic anhydrases II, IV, VII, VIII and XII in rat brain after kainic acid induced status epilepticus. *Neurochemistry International*, **48**, 24-30. [doi:10.1016/j.neuint.2005.08.007](https://doi.org/10.1016/j.neuint.2005.08.007)
- [19] Kleihues, P., Louis, D.N., Scheithauer, B.W., Rorke, L.B., Reifenberger, G., Burger, P.C. and Cavenee, W.K. (2002) The WHO classification of tumors of the nervous system. *Journal of Neuropathology and Experimental Neurology*, **61**, 215-225.
- [20] Louis, D.N., Ohgaki, H., Wiestler, O.D., Cavenee, W.K., Burger, P.C., Jouvet, A., Scheithauer, B.W. and Kleihues, P. (2007) The 2007 WHO classification of tumours of the central nervous system. *Acta Neuropathologica*, **114**, 97-109. [doi:10.1007/s00401-007-0243-4](https://doi.org/10.1007/s00401-007-0243-4)
- [21] Bootorabi, F., Janis, J., Smith, E., Waheed, A., Kukkurainen, S., Hytonen, V., Valjakka, J., Supuran, C.T., Vullo, D., Sly, W.S. and Parkkila, S. (2010) Analysis of a shortened form of human carbonic anhydrase VII expressed *in vitro* compared to the full-length enzyme. *Biochimie*, **92**, 1072-1080.
- [22] Leppilampi, M., Saarnio, J., Karttunen, T.J., Kivela, J., Pastorekova, S., Pastorek, J., Waheed, A., Sly and W.S., Parkkila, S. (2003) Carbonic anhydrase isozymes IX and XII in gastric tumors. *World Journal of Gastroenterology*, **9**, 1398-1403.
- [23] Haapasalo, H., Sallinen, S., Sallinen, P., Helen, P., Jaaskelainen, J., Salmi, T.T., Paetau, A., Paljarvi, L., Visakorpi, T. and Kalimo, H. (1999) Clinicopathological correlation of cell proliferation, apoptosis and p53 in cerebellar pilocytic astrocytomas. *Neuropathology and Applied Neurobiology*, **25**, 134-142. [doi:10.1046/j.1365-2990.1999.00157.x](https://doi.org/10.1046/j.1365-2990.1999.00157.x)
- [24] Jarvela, S., Helin, H., Haapasalo, J., Jarvela, T., Junttila, T.T., Elenius, K., Tanner, M., Haapasalo, H. and Isola, J. (2006) Amplification of the epidermal growth factor receptor in astrocytic tumours by chromogenic *in situ* hybridization: association with clinicopathological features and patient survival. *Neuropathology and Applied Neurobiology*, **32**, 441-450.
- [25] Haapasalo, J., Hilvo, M., Nordfors, K., Haapasalo, H., Parkkila, S., Hyrskyluoto, A., Rantala, I., Waheed, A., Sly, W.S., Pastorekova, S., Pastorek, J. and Parkkila, A.K. (2008) Identification of an alternatively spliced isoform of carbonic anhydrase XII in diffusely infiltrating astrocytic gliomas. *Neuro-Oncology*, **10**, 131-138.
- [26] Nordfors, K., Haapasalo, J., Korja, M., Niemela, A., Laine, J., Parkkila, A.K., Pastorekova, S., Pastorek, J., Waheed, A., Sly, W.S., Parkkila, S. and Haapasalo, H. (2010) The tumour-associated carbonic anhydrases CA II, CA IX and CA XII in a group of medulloblastomas and supratentorial primitive neuroectodermal tumours: an association of CA IX with poor prognosis. *BMC Cancer*,

- 10, 148. doi:10.1186/1471-2407-10-148
- [27] Maseide, K., Kandel, R.A., Bell, R.S., Catton, C.N., O'Sullivan, B., Wunder, J.S., Pintilie, M., Hedley and D., Hill, R.P. (2004) Carbonic anhydrase IX as a marker for poor prognosis in soft tissue sarcoma. *Clinical Cancer Research*, **10**, 4464-4471. doi:10.1158/1078-0432.CCR-03-0541
- [28] Kon-no, H., Ishii, G., Nagai, K., Yoshida, J., Nishimura, M., Nara, M., Fujii, T., Murata, Y., Miyamoto, H. and Ochiai, A. (2006) Carbonic anhydrase IX expression is associated with tumor progression and a poor prognosis of lung adenocarcinoma. *Lung Cancer*, **54**, 409-418.
- [29] Korkeila, E., Talvinen, K., Jaakkola, P.M., Minn, H., Syrjanen, K., Sundstrom, J. and Pyrhonen, S. (2009) Expression of carbonic anhydrase IX suggests poor outcome in rectal cancer. *British Journal of Cancer*, **100**, 874-880. doi:10.1038/sj.bjc.6604949
- [30] Liao, S.Y., Darcy, K.M., Randall, L.M., Tian, C., Monk, B.J., Burger, R.A., Fruehauf, J.P., Peters, W.A., Stock, R.J. and Stanbridge, E.J. (2010) Prognostic relevance of carbonic anhydrase-IX in high-risk, early-stage cervical cancer: A Gynecologic Oncology Group study. *Gynecological Oncology*, **116**, 452-458.
- [31] Klatte, T., Seligson, D.B., Rao, J.Y., Yu, H., De Martino M., Kawaoka, K., Wong, S.G., Belldegrun, A.S. and Pantuck, A.J. (2009) Carbonic anhydrase IX in bladder cancer: A diagnostic, prognostic, and therapeutic molecular marker. *Cancer*, **115**, 1448-1458.
- [32] Choi, S.W., Kim, J.Y., Park, J.Y., Cha, I.H., Kim, J. and Lee, S. (2008) Expression of carbonic anhydrase IX is associated with postoperative recurrence and poor prognosis in surgically treated oral squamous cell carcinoma. *Human Pathology*, **39**, 1317-1322.
- [33] Belldegrun, A.S. and Bevan, P. (2008) Carbonic anhydrase IX: Role in diagnosis prognosis and cancer therapy. Introduction. *British Journal of Urology International*, **101**, 1.
- [34] Hussain, S.A., Ganesan, R., Reynolds, G., Gross, L., Stevens, A., Pastorek, J., Murray, P.G., Perunovic, B., Anwar, M.S., Billingham, L., James, N.D., Spooner, D., Poole, C.J., Rea, D.W. and Palmer, D.H. (2007) Hypoxia-regulated carbonic anhydrase IX expression is associated with poor survival in patients with invasive breast cancer. *British Journal of Cancer*, **96**, 104-109.
- [35] Lakkis, M.M., O'Shea, K.S. and Tashian, R.E. (1997) Differential expression of the carbonic anhydrase genes for CA VII (Car7) and CA-RP VIII (Car8) in mouse brain. *Journal of Histochemistry and Cytochemistry*, **45**, 657-662.
- [36] Ruusuvauro, E., Li, H., Huttu, K., Palva, J.M., Smirnov, S., Rivera, C., Kaila, K. and Voipio, J. (2004) Carbonic anhydrase isoform VII acts as a molecular switch in the development of synchronous gamma-frequency firing of hippocampal CA1 pyramidal cells. *Journal of Neuroscience*, **24**, 2699-2707. doi:10.1523/JNEUROSCI.5176-03.2004
- [37] Said, H.M., Staab, A., Hagemann, C., Vince, G.H., Katzer, A., Flentje, M. and Vordermark, D. (2007) Distinct patterns of hypoxic expression of carbonic anhydrase IX (CA IX) in human malignant glioma cell lines. *Journal of Neurooncology*, **81**, 27-38.
- [38] Wykoff, C.C., Beasley, N.J., Watson, P.H., Turner, K.J., Pastorek, J., Sibtain, A., Wilson, G.D., Turley, H., Talks, K.L., Maxwell, P.H., Pugh, C.W., Ratcliffe, P.J. and Harris, A.L. (2000) Hypoxia-inducible expression of tumor-associated carbonic anhydrases. *Cancer Research*, **60**, 7075-7083.
- [39] Korkolopoulou, P., Perdiki, M., Thymara, I., Boviatsis, E., Agrogiannis, G., Kotsiakos, X., Angelidakis, D., Rologis, D., Diamantopoulou, K., Thomas-Tsagli, E., Kaklamanis, L., Gatter, K. and Patsouris, E. (2007) Expression of hypoxia-related tissue factors in astrocytic gliomas. A multivariate survival study with emphasis upon carbonic anhydrase IX. *Human Pathology*, **38**, 629-638.
- [40] Supuran, C.T. (2008) Carbonic anhydrases: novel therapeutic applications for inhibitors and activators. *Nature Reviews Drug Discovery*, **7**, 168-181. doi:10.1038/nrd2467
- [41] Pastorekova, S., Parkkila, S. and Zavada, J. (2006) Tumor-associated carbonic anhydrases and their clinical significance. *Advances in Clinical Chemistry*, **42**, 167-216. doi:10.1016/S0065-2423(06)42005-9
- [42] Xiang, Y., Ma, B., Yu, H.M. and Li, X.J. (2004) The protein profile of acetazolamide-treated sera in mice bearing Lewis neoplasm. *Life Science*, **75**, 1277-1285.
- [43] Supuran, C.T., Briganti, F., Tilli, S., Chegwiddden, W.R. and Scozzafava, A. (2001) Carbonic anhydrase inhibitors: sulfonamides as antitumor agents? *Bioorganic and Medicinal Chemistry*, **9**, 703-714. doi:10.1016/S0968-0896(00)00288-1
- [44] Supuran, C.T. (2003) Indisulam: An anticancer sulfonamide in clinical development. *Expert Opinion on Investigational Drugs*, **12**, 283-287.