

Immunohistochemical Examination of E-Cadherin in the Head and Neck Squamocellular Carcinomas

Elisabeta Maria Vasca¹, Ioana Lile¹, Amalia Luce², Domenico Napolitano³,
Filippo Ricciardiello⁴, Teresa Abate⁴, Michele Caraglia², Tatiana Duminica¹, Virgil Vasca¹

¹Faculty of Medicine, Pharmacy and Dental Medicine, "Vasile Goldiş" Western University of Arad, Arad, Romania

²Department of Biochemistry, Biophysics and General Pathology, Second University of Naples, Naples, Italy

³ENT Division, A.O.R.N. Cardarelli, Naples, Italy

⁴ENT Complex Operative Unit, Naples University "Federico II", Naples, Italy

Email: vasca.elisabeta@yahoo.com, ioana.lile@yahoo.com, alma2104@libero.it,
domenico.napolitano@libero.it, filipporicciardiello@virgilio.it, abate.teresa@yahoo.it,
michele.caraglia@unina2.it, duminica.tatiana@gmail.com, vasca.virgil@yahoo.com

Received 25 August 2014; revised 24 September 2014; accepted 20 October 2014

Copyright © 2014 by authors and Scientific Research Publishing Inc.

This work is licensed under the Creative Commons Attribution International License (CC BY).

<http://creativecommons.org/licenses/by/4.0/>



Open Access

Abstract

E-cadherin is present in the epithelial cells and its aberrant expression is correlated with different kinds of head and neck squamocellular carcinomas. The purpose of the present study was to identify the expression particularities of analyzed E-cadherin in rapport with the localization and the differentiation of various head and neck squamocellular carcinomas. 18 biopsy fragments obtained by squamocellular carcinoma patients (larynx, pharynx, hard palate, tongue, submandibular, lip, gingival sulcus, nasal pyramid, maxillary, zygomatic) were processed by immunohistochemical staining. Immunoreactions for E-cadherin in the tumoral cells were examined according to the score: 0 (0% positive cells of specimen); 1 (<10% positive cells of specimen); 2 (10% - 30% of specimen); 3 (>30% of specimen). The immunohistochemical staining indicated the presence of 12 cases of well-differentiated squamocellular carcinoma (7 cases with score 3, 3 cases with score 2 and 1 case with score 1). Moderately-differentiated carcinomas were observed in the 3 cases (2 with score 2 and 1 with score 1). The poorly-differentiated histopathological type was present in 3 cases (all with score 1). Three types of E-cadherin distribution patterns were found: cytoplasmatic; cytoplasmatic and membranar; membranar. The presence of maximum score (value 3) of E-cadherin was found in well-differentiated squamocellular carcinomas of laryngeal, tongue, lip, nasal pyramid, and zygomatic area origin. A lower value of the score was present in the less differentiated histopathological type.

How to cite this paper: Vasca, E.M., et al. (2014) Immunohistochemical Examination of E-Cadherin in the Head and Neck Squamocellular Carcinomas. *International Journal of Otolaryngology and Head & Neck Surgery*, 3, 330-336.
<http://dx.doi.org/10.4236/ijohns.2014.36059>

Keywords

Head and Neck Cancer, E-Cadherin, Cellular Adhesion, Differentiation Degree

1. Introduction

Cadherins, whose name derives from “calcium-dependent adhesion”, represent a class of type 1 of transmembranar proteins [1]. They play an important role in the cellular adhesion and insure the connection of the tissue cells. They depend on the presence of calcium ions-explaining thus the provenience of the name. There are several classes of cadherins, named with a prefix that usually refers to the type of tissue they associated with [2]. Cadherins have been classified into four types: classical, desmosomal, protocadherin and nonconventional. N-cadherin, P-cadherin, and E-cadherin (which is found in the epithelial tissues) belong to the group of classical cadherins.

E-cadherin (ECAD) glycoprotein (codified by gene CDH1, situated on the 16q22.1 chromosome) has an important role in establishing and maintaining the intercellularly contacts and morphogenesis. The terminal cytoplasmatic end of ECAD molecule has proved to be linked to the actin of the cytoskeleton by means of α -catenin and β -catenin [3].

The head and neck squamocellular carcinomas (HNSCC) represent a frequent malignant condition with significant incidence and mortality [4] [5]. The larynx and oral cavity are the main anatomical regions of the head and neck which have a high risk of developing squamocellular carcinomas [6]. A 2008 classification situated the neoplasms of the oral cavity (including lip cancer) in the category of 1,263,900 new cases and 128,000 deaths per year worldwide [7] [8].

The aberrant expression of E-cadherins was associated with the invasive character of neoplasms and the onset of metastasis in different types of carcinomas including those of the head and neck [2] [3].

There are several mechanisms for the abnormal expression of ECAD in cancer, including the loss of CDH1 allelic locus, as well as somatic and more rarely, germline mutations. Regression of ECAD transcription by hypermethylation was also observed in several tumoral types and cell lines [9] [10]. It has been shown that the reduced expression of ECAD in the esophageal adenocarcinoma is correlated with a negative prognosis [5] [11].

Despite progresses in the surgical treatment and radiotherapy of the latest years, the prognosis is still negative in the advanced cases [12] [13].

The aim of the present study was to identify the particularities of E-cadherin expression analyzed in rapport with the localization in different head and neck regions [14] [15].

2. Materials and Methods

Our study included a number of 18 biopsy fragments obtained by patients with squamocellular carcinoma—7 at the level of the larynx, 2 with pharyngeal origin, 1 from hard palate, 1 from tongue, 1 submandibular, 2 from the lip, 1 from gingival sulcus, 1 from nasal pyramid, 1 maxillary and 1 zygomatic.

All the patients approved the research and accorded with the publication of data.

The biopsy fragments were fixed in tamponated formalin 10% for 48 hours, then included in paraffin. Sections with 5 micrometers thickness were obtained by each case. Deparaffinization and rehydration of the sections was followed by exposure to heat, pH 6 solution for 30 minutes. The immunohistochemical staining was continued with a blockage of the endogeneous peroxidase by using oxygenated water 3%. Incubation with primary antibody E-cadherin (clone 36B5, ready to use, Novocastra, Newcastle upon Tyne, UK) was made for 15 minutes. As a technique, we used LSAB \pm HRP applied for 30 minutes. The chromogene used was 3,3-diaminobenzidine, and for counter-coloration we applied modified Lille hematoxylin. All the stages of the immunohistochemical staining were carried out with the help of the immunohistochemistry automaton (Dako Cytomation Autostainer). The microscopic examination was performed with microscope Nikon Eclipse E 600 and the images were obtained by using the LUCIA G system. Immunoreactions for ECAD in the tumoral cells were examined according to the following score: 0 (0% positive cells of specimen), 1 (<10% positive cells), 2 (10% - 30%), 3 (>30%).

3. Results

The morphological staining indicated the presence of 12 cases of well-differentiated squamocellular carcinomas (5 laryngeal cases, 2 pharyngeal, 2 from the lip, 1 from the tongue, 1 from the zygomatic area, 1 from the nasal pyramid). Moderately-differentiated carcinomas were observed in the 2 cases of larynx and in 1 case of hard palate. The poorly-differentiated histopathological type was present in cases derived by the region of the gingival sulcus, upper maxillary and submandibular areas (1 in each case).

The immunohistochemical reaction for E-cadherin was present in all the cases included in the study. The tumoral cells expressed E-cadherin in different percentages with values of the score ranging between 1 and 3. The intensity of the immunohistochemical reaction varied between 1—weak, 2—moderate and 3—intense, with two models of distribution-homogeneous and heterogeneous in the same tumoral region. 3 patterns of expression were observed: membranar, cytoplasmatic and membranar, cytoplasmatic (Figure 1).

For the squamocellular carcinomas localized in the laryngeal area, we noticed the following values of the score: score 3 (more than 30% positive tumoral cells for E-cadherine) in two cases, score 2 (10% - 30% tumoral cells expressed E-cadherin) in four cases and score 1 (less than 10% positive tumoral cells) in one of the cases.

In one of the cases with score 3, we observed a distribution in the whole tumoral area but the expression pattern was cytoplasmatic in the cells at the peripheral area, while in the center the cytoplasmatic and of membranar expression prevailed or the membranar one. The intensity of the immunohistochemical staining was maximum in the central cells of the tumoral area. The second case of laryngeal area quantified with score 3, presented both cytoplasmatic and membranar pattern but also only membranar, the latter one prevailing (Figure 2).

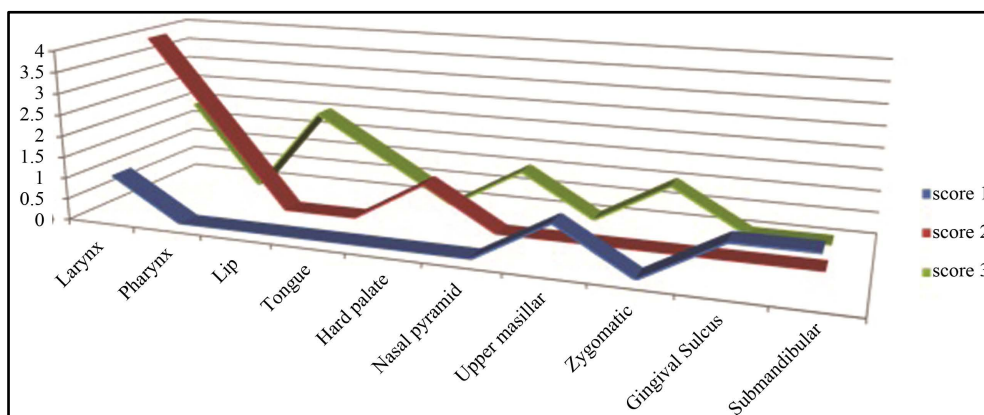


Figure 1. Rapport between the number of cases, score and the anatomical regions.

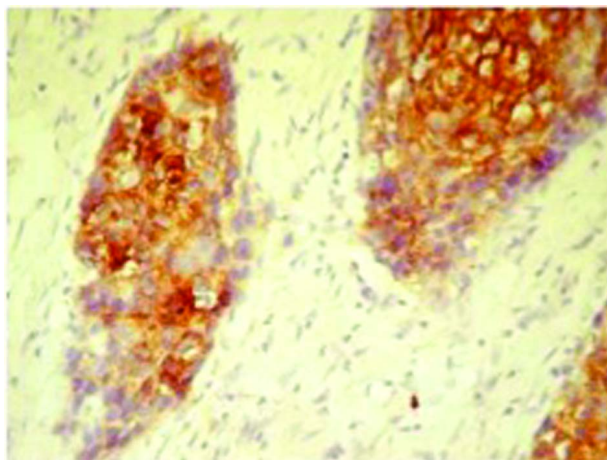


Figure 2. Squamocellular carcinoma. Immunohistochemical staining for E-cadherin with laryngeal origin, score 3, membranar and/or cytoplasmatic expression pattern, distribution in the whole tumoral area, magnification $\times 20$.

In two of the score 2 cases, we observed the variation of E-cadherin expression when crossing from the quasi-normal area to the hyperplasia area and then to the tumoral one. In the tumoral area, the E-cadherin expression in the surface epithelium decreases and increases in the tumoral region where it presents a membranar prevailing pattern, average intensity of reaction, and a homogeneous distribution pattern in the whole tumoral area (**Figures 3(A)-(C)**).

The other two cases with laryngeal origin with score 2, presented all three patterns of expression: cytoplasmatic, cytoplasmatic and membranar and membranar, but the membranar was prevailed. The intensity of the immunohistochemical staining was similar to the score.

In the laryngeal squamocellular carcinoma with score 1 the cytoplasmatic pattern prevailed, homogeneous distribution in the whole tumoral area and the intensity of the immunohistochemical reaction was similar to the score. In this case, we observed the presence of mitosis with high frequency (**Figure 4(A)**).

The two cases of squamocellular carcinomas with pharyngeal origin belonging to the well-differentiated type, presented an E-cadherin expression in 10% - 30% of the tumoral cells, that is score 2. We observed different intensities of the immunohistochemical staining in different tumoral area while an homogeneous intensity in the same region. The values of the immunohistochemical staining were close to those of the percentage score 2 and 3. The distribution pattern was homogeneous with positive cells in the entire tumoral area. The expression pattern was cytoplasmatic, membranar, cytoplasmatic and membranar. In some cases we detected a prevailing cytoplasmatic pattern in the cells from the center of the tumoral region and intensity score 3 of the immunohistochemical staining in these cells. In the second case cytoplasmatic and membranar pattern prevailed but the other patterns were also present (cytoplasmatic, membranar) in the tumoral region (**Figure 4(B)**).

For the squamocellular carcinoma with tongue origin, well-differentiated as histopathological type, we observed a score 3 that indicates the percentage of tumoral cells which are positive to E-cadherin. We observed a homogeneous distribution in all the cells of the tumoral region with a cytoplasmatic and membranar prevailing expression pattern and higher intensity of the reaction in the cells situated in the center of the tumoral region (**Figures 5(A)-(B)**).

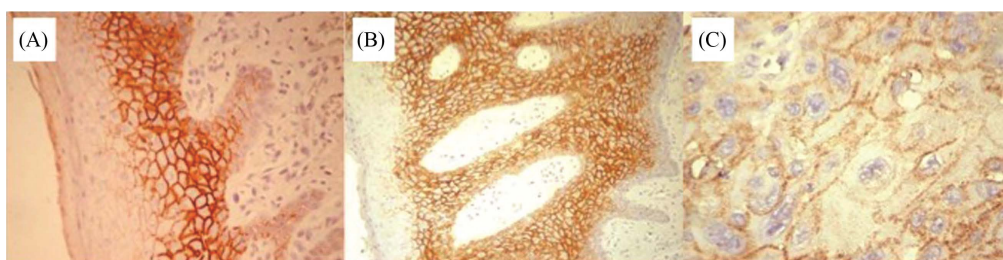


Figure 3. Immunohistochemical staining for E-cadherin: (A) Quasi-normal epithelium, magnification $\times 20$; (B) Hyperplasia region, magnification $\times 10$; (C) Average intensity, membranar pattern, homogeneous distribution in the whole tumoral area, magnification $\times 40$.

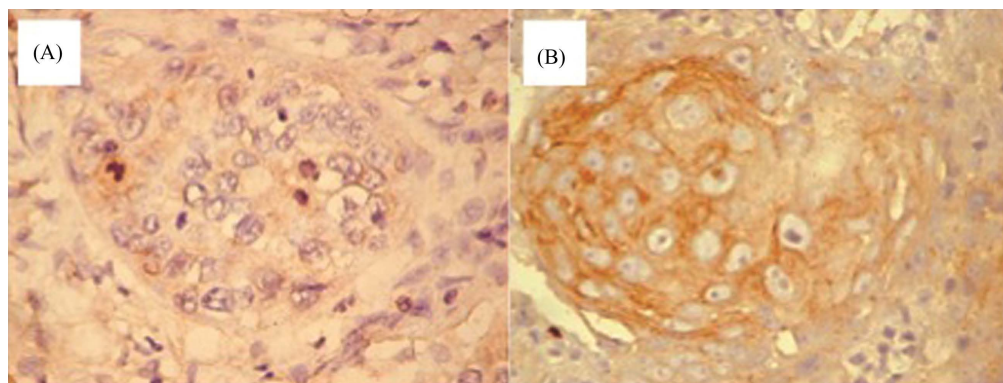


Figure 4. Immunohistochemical staining for E-cadherin: (A) Well-differentiated squamocellular carcinoma, score 1, magnification $\times 40$; (B) Pharyngeal carcinoma, the cytoplasmatic and membranar pattern prevails, magnification $\times 40$.

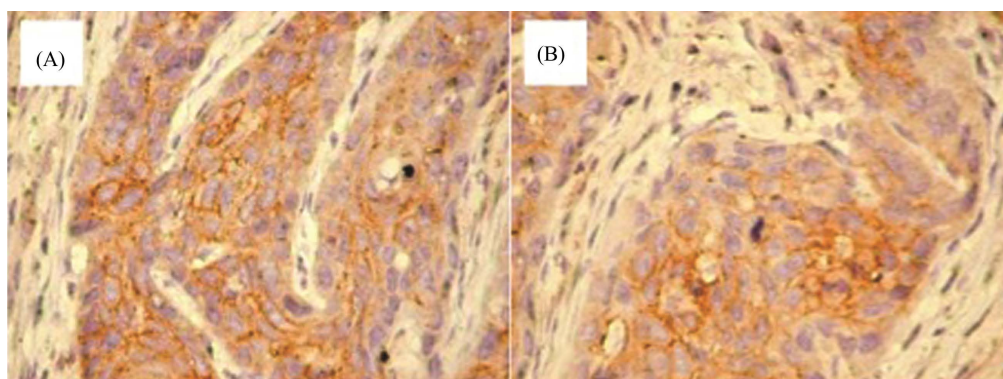


Figure 5. Immunohistochemical staining for E-cadherin: (A) Squamocellular carcinoma with tongue origin, score 3, higher intensity of the staining in the cells from the center of the tumoral areas, magnification $\times 20$; (B) Squamocellular carcinoma of the tongue, cytoplasmatic and membranar prevailing pattern, magnification $\times 40$.

Both well-differentiated squamocellular carcinomas with lip origin presented a score 3 value. We also observed an intense immunohistochemical staining with membranar prevailing pattern in particular in the cells from the center of the tumoral areas (**Figures 6(A)-(B)**). Isolated, we also observed the presence of the cytoplasmatic and cytoplasmatic and membranar patterns.

In the case of the well-differentiated squamocellular carcinoma, localized in the zygomatic area, we noted a percentage of more than 30% of tumoral cells that are positive to E-cadherin, score 3. The distribution pattern was homogeneous in the entire tumoral area and from the three cytoplasmatic and cytoplasmatic and membranar patterns prevailed (**Figure 7(A)**).

The squamocellular carcinoma localized in the area of the nasal pyramid presented score 3 of E-cadherin, distribution of the tumoral cells in the whole area, cytoplasmatic and membranar patterns of expression (**Figure 7(B)**).

The squamocellular carcinoma localized at the level of the hard palate, belonged to the moderately-differentiated type, expressed E-cadherin in the tumoral cells in a percentage of 10% - 30% (score 2). The intensity of the immunohistochemical staining was similar to the score, the distribution was homogeneous both in the center as well as at the periphery of the tumoral regions. Considering the three patterns of expression, cytoplasmatic, membranar, cytoplasmatic and membranar, the membranar had the highest occurrence.

For the poorly-differentiated carcinomas as histopathological type, of the upper maxillary area, and of submandibular or gingival sulcus we observed score 1—less than 10% positive tumoral cells (**Figure 7(C)**). We observed the alternance of some tumoral islands, homogeneous, positive for E-cadherin with tumoral areas where E-cadherin expression was missing. In the positive areas, the intensity of the immunohistochemical staining was 2 or 3, all three types of expression were present but the cytoplasmatic expression prevailed and isolated, the membranar one (the submandibular area), the membranar and cytoplasmatic and membranar (the upper maxillary), cytoplasmatic and cytoplasmatic and membranar (gingival sulcus).

4. Discussion

The studies carried out in different types of cancer researched the involvement of E-cadherin in the tumoral suppression. At an experimental level, the suppression of E-cadherin function or expression induce mesenchymal morphology and an increased cell migration and invasion as well as a tendency to metastasis. The tumoral suppressor role of E-cadherin was demonstrated or suggested in a variety of epithelial neoplasms: the hepatocellular carcinoma, the head and neck, skin, esophagus squamocellular carcinoma, the melanoma.

A study carried out by Rosado and colab. [16], which focused on the E-cadherin and β -catenin expression in the patients with head and neck squamocellular carcinoma, indicated the presence of the expression in all the cases included in the study.

We have also noticed this aspect; all the 18 cases studied presented a score of the expression with values ranging between 1 and 3. About the expression patterns observed, the authors observed the cytoplasmatic

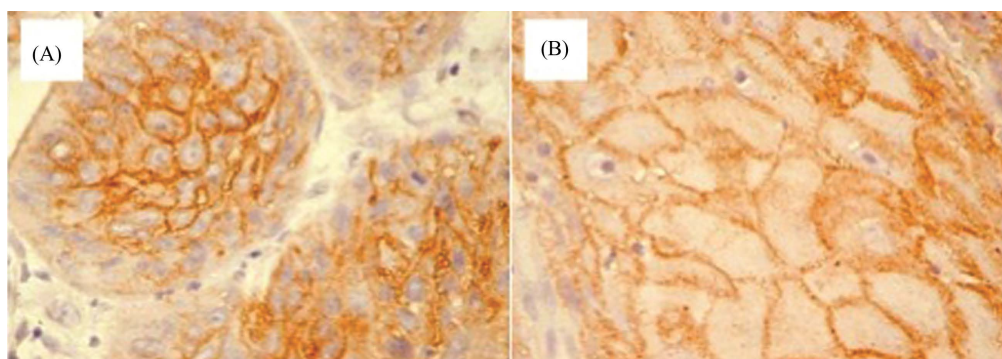


Figure 6. Immunohistochemical staining for E-cadherin: (A) Squamocellular carcinoma with lip origin, score 3, intense reaction in the cells from the center of the tumoral area, magnification $\times 40$; (B) Squamocellular carcinoma of the lip, membranar pattern, magnification $\times 40$.

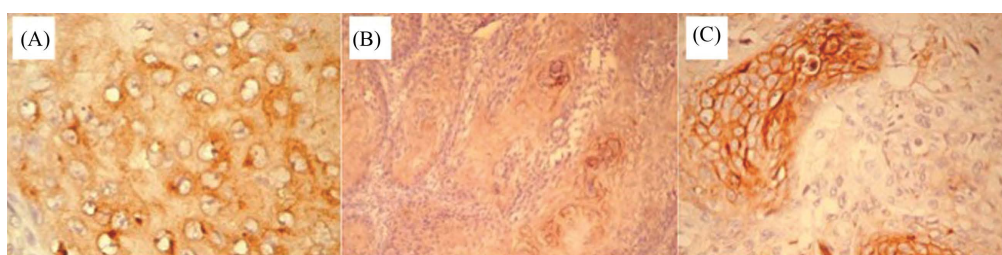


Figure 7. Immunohistochemical staining for E-cadherin: (A) Squamocellular carcinoma, the zygomatic area, cytoplasmatic and cytoplasmatic and membranar pattern, magnification $\times 40$; (B) Squamocellular carcinoma, the nasal pyramid, score 3, magnification $\times 20$; (C) Squamocellular carcinoma, the upper maxillary, score 1, magnification $\times 40$.

expression in just one of the cases, all the others having a cytoplasmatic and membranar pattern. We observed this latter pattern in most of the cases, but associated with isolated cells with cytoplasmatic or membranar expression (especially in the lip carcinomas).

A study performed by Wu and colabs. [17] indicated the E-cadherin expression in most of the well-differentiated squamocellular carcinomas with head and neck, lung, skin, esophagus or cervical origin in proportion of 75% - 100%, while less than 40% of the poorly-differentiated squamocellular carcinomas expressed E-cadherin. Schipper and colabs. [1] analyzed the E-cadherin expression inside head and neck squamocellular carcinomas and noted an intense expression in the well-differentiated carcinomas localized in this region, moderated in the moderately-differentiated ones and absent in those poorly-differentiated. All the cases that we have analyzed, irrespective of the histopathological type, expressed E-cadherin. The percentage of tumoral cells, quantified by values of the score ranging between 1 and 3 presented value 1 in the poorly-differentiated carcinomas. We found presence of E-cadherin with maximum score, value 3, in the well-differentiated squamocellular carcinomas with laryngeal, tongue, lip, nasal pyramid, zygomatic area origin. In our samples we noticed alternate areas where the E-cadherin expression was absent or positive and reduced areas in the poorly-differentiated carcinomas. Variable patterns of expression were found: cytoplasmatic, membranar, cytoplasmatic and membranar. A lower value of the score was present in the histopathological type less differentiated.

5. Conclusion

The role of E-cadherin in the squamocellular carcinomas is far from being clarified. It seems that the trials to estimate a prognosis in this clinical entity should include a combination between the molecular markers, the histopathological data and clinical parameters.

References

- [1] Schipper, H., Frixen, U.H., Behrens, J., Unger, A., Jahnke, K. and Birchmeier, W. (1991) E-Cadherin Expression in

- Squamous Cell Carcinomas of Head and Neck: Inverse Correlation with Tumor Dedifferentiation and Lymph Node Metastasis. *Cancer Research*, **51**, 6328-6337.
- [2] Finkel, T. and Holbrook, N.J. (2000) Oxidants, Oxidative Stress and the Biology of Ageing. *Nature*, **408**, 239-247. <http://dx.doi.org/10.1038/35041687>
 - [3] Arcasoy, M.O., Jiang, X. and Haroon, Z.A. (2003) Expression of Erythropoietin Receptor Splice Variants in Human Cancer. *Biochemical and Biophysical Research Communications*, **307**, 999-1007. [http://dx.doi.org/10.1016/S0006-291X\(03\)01303-2](http://dx.doi.org/10.1016/S0006-291X(03)01303-2)
 - [4] Fong, L. and Engleman, E.G. (2000) Dendritic Cells in Cancer Immunotherapy. *Annual Review of Immunology*, **18**, 245-273. <http://dx.doi.org/10.1146/annurev.immunol.18.1.245>
 - [5] Kovács, A.F. (2006) Maximized Combined Modality Treatment of an Unselected Population of Oral and Oropharyngeal Cancer Patients. Final Results of a Pilot Study Compared with a Treatment-Dependent Prognosis Index. *Journal of Cranio-Maxillo-Facial Surgery*, **34**, 74-84. <http://dx.doi.org/10.1016/j.jcms.2005.09.003>
 - [6] Kovács, A.F., Döbert, N., Gaa, J., Menzel, C. and Bitter, K. (2004) Positron Emission Tomography in Combination with Sentinel Node Biopsy Reduces the Rate of Elective Neck Dissections in the Treatment of Oral and Oropharyngeal Cancer. *Journal of Clinical Oncology*, **22**, 3973-3980. <http://dx.doi.org/10.1200/JCO.2004.01.124>
 - [7] Buduneli, N., Kardeşler, L., Işık, H., Willis III, C.S., Hawkins, S.I., Kinane, D.F. and Scott, D.A. (2006) Effects of Smoking and Gingival Inflammation on Salivary Antioxidant Capacity. *Journal of Clinical Periodontology*, **33**, 159-164. <http://dx.doi.org/10.1111/j.1600-051X.2006.00892.x>
 - [8] Bucur, A., Navarro Vila, C., Lowry, J. and Acero, J. (2009) Compendiu de chirurgie oro-maxilo-faciala.
 - [9] Balkwill, F. and Mantovani, A. (2001) Inflammation and Cancer: Back to Virchow? *Lancet*, **357**, 539-545. [http://dx.doi.org/10.1016/S0140-6736\(00\)04046-0](http://dx.doi.org/10.1016/S0140-6736(00)04046-0)
 - [10] Tumuluri, V., Thomas, G.A. and Fraser, I.S. (2002) Analysis of the Ki-67 Antigen at the Invasive Tumour Front of Human Oral Squamous Cell Carcinoma. *Journal of Oral Pathology & Medicine*, **31**, 598-604. <http://dx.doi.org/10.1034/j.1600-0714.2002.00042.x>
 - [11] Takane, M., Sugano, N., Ezawa, T., Uchiyama, T. and Ito, K. (2005) A Marker of Oxidative Stress in Saliva: Association with Periodontally-Involved Teeth of a Hopeless Prognosis. *Journal of Oral Science*, **47**, 53-57. <http://dx.doi.org/10.2334/josnusd.47.53>
 - [12] Borek, C. (2004) Dietary Antioxidants and Human Cancer. *Integrative Cancer Therapies*, **3**, 333-341. <http://dx.doi.org/10.1177/1534735404270578>
 - [13] Baselga, J. and Swain, S.M. (2009) Novel Anticancer Targets: Revisiting ERBB2 and Discovering ERBB3. *Nature Reviews Cancer*, **9**, 463-475. <http://dx.doi.org/10.1038/nrc2656>
 - [14] Arcasoy, M.O., Amin, K., Karayal, A.F., Chou, S.C., Raleigh, J.A., Varia, M.A. and Haroon, Z.A. (2002) Functional Significance of Erythropoietin Receptor Expression in Breast Cancer. *Laboratory Investigation*, **82**, 911-918. <http://dx.doi.org/10.1097/01.LAB.0000020415.72863.40>
 - [15] Lalli, A., Tilakaratne, W.M., Ariyawardana, A., *et al.* (2008) An Altered Keratinocyte Phenotype in Oral Submucous Fibrosis: Correlation of Keratin K17 Expression with Disease Severity. *Journal of Oral Pathology & Medicine*, **37**, 211-220. <http://dx.doi.org/10.1111/j.1600-0714.2007.00609.x>
 - [16] Rosado, P., Lequerica-Fernández, P., Fernández, S., Allonca, E., Villallain, L. and de Vicente, J.C. (2013) E-Cadherin and β -Catenin Expression in Well-Differentiated and Moderately-Differentiated Oral Squamous Cell Carcinoma: Relations with Clinical Variables. *British Journal of Oral and Maxillofacial Surgery*, **51**, 149-156. <http://dx.doi.org/10.1016/j.bjoms.2012.03.018>
 - [17] Wu, H., Lotan, R., Menter, D., Lippman, S.M. and Xu, X.C. (2000) Expression of E-Cadherin Is Associated with Squamous Differentiation in Squamous Cell Carcinomas. *Anticancer Research*, **20**, 1385-1390.

Scientific Research Publishing (SCIRP) is one of the largest Open Access journal publishers. It is currently publishing more than 200 open access, online, peer-reviewed journals covering a wide range of academic disciplines. SCIRP serves the worldwide academic communities and contributes to the progress and application of science with its publication.

Other selected journals from SCIRP are listed as below. Submit your manuscript to us via either submit@scirp.org or [Online Submission Portal](#).

