

Isolated Full Thickness Jejunal Necrosis Following Sulphuric Acid Cocktail Ingestion—A Clinical Case Report

—Isolated Corrosive Jejunal Necrosis

S. S. Pankaja, George J. Valooran, Sri Aurobindo Prasad Das, L. Suvasini, R. Aravind,
Vikram Kate, Pankaj Kundra *

*Departments of Surgery and Anaesthesiology, Jawaharlal Institute of Postgraduate Medical
Education and Research, Puducherry, India*

*E-mail: *drvikramkate@gmail.com*

Received February 16, 2011; revised March 24, 2011; accepted May 16, 2011

Abstract

Isolated involvement of the lower gastrointestinal tract with relative sparing of the oesophagus and the stomach is extremely rare following corrosive agent ingestion. We report a case of isolated full thickness jejunal necrosis following sulphuric acid cocktail ingestion. A 42 year old man presented with history of consuming 200 ml of sulphuric acid mixed with alcohol, with suicidal intent. On exploration there were multiple, full thickness necrotic areas in the proximal jejunum with minimal congestion of the oesophagus, stomach and duodenum. Inversion of the jejunal necrotic areas with feeding jejunostomy was carried out. However postoperatively patient developed progressive pulmonary insufficiency with features of sepsis and expired on the nineteenth day following a bout of massive haematemesis. Corrosive agents when taken in considerable amount mixed with other fluids can lead to full thickness small bowel necrosis with relative sparing of the proximal gastrointestinal tract.

Keywords: Corrosive Injury, Acid Ingestion, Bowel Necrosis

1. Introduction

Accidental or suicidal ingestion of sulphuric and hydrochloric acids, leading to esophagogastric injury is not uncommon [1-3]. The site, extent and intensity of damage depend on the multiple factors related to the caustic agent, duration of contact and the victim [4]. Concomitant acid injury of the lower gastrointestinal tract is a rare occurrence due to acid induced pylorospasm with consequent gastric pooling, and neutralizing effect of the bile [1,5-7]. However, isolated necrosis of the lower gastrointestinal tract with relative sparing of the proximal gastrointestinal tract is extremely rare with limited reports [2,4,5]. Here we present a case of isolated full thickness jejunal necrosis with relative sparing of the proximal gastrointestinal tract following sulphuric acid cocktail ingestion.

2. The Case

A 42 year old manual labourer presented to emergency

department with history of having consumed battery sulphuric acid mixed with alcohol, around 200 ml, under the influence of alcohol with suicidal intent 3 hours prior to presentation. Following ingestion patient had vomiting which had both fresh and altered blood and developed severe burning pain in epigastric and retrosternal regions. At presentation patient was severely agitated. Abdominal examination revealed mild epigastric guarding, tenderness and normal bowel sounds. As patient had mild epigastric guarding upper gastrointestinal endoscopy was not performed as there was a likely risk of perforation due to inflation for endoscopy. Initial arterial blood gas analysis revealed severe metabolic acidosis. Skiagram of the chest, electrocardiogram and other biochemical tests including serum amylase were normal. Patient was resuscitated, started on antibiotics and shifted to surgical intensive care unit.

Two days later, patient developed abdominal distension with peritoneal signs for which he was posted for an exploratory laparotomy. Considering the patient being full stomach and scheduled for emergency laparotomy,

an awake, orotracheal fiberoptic tracheal intubation was performed under local anaesthesia. On exploration there were multiple areas of full thickness necrosis in the proximal jejunum (**Figure 1**) starting from duodeno-jejunal flexure for a length of two feet. As the necrotic areas were in close proximity to the duodeno-jejunal flexure and there were no obvious large areas of full thickness necrosis, resection of the involved was not carried out. The lower end of oesophagus, stomach, duodenum were minimally congested whereas the rest of the intestine and colon were appearing normal. There was saponification of the omentum and two litres of blood stained fluid in the peritoneal cavity. 18 size Ryle's tube was inserted intra operatively into the stomach successfully. All the necrotic areas were inverted in two layers by seromuscular sutures and a feeding jejunostomy was carried out. Postoperatively ventilatory support was continued. Patient continued to deteriorate developing features of sepsis, multi-organ dysfunction and expired on 19th postoperative day following a massive bout of haematemesis. Autopsy findings included a congested oesophageal and gastric mucosa with evidence of grade I/II oesophageal varices, multiple necrotic areas over jejunum without evidence of free perforation, and features of cirrhosis in the liver.

3. Discussion

Accidental or suicidal ingestion of caustic substances is common as they are present in many household products such as toilet cleansers, antirust compounds, battery fluid etc. [3,4]. Self poisoning is associated with higher grade of injury. Characteristic features in acid ingestion include severe injury to the stomach, particularly antropyloric region and relative sparing of the oesophagus. However following gastric surgeries involving pyloric ablation,

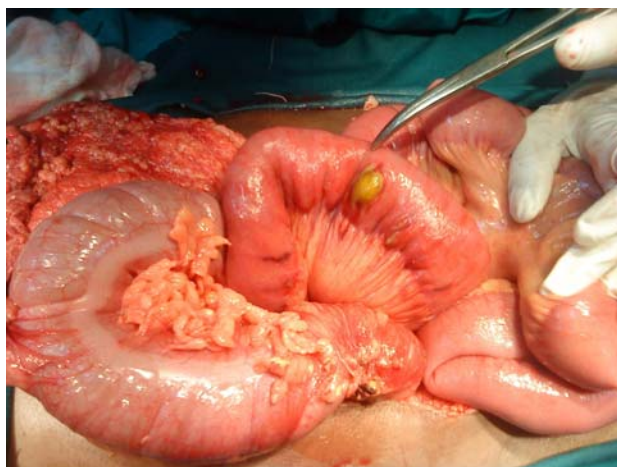


Figure 1. Full thickness necrotic area in the jejunum without perforation.

ingested acid can enter the small intestine rapidly and can cause significant injury [8]. Due to contact burns and bitter taste concentrated acids are usually vomited out thereby producing lesser damage whereas dilute acids will be ingested in relatively larger amount and can lead to significant injury of the digestive tract [4]. In the present case dilution of acid with alcohol has led to a significant corrosive injury to the proximal jejunum rather when compared to the oesophagus or the stomach. However it has been reported that strong acids when taken in considerable amount can lead to injury beyond the stomach causing extensive necrosis of the small intestine and colon [5,6].

Diagnosis can be made by clinical examination, imaging and endoscopy in stable cases whereas in unstable cases clinical examination and imaging are used for the diagnosis. Although antibiotics and steroids are used, their role is still controversial. Early surgical intervention, performed when indicated, has been reported to improve the prognosis. In the present case there were no early clinical signs or imaging finding necessitating emergent laparotomy at presentation. At exploration resection of all the necrotic tissues is recommended [5]. However, in the present case resection was not done as patient had very small but multiple necrotic patches just distal to the duodeno-jejunal flexure. There are reports of successful management of corrosive jejunal perforation with simple closure [7].

This case highlights that although corrosive acid injury commonly involves oesophagus and stomach, when taken in considerable amount mixed with other fluids, it can enter the small bowel in significant amount causing full thickness necrosis with relative sparing of the proximal gastrointestinal tract.

4. References

- [1] J. P. Thornton, "Surgical Management of corrosive Gastric Injuries," *Journal of the National Medical Association*, Vol. 66, No. 1, 1974, pp. 53-55.
- [2] J. B. Dilawari, S. Singh, P. N. Rao and B. S. Anand, "Corrosive Acid Ingestion in Man—A Clinical and Endoscopic Study," *Gut*, Vol. 25, No. 2, 1984, pp. 183-187. [doi:10.1136/gut.25.2.183](https://doi.org/10.1136/gut.25.2.183)
- [3] K. Ramasamy and V. V. Gumaste "Corrosive Ingestion in Adults," *Journal of Clinical Gastroenterology*, Vol. 37, No. 2, 2003, pp. 119-124. [doi:10.1097/00004836-200308000-00005](https://doi.org/10.1097/00004836-200308000-00005)
- [4] S. Sharma, P. R. Debnath, L. D. Agarwal and V. Gupta, "Gastric Outlet Obstruction without Esophageal Involvement: A Late Sequelae of Acid Ingestion in Children," *Journal of Indian Association of Pediatric Surgeons*, Vol. 12, No. 1, 2007, pp. 47-49. [doi:10.4103/0971-9261.31094](https://doi.org/10.4103/0971-9261.31094)

- [5] P. Cattani, N. Munoz-Bongrand, T. Berney, B. Halimi, E. Sarfati and M. Celerier, "Extensive abdominal surgery after caustic ingestion," *Annals of Surgery*, Vol. 231, No. 4, 2000, pp. 519-523.
[doi:10.1097/00000658-200004000-00010](https://doi.org/10.1097/00000658-200004000-00010)
- [6] Q. Zeng, H. Zhou, X. Zheng, Z. Li, M. Zhou, S. Han, *et al.*, "Total Gastrointestinal Tract Necrosis after Ingesting a Considerable Amount of Hydrochloric Acid," *Journal of Gastrointestinal Surgery*, Vol. 13, No. 3, 2009, pp. 578-80. [doi:10.1007/s11605-008-0524-9](https://doi.org/10.1007/s11605-008-0524-9)
- [7] O. Boybeyi, I. Karnak, F. C. Tanyel and M. E. Senocak, "Management of Unusually Extensive Esophagogastric Corrosive Injuries: Emergency Measures and Gastric Reconstruction," *Journal of Pediatric Surgery*, Vol. 44, No. 5, 2009, pp. 1022-1026.
[doi:10.1016/j.jpedsurg.2009.02.001](https://doi.org/10.1016/j.jpedsurg.2009.02.001)
- [8] J. M. Chang, M. H. Wu, W. W. Lai, M. Y. Lin, Y. F. Tsai, I. L. Hsu, *et al.*, "Acid Corrosive Injury in Patients with a History of Partial Gastrectomy: Outcome Analysis," *Digestive Surgery*, Vol. 24, No. 3, 2007, pp. 202-207.
[doi:10.1159/000102900](https://doi.org/10.1159/000102900)