

# Swinging Eyelid Procedure: An Useful Approach for Reduction of Zygomaticomalar Fracture

Hirohiko Kakizaki<sup>1\*</sup>, Yasuhiro Takahashi<sup>1</sup>, Hidetaka Miyazaki<sup>2</sup>, Akihiro Ichinose<sup>3</sup>, WengOnn Chan<sup>4</sup>

<sup>1</sup>Department of Ophthalmology, Aichi Medical University, Nagakute, Aichi, Japan

<sup>2</sup>Department of Stomatology and Oral Surgery, Gunma University Graduate School of Medicine, Maebashi, Gunma, Japan

<sup>3</sup>Department of Plastic Surgery, Kobe University, Graduate School of Medicine, Kobe, Japan

<sup>4</sup>South Australian Institute of Ophthalmology and Discipline of Ophthalmology & Visual Sciences, University of Adelaide, South Australia, Australia

Email: [cosme@d1.dion.ne.jp](mailto:cosme@d1.dion.ne.jp)

Received January 14, 2011; revised February 20, 2011; accepted April 1, 2011

## Abstract

The swinging eyelid procedure is a versatile technique to approach orbital and periorbital surgical fields with less visible scar. Although mainly used in orbital surgeries, this procedure can also be used to expose the zygomatic arch and periorbital areas. The swinging eyelid procedure, therefore, enables appropriate reduction of zygomaticomalar fracture under direct visualization. We used this technique for a 27 years old man with a displaced zygomaticomalar fracture that pushed on the lateral rectus muscle. Good functional and cosmetic results were obtained postoperatively without ocular motility impairment.

**Keywords:** Swinging Eyelid Procedure, Transconjunctival Approach, Reduction; Zygomaticomalar Fracture, Lateral Rectus Muscle

## 1. Introduction

The swinging eyelid procedure is a versatile technique to approach orbital and periorbital surgical fields with less visible scar and shorter surgical time [1]. This is an extended transconjunctival approach with lateral canthotomy and cantholysis [1]. Further incision of the Lockwood's ligament and its arcuate expansion enlarges the operating field [2]. The lower eyelid can be swung in this state, by which the "swinging eyelid" was named [1].

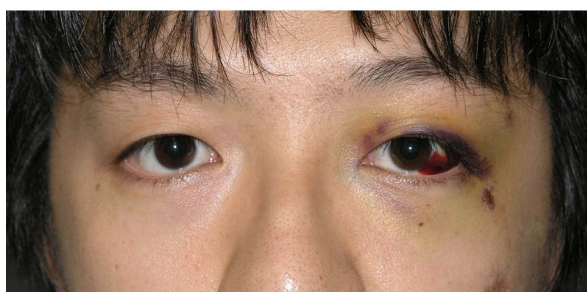Zygomaticomalar fracture is one of the commonest facial fractures [3]. In general, the zygomatic fracture reduction is performed via intraoral [4] or temporal approach [5]. Although these techniques have several merits such as minimal bleeding and no or minimal external scar, the fracture site cannot be visualized adequately. The swinging eyelid procedure enables direct visualization of the surgical site that is vital to confirm appropriate fracture reduction. However, no report has illustrated effectiveness of the swinging eyelid procedure, in spite of its popularity, for reduction of the zygomaticomalar fracture.

We present a case of a zygomaticomalar fracture, in which we used the swinging eyelid procedure in reducing the fracture.

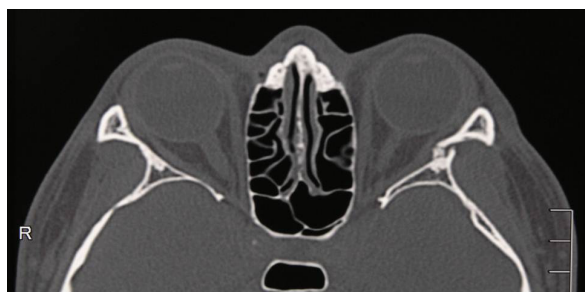## 2. Case History

A 27-year-old man fell and hit his left cheek on the ground. On initial examination, he showed a concaved left cheek and left subconjunctival haemorrhage (**Figure 1(a)**). The patient had objective numbness in the area of the left infraorbital nerve without trismus. Bilateral visual acuity, cornea and other intraocular tissues were not impaired. Ocular motility was within normal range. Computed tomography demonstrated a left displaced zygomaticomalar fracture pushing on the lateral rectus muscle (**Figures 1(b)** and **(c)**).

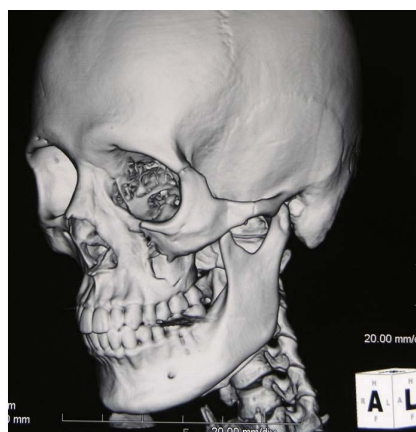
We reduced the fracture using the swinging eyelid procedure [1] 6 days after the injury. First, 2 cm length of the direct lateral skin incision was made (**Figure 2(a)**). The inferior crus of the lateral canthal band [2], the Lockwood's ligament, and its arcuate expansion were cut. The inferior conjunctival fornix was incised parallel to the lower edge of the tarsal plate and the dissection ex-



(a)

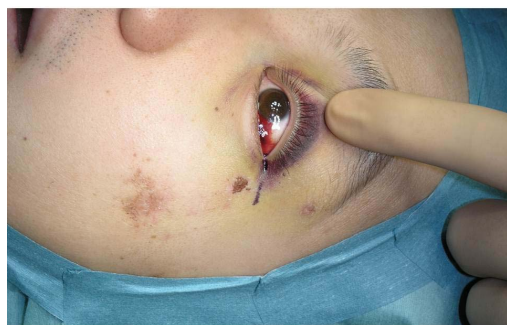


(b)

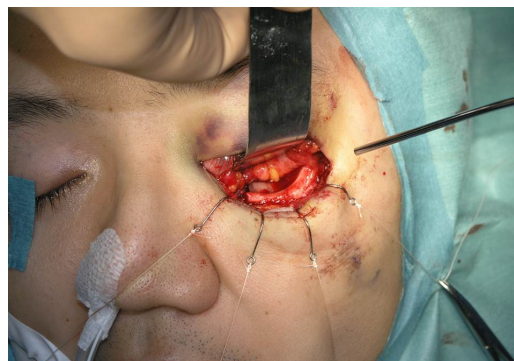


(c)

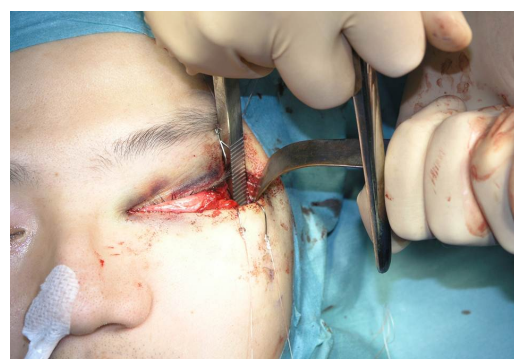
**Figure 1.** (a) Preoperative photograph of the patient showing a concaved left cheek. Subconjunctival haemorrhage is demonstrated; (b) Axial computed tomography (CT) scan showing left zygomaticomalar bone fracture; (c) Three-dimensional CT scan showing fractures of the left zygomaticomalar bone, left maxillary bone and the orbital floor.



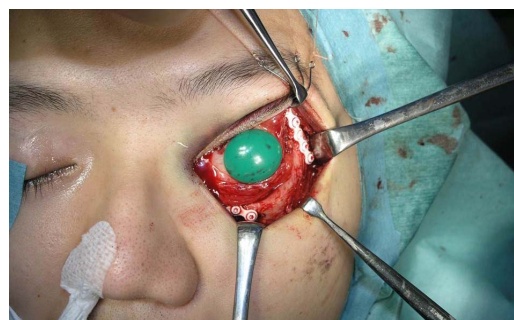
(a)



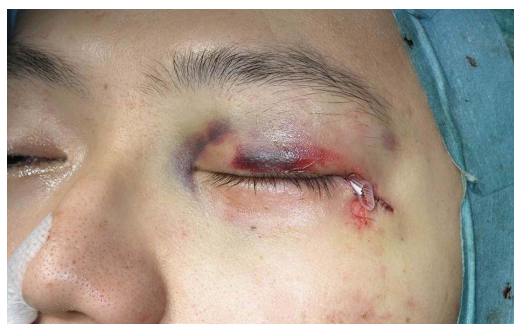(b)



(c)



(d)

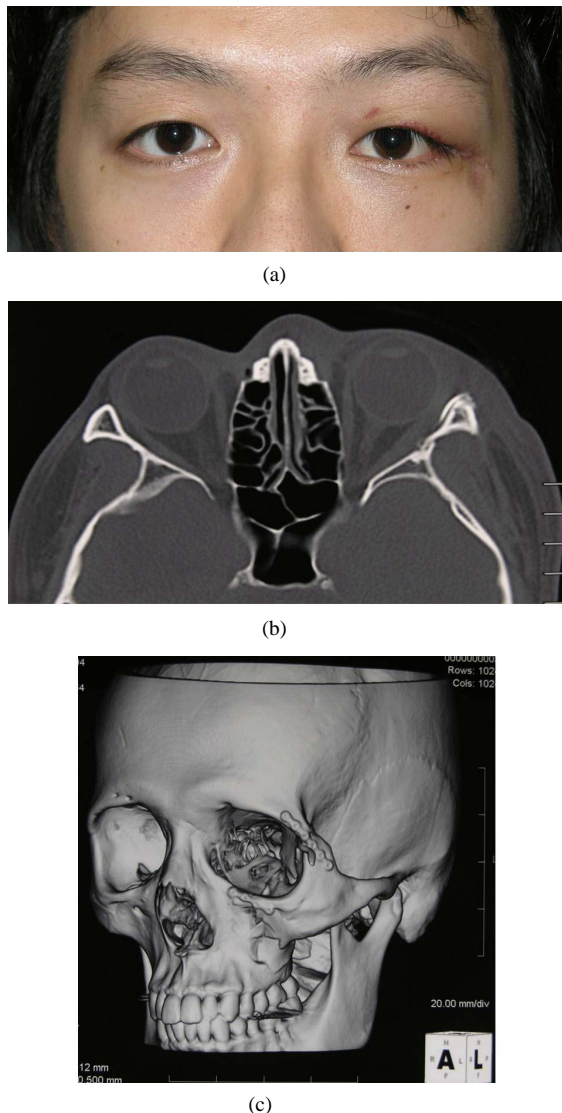


(e)

**Figure 2.** (a). Skin marking on the planned lateral canthotomy incision; (b) Exposure of the orbital floor and the orbital rim; (c) Reduction of the zygomaticomalar fracture; (d) Fixation of the zygomaticomalar fracture by absorbable microplates; (e) Closure of the skin incision with a drain.

tended to the inferior orbital rim through the retro-septal plane. The periosteum was then incised. Malleable retractor was used to expose the surgical field. The inferior and lateral orbital rims, orbital floor, lateral orbital wall, zygomatic arch and the zygomatic process of the maxilla were sufficiently exposed (**Figure 2(b)**). We pulled up the concaved zygomatic arch and reduced the zygomatic bone (**Figure 2(c)**). The bone was fixed with absorbable plates (Super FIXORB®, Takiron Co., LTD. Osaka, Japan) (**Figure 2(d)**). The lateral canthal band was the re-approximated and the skin was closed (**Figure 2(e)**).

Postoperatively, the concavity of the left cheek was well reduced (**Figure 3(a)**). The infraorbital paresthesia



**Figure 3. (a) Postoperative photograph with reduction of the concaved cheek; (b) Postoperative axial CT scan showing complete reduction with good alignment; (c) Postoperative three-dimensional CT scan showing complete reduction with good alignment.**

resolved, and the patient did not develop postoperative trismus. On ophthalmic examination, ocular motility remained within normal range. The wound was inconspicuous, and the lateral canthal shape was preserved. Postoperatively, there were no lower eyelid entropion, ectropion or retraction. Postoperative computed tomography demonstrated complete reduction with appropriate alignment of the zygomatic bone (**Figures 3(b) and (c)**).

### 3. Discussion

The swinging eyelid procedure enabled sufficient exposure of the surgical field with short access time, good safety and cosmetic outcomes. As illustrated in this case, when the fracture is displaced and pushing on the lateral rectus muscle, an open reduction is necessary to prevent a lateral rectus muscle injury and to confirm the complete reduction of the fracture.

Greater exposure of the surgical field is achieved by the lateral canthotomy and cantholysis [1]. In the simple transconjunctival approach [6], the surgical field is limited around the orbital floor because of the narrow lower conjunctival fornix space, and laceration may occur with excess enlargement of the surgical field [6].

No lower eyelid malposition or lateral canthal dystopia [7] was noted postoperatively in this case. As the dissection plane of the swinging eyelid procedure is behind the orbital septum, damage to this area may not cause postoperative lower eyelid retraction [2]. The subciliary incision takes the preseptal plane, which is sometimes associated with an unacceptable septum injury causing cicatrization and lower eyelid retraction [8]. Subciliary incision should be, therefore, avoided in reduction of the zygomaticomalar fractures [6].

In conclusion, the swinging eyelid procedure is an effective and safe technique for open reduction of zygomaticomalar fracture with good cosmetic and functional outcomes.

### 4. References

- [1] C. D. McCord Jr., "Orbital Decompression for Graves' Disease: Exposure through Lateral Canthal and Inferior Fornix Incision," *Ophthalmology*, Vol. 88, No. 6, 1981, pp. 533-541.
- [2] H. Kakizaki, R. Malhotra, S. N. Madge and D. Selva, "Lower Eyelid Anatomy: An Update," *Annals of Plastic Surgery*, Vol. 63, No. 3, 2009, pp. 344-350. [doi:10.1097/SAP.0b013e31818c4b22](https://doi.org/10.1097/SAP.0b013e31818c4b22)
- [3] P. Kelley, R. Hopper and J. Gruss, "Evaluation and Treatment of Zygomatic Fractures," *Plastic and Reconstructive Surgery*, Vol. 120, No. 7, 2007, pp. 5S-15S. [doi:10.1097/01.prs.0000260720.73370.d7](https://doi.org/10.1097/01.prs.0000260720.73370.d7)



- [4] W. W. Keen, "Surgery, Its Principles and Practice," WB Saunders, Philadelphia, 1909.
- [5] H. D. Gillies, T. P. Kilner and D. Stone, "Fractures of the Malar-Zygoma Compound, with a Description of a New X-Ray Position," *British Journal of Surgery*, Vol. 14, No. 56, 1927, pp. 651-656. [doi:10.1002/bjs.1800145612](https://doi.org/10.1002/bjs.1800145612)
- [6] G. de Riu, S. M. Meloni, R. Gobbi, D. Soma, A. Baj and A. Tullio, "Subciliary versus Swinging Eyelid Approach to the Orbital Floor," *Journal of Cranio-Maxillofacial Surgery*, Vol. 36, No. 8, 2008, pp. 439-442. [doi:10.1016/j.jcms.2008.07.005](https://doi.org/10.1016/j.jcms.2008.07.005)
- [7] N. Shorr and M. K. Fallor, "'Madame Butterfly' Procedure: Combined Cheek and Lateral Canthal Suspension Procedure for Post-Blepharoplasty, 'Round Eye', and Lower Eyelid Retraction," *Ophthalmic Plastic & Reconstructive Surgery*, Vol. 1, 1985, pp. 229-235.
- [8] S. A. Wolfe, R. Ghurani, S. Podda and J. Ward, "An Examination of Posttraumatic, Postsurgical Orbital Deformities: Conclusions Drawn for Improvement of Primary Treatment," *Plastic and Reconstructive Surgery*, Vol. 122, 2008, pp. 1870-1881. [doi:10.1097/PRS.0b013e31818cc36a](https://doi.org/10.1097/PRS.0b013e31818cc36a)